COLUMBIA LIBRARIES OFFSITE
HEALTH SCIENCES STANDARD
HX00060488

RD32 K811

Columbia University
in the City of New York

College of Physicians and Surgeons

From the Library of

Churchill Carmalt, M. D.

Presented by the Externe Club of New York

Digitized by the Internet Archive
in 2010 with funding from
Columbia University Libraries

http://www.archive.org/details/operativesurgery00koch

OPERATIVE

SURGERY

BY

TH. KOCHER, M.D.

PROFESSOR AT THE UNIVERSITY AND DIRECTOR OF THE SURGICAL CLINIC
AT THE BERNE UNIVERSITY

WITH ONE HUNDRED AND SIXTY-THREE ILLUSTRATIONS

NEW YORK
WILLIAM WOOD & COMPANY
1894

COPYRIGHTED, 1894,
BY WILLIAM WOOD & COMPANY

ELECTROTYPED AND PRINTED BY
THE PUBLISHERS' PRINTING COMPANY
132-138 WEST 14TH STREET
NEW YORK

CONTENTS.

PART I.

General Observations.

PAGE

A. Introduction, ... 1

B. Anæsthesia, ... 4

Ether spray.—Cocaine injection.—Ether.—Chloroform.—Bromide of ethyl.—Chloride of methylene.

C. The Treatment of Wounds, ... 11

Atmospheric infection.—Contact infection.—Infection by implantation.—Carbolic acid and corrosive sublimate.—Heat (steam and boiling).—Disinfection of the hands.—Asepsis and antisepsis.—The suture and open treatment of the wound.—Drainage and secondary suture.—Healing under the blood crust.—Continuous antisepsis.—Subnitrate of bismuth and iodoform.

D. The Selection of the Direction of the Incision, ... 25

Drainage openings.—Normal incisions.

PART II.

Special Operations.—Incisions.

E. The Skull, ... 33

a. Soft Parts, ... 33

1. Temporal artery and vein, ... 33
   Auriculo-temporal nerve, ... 34
2. Supra-orbital artery, ... 34
   Supra-orbital nerve, ... 35
3. Frontal nerve, ... 36
4. Ethmoidal nerve, ... 36
5. Occipital artery, ... 37
6. Major and minor occipital nerves, ... 40

b. The Relations of the Cerebral Convolutions to the Skull, . . . 40

7. Centres of the brain cortex, ... 47
   Puncture of the ventricles, ... 48
8. Relations to the surface of the skull, ... 50

c. Trephining, ... 51

9. Longitudinal sinus, ... 52
10. Transverse sinus, ... 52
11. Middle meningeal artery, ... 53
12. Frontal sinus, ... 56
13. Antrum and mastoid cells, ... 57
14. Cerebellum, ... 60

374749

PAGE

F. The Face, ... 60
Normal incisions, ... 60
15. External maxillary artery, ... 61
16. Operations on the nose, ... 62
17. Nose and nasal cavities, ... 62
18. Sphenoid cavities, ... 64
Naso-lachrymal canal, ... 64
Frontal sinus, ... 64
19. Antrum of Highmore, ... 64
20. Operations on the nerves, ... 65
21. Facial nerve, ... 65
Trigeminus II., ... 66
22. Infra-orbital nerve, ... 66
23. Orbital nerve, ... 68
24. Supra-maxillary nerve, ... 68
Trigeminus III., ... 71
25. Mental nerve, ... 72
26. Inferior alveolar nerve, ... 72
27. Lingual nerve, ... 74
28. Auriculo-temporal nerve, ... 75
29. Buccinator nerve, ... 75
30. Infra-maxillary nerve, ... 75
31. Resection of the upper maxilla, ... 77
32. Osteoplastic resection, ... 79
33. Resection of the lower maxilla, ... 80
34. Osteoplastic resection, ... 82
35. Transverse division of the cheek, ... 82
36. Incisions in the tongue and the floor of the mouth, . . 83

G. The Upper Lateral Cervical Triangle, ... 84
The Normal Incision for the Upper Cervical Triangle, ... 84
37. External carotid artery, ... 85
38. Superior thyroid artery, ... 87
39. Lingual artery, ... 88
40. Internal carotid artery, ... 90
41. Hypoglossal nerve, ... 90
42. Lingual nerve, ... 90
43. Superior laryngeal nerve, ... 91
44. Internal and common jugular vein, ... 91
45. Accessory nerve, ... 91
46. Lateral pharyngotomy, ... 92
With resection of the upper maxilla, ... 92
With excision of the lower maxilla, ... 93
Inferior pharyngotomy, ... 94
47. Median pharyngotomy, ... 94

H. The Anterior Cervical Triangle, ... 97
48. Common carotid artery, ... 97
49. Common jugular vein, ... 98
50. Vagus nerve, ... 99
51. Inferior thyroid artery, ... 99
Inferior laryngeal nerve, ... 100

PAGE

52. Vertebral artery, ... 101
53. Œsophagotomy, ... 101
54. Retro-œsophageal space, ... 102
55. Tracheotomy, ... 102
Crico-tracheotomy, ... 102
Inferior tracheotomy, ... 104
56. Laryngotomy, ... 104
57. Laryngectomy, ... 106
58. Innominate artery, ... 107
59. Excision of the diseased thyroid gland, ... 107

J. The Lower Lateral Cervical Triangle, ... 110
The Normal Incision for the Lower Lateral Cervical Triangle, . . 110
60. Subclavian artery, ... 110
61. Accessory nerve (external branch), ... 113
62. Subcutaneus colli nerve, ... 113
63. Large auricular nerve, ... 113
64. Dorsalis scapulæ, suprascapular, axillary, subscapular, anterior and posterior thoracic nerves, ... 113

K. The Nuchal Region, ... 114

L. The Thorax, ... 114
65. Internal mammary artery, ... 114
66. Intercostal artery, ... 115
67. Intercostal nerve, ... 115
68. Thoracotomy, ... 115
69. Resection of the ribs, ... 115
70. Resection of larger portions of the chest wall, . . . 117
71. Operations on the lungs, ... 117

M. The Spinal Column, ... 118
72. Opening the spinal canal, ... 118

N. Lumbar Region, ... 119
Normal incision, ... 119
73. Nephrotomy and nephrectomy, ... 122
74. Ureter, ... 122
75. Splenotomy, ... 123

O. Abdomen, ... 123
Normal incisions, ... 123
Hypochondrium, ... 124
76. Cholecystotomy and cholecystectomy, ... 124
Hypogastrium, ... 125
Common and external iliac arteries, ... 125
Opening the inguinal canal, ... 125
77. Castration. Excision of the tunica vaginalis, . . . 126
78. Inguinal herniotomy, ... 127
79. Isolation of the round ligament, ... 127
80. Resection of the vermiform appendix, ... 128
81. Formation of a fecal fistula, ... 129
82. Formation of an artificial anus, ... 130
83. Resection and suture of the intestine, ... 131
84. High supra-pubic cystotomy, ... 132
85. Opening of the bladder with resection of the symphysis, . 134

PAGE

P. Perineum, ... 134
86. Perineal lithotomy, ... 135
87. Opening of the cavernous and bulbous portion of the urethra, ... 135
88. Opening of the membranous and prostatic portion of the urethra, ... 136
Exposure of the prostate, seminal vesicles, and vasa deferentia, ... 136
89. Internal pudendal artery, ... 138
Internal pudendal nerve, ... 138
Q. Sacral Region, ... 139
90. Resection and excision of the rectum, ... 139
R. Upper Extremity, ... 143
a. Shoulder Region, ... 143
91. Subclavian artery, ... 143
92. Superior thoracic artery, ... 144
93. Thoracico-acromial artery, ... 145
94. Long thoracic artery, ... 145
b. Axilla, ... 146
95. Axillary artery, ... 146
96. Anterior circumflex artery, ... 146
97. Posterior circumflex artery and axillary nerve, . . 147
98. Subscapular artery and nerves, ... 147
99. Thoracico-dorsalis artery, ... 147
100. Circumflexa scapulæ artery, ... 147
c. Arm, ... 150
101. Brachial artery, ... 150
102. Deep brachial artery, ... 150
103. Superior collateral ulnar artery, ... 151
104. Inferior collateral ulnar artery, ... 151
105. Median nerve, ... 152
106. Ulnar nerve, ... 152
107. Radial nerve, ... 152
108. Musculo-cutaneous nerve, ... 153
d. Elbow Region, ... 153
109. Brachial artery, ... 153
110. Median nerve, ... 154
111. Ulnar nerve, ... 154
112. Radial nerve, ... 154
e. Forearm—Volar Surface, ... 155
113. Radial artery, ... 155
114. Ulnar artery, ... 156
115. Interosseal artery, ... 158
116. Median nerve, ... 158
117. Cutaneus palmaris nerve, ... 158
118. Interosseus nerve, ... 159
Radial and ulnar nerves, see Radial and ulnar arteries.
Incisions on the volar side, ... 159
f. Forearm—Dorsal Surface, ... 159
119. Deep branch of the radial nerve, ... 159
Incisions on the dorsal surface, ... 160

PAGE

g. Wrist Joint—Volar Side, ... 160
120. Ulnar artery at the pisiform bone, ... 160
121. Median nerve, ... 161
h. The Hand—Dorsal Side, ... 161
122. Radial artery on the dorsum of the hand, . . . 161
123. Radial artery on the trapezium, ... 161
124. Dorsal branch of the ulnar nerve, ... 162
125. Dorsal branch of the radial nerve, ... 162
i. The Palm of the Hand, ... 162
126. Superficial volar arch, ... 164
127. Deep volar arch, ... 165
128. Median nerve, ... 165
129. Comon digital arteries, ... 165
j. Fingers, ... 166
S. Lower Extremity, ... 167
Gluteal Region, ... 167
131. Superior gluteal artery, ... 167
Superior gluteal nerve, ... 168
132. Inferior gluteal (sciatic) artery, ... 168
133. Posterior femoral cutaneous nerve, ... 168
134. Sciatic nerve, ... 168
135. Internal pudendal artery, ... 170
Internal pudendal nerve, ... 170
Inguinal Region, ... 170
136. External iliac artery, ... 170
137. Inferior epigastric artery at its origin, ... 170
138. Circumflexa ilii artery at its origin, ... 170
139. Inferior epigastric artery at the anterior abdominal wall, ... 170
140. Circumflexa ilii artery in its outer third, . . . 172
141. Aorta and common iliac artery, ... 172
142. Internal spermatic vessels, ... 173
143. Ureter, ... 173
144. Inferior mesenteric artery, ... 173
145. Hypogastric artery, ... 173
146. Obturator artery, ... 173
147. Obturator nerve, ... 173
The Thigh, ... 176
148. Femoral artery, ... 176
149. Superficial artery of the knee joint, ... 177
Deep femoral artery, ... 180
External circumflex femoral artery, ... 180
150. Deep artery at the adductor longus, ... 180
151. Internal circumflex artery, ... 181
152. Crural nerve, ... 181
153. Internal saphenus nerve, ... 181
154. Lateral cutaneous femoral nerve, ... 181
155. Sciatic nerve, ... 184
Region of the knee joint, ... 184
156. Popliteal artery, ... 184

PAGE

157. Peroneal nerve, ... 185
158. Internal saphenus nerve (see Leg).
159. Communicating peroneal nerve (external sural), . . 185

The Leg, ... 185
160. Tibialis antica artery, ... 185
161. Deep peroneal nerve, ... 186
162. Superficial peroneal nerve, ... 188
163. Tibialis postica artery, ... 188
164. Tibio-peroneal trunk, ... 190
165. Peroneal artery, ... 192
166. Internal saphenus nerve, ... 194
167. External sural and external saphenus nerves, . . . 194
168. Tibialis posticus nerve, ... 195
169. Suralis medius nerve, ... 195

The Foot, ... 195
170. Plantar arch, ... 195
171. Internal plantar artery, ... 195
172. Internal plantar nerve, ... 196
173. External plantar artery, ... 196
174. External plantar nerve, ... 196
175. Plantar arteries at their origin, ... 196
176. Dorsalis pedis artery, ... 196

PART III.

Excisions (Resections).

T. General Observations, ... 199
U. Lower Extremity, ... 200
177. Excision of the phalanges of the toes and the metatarsal bones, ... 200
178. Metatarso-tarsal and anterior tarsal resection, . . 201
179. Intertarsal resection, ... 202
180. Excision of the talus, ... 203
181. Excision of the calcaneus, ... 205
182. Talo-calcaneus and posterior tarsal resection, . . . 205
183. Resection of the foot, ... 206
184. Total tarsal resection, ... 209
185. Resection of the lower third of the leg, ... 210
186. Resection of the tibia, ... 211
187. Resection of the fibula, ... 211
188. Arthrotomy and resection of the knee, ... 212
189. Resection of the patella, ... 218
190. Osteotomy and resection of the tibia, ... 218
191. Supracondylic osteotomy of the femur, ... 219
192. Osteotomy and subtrochanteric cuneiform resection of the femur, ... 219
193. Resection of the diaphysis of the femur, ... 220
194. Resection of the hip, ... 221
195. Resection of the pelvis, ... 225

PAGE

V. Upper Extremity, ... 225
196. Resection of the fingers and metacarpals, . . . 225
197. Resection of the hand, ... 227
198. Resection of the ulna, ... 231
199. Resection of the radius, ... 231
200. Resection of the elbow, ... 232
201. Resection of the diaphysis of the humerus, . . . 236
202. Resection of the articulation of the humerus, . . 237
203. Resection of the clavicle, ... 243
204. Resection of the scapula, ... 244

PART IV.

Amputations and Exarticulations.

W. Introduction, ... 247
X. Lower Extremity, ... 254
205. Amputation of the toes and metatarsals, ... 254
206. Exarticulation of the toes, ... 254
207. Metatarsal amputation, ... 255
208. Metatarso-tarsal exarticulation, ... 256
209. Anterior intertarsal exarticulation, ... 257
210. Posterior intertarsal exarticulation, ... 257
211. Tarsal amputation, ... 258
212*a*. Subastragaloid exarticulation, ... 259
b. Osteoplastic subastragaloid amputation, . . . 260
213. Exarticulation of the foot, ... 260
214. Osteoplastic amputation of the foot, ... 261
215. Amputation of the leg, ... 263
216. Exarticulation of the knee, ... 264
217. Amputation of the femur, ... 265
218. Intracondylic amputation of the femur, ... 265
219. Supracondylic amputation of the femur, ... 266
220. Osteoplastic supracondylic amputation of the femur, . 266
221. High amputation of the femur, ... 267
222. Exarticulation of the hip, ... 267
Y. Upper Extremity, ... 270
223. Amputation of the fingers and metacarpals, . . . 270
224. Exarticulation of the hand, ... 272
225. Amputation of the forearm, ... 273
226. Exarticulation of the elbow, ... 273
227. Amputation of the arm, ... 275
228. Exarticulation of the humerus, ... 276
229. Exarticulation of the humerus with the clavicle and scapula, ... 277

OPERATIVE SURGERY.

PART I.

GENERAL OBSERVATIONS.

A. Introduction.

THANKS to the antiseptic treatment of wounds, we can cause the most rapid healing by adhesion of wounds made by us as surgeons, and since then operative technique has received an extraordinary impulse. Provided we are sure of our antisepsis, we may incise any part of the body, not only for therapeutic but also for diagnostic purposes. Of course, this makes it incumbent upon us, now that the indications for the operative treatment of diseases have been greatly extended, to perfect our technique to the utmost, so as to remain true to the first principle of therapeusis: "*nil nocere.*" A complete mastery of the technique, resting mainly on the most accurate knowledge of anatomy, is therefore a condition *sine qua non* in operative therapeutics, standing next to the reliability of the antiseptic treatment of wounds. In practice it is not possible to study anatomical handbooks and atlases before every operation, particularly because these auxiliaries are for the most part based on purely anatomical points and fail to notice details in a manner desired by the surgeon. For this reason it is not our intention to swell the number of the many excellent text-books on operative surgery by another more explicit one; on the contrary, we mean to give the briefest possible directions, in the

manner of Roser's favorite vade-mecum, for a rapid posting on an operation to be performed.

These directions may serve as a guide for practice on the cadaver, but the main purpose has been to adapt them to the performance of operations on the living patient, and the author, therefore, has recommended only those methods which he has tried and proved by many years' clinical experience. He has done so, not because he places his methods above those of other surgeons, which often differ, but he hopes, on the contrary, at some future time to fill the gaps left here, by doing justice to the originators of operations described in these pages and of such as differ from them, and he craves indulgence that in this first publication too little notice has been taken of the historical development and importance of the various methods.

The most important task of a surgical text-book applicable to the living patient appears to us to be that the reader be enabled to post himself rapidly and surely regarding the path the knife has to follow in incisions in any part of the body and to any depth desired.

The correct direction of the first incision, so as to give free access on the one hand, and positively to avoid any unnecessary incidental injury when proceeding deeper on the other hand, is the most important point in surgical interference. It is especially necessary to learn to avoid, besides the vessels whose injury is manifested by hemorrhages, the larger and smaller nerve twigs; in other words, to choose the border lines of nerve distributions for incisions.

In this sense we hold certain incisions as typical for definite regions of the body, that is to say, as alone admissible when the choice of the method is left free, and we ourselves claim the value of our contributions to lie in our having given simple rules for reliable and conservative surgical manipulations for every part of the body.

A second group of operations is formed by excisions or resec-

tions. In these the object is not only, as in the case of incisions, to reach a deep structure by the shortest road, but a portion or an entire organ is to be removed from the body; hence the field must be so exposed that the part to be removed is easily visible and palpable, so that the morbid portion can be safely and readily extracted.

Resections of the joints and bones form a type of excisions; with them, of course, we may group also extirpations of internal organs and tumors.

Finally, in a third group we have to deal with the total removal of a terminal portion of a part of the body, either limited or extensive. These operations are called amputations. In these we have an added factor in the technique, namely, to give that part of the body from which a portion has been removed a definite form and a covering of integument; for by the complete loss of the parts on the one side of the wound the measures for obtaining a rapid adhesion of the injured tissues become more complicated.

In incisions, no matter how deep, it is sufficient—antiseptic treatment being presupposed—to bring the tissues which have been separated again into the mutual contact that existed before the operation.

In excisions and still more in amputations, however, tissues come in contact which before were not in juxtaposition.

In incisions the application of simple sutures through the entire depth and width of the raw surfaces suffices to bring them again into the closest contact as before the operation. This is best secured by a continuous suture, the needle being passed alternately deeply and superficially.

In excisions and amputations it is not possible by sutures to bring the raw surfaces so close that the tissues belonging together are brought into direct contact.

We have omitted all reference to the choice and form of the instruments, the manipulation of knife, forceps, scissors, saw,

and the various methods of suturing. We are convinced that no directions, no matter how minute, suffice to make a surgeon; all these numerous details can only be learned by witnessing and practising them in clinics and hospitals under skilful instruction. In like manner the facts as to when and why vessels are to be ligated, nerves to be stretched, joint capsules to be laid open, articulations to be resected, and limbs to be amputated—in a word, the discussion of the indications for the operations—must be learned in the clinic.

As we write these instructions mainly for use on the living patient we cannot omit mention, by way of introduction, of two vital conditions in every operative manipulation, namely, anæsthesia and antisepsis. It is not permitted to give pain to a person by an operation, any more than to jeopardize life by the inoculation of infectious material into the wound.

B. Anæsthesia.

The anæsthesia of a patient differs widely according to the operation to which he is to be subjected. We shall describe only those measures of whose efficacy and mode of application we are qualified to speak from personal observation and experience.

Ideal anæsthesia would be approached if we could render insensitive only that part of the body which is to be operated on. While there are measures which fulfil this indication, they act only superficially and for a brief period.

Local Anæsthesia.

The most important local anæsthetics are ether spray and cocaine injections. The two drugs differ in their value; one having a purely physical effect, while the other acts chemically or as a poison, not only on the sensory nerves, but also on other parts of the nervous system, by absorption, thus possibly giving

rise to dangerous incidental effects. In the use of ether, conduction along the sensory nerves is inhibited by cold. This method of anæsthesia is suitable for minor operations of brief duration. But the effect of ether continues for a short time only. If ether spray is made to act for a longer time on the skin the latter may become necrotic, especially in the case of small tumors over which the skin is tense (chondroma of the finger). Local anæsthesia by ether spray may be used when the most painful part of the operation consists in the lesion of the integument, as in simple incisions or avulsion of a nail. In such cases it is one of the best measures in our possession. The only drawback is the burning sensation when the tissue thaws. To avoid this subsequent pain the part should be dipped in warm water.

In most recent times, in place of ether spray, ethyl chloride, which acts more rapidly and certainly, has been used. This is vaporized by the heat of the hand.

Cocaine, in the form of the hydrochlorate, injected into the tissues inhibits the conduction in the sensory nerves, even the larger trunks. It also acts through the intact mucous membrane on which it is painted, without being injected into the tissues. This drug has disadvantages as compared with ether, because it is absorbed and may paralyze distant nerve elements; hence it is to be used only under certain conditions. For injection it is used in one-per-cent solution; for painting, in ten-per-cent strength. Its effect lasts only a few minutes. Experience has shown that a dose of but 1.5 grains may cause untoward accidents. A dose above 8 grains may be fatal. Hence several syringefuls of a one-per-cent solution may be injected without fear. Of course, regard must be had for antisepsis; therefore the cocaine is mixed with a five-per-cent solution of carbolic acid. The solution must be injected directly into the cutis or immediately beneath it at the point where the tissues are to be severed. In intracutaneous injections the anæsthetic zone is

recognized by the small elevation produced. Minor operations, incisions, and excisions of small tumors may be performed by means of cocaine without producing any pain.

General Anæsthesia.

Our knowledge of this beneficent means dates back only to the fourth decade of this century. The first drug by means of which general anæsthesia was obtained was ether. A very few years later it was displaced by chloroform. Up to the present time it is not decided which of these two drugs is deserving of more general application. We therefore think it desirable to inform the reader, on the strength of our own experience, as to what appears to us to be the most judicious mode of employment of these two agents; for the fact that competent surgeons advocate opposite opinions proves that both drugs may be judiciously used according to the conditions present.

The difference in the mode of employment of the two drugs is considerable in so far as ether is poisonous only in much larger doses than chloroform. In the larger doses both drugs have a toxic effect. With neither, therefore, may we exceed a certain maximum dose, as with every other poison. This maximum dose is much greater with ether; the proportion being about like that between quinine and strychnine. Just as we employ quinine in much larger doses than morphine and strychnine, so we can give much more ether than chloroform. Herein lies the great advantage of ether; for in employing anæsthesia it is necessary to give the largest possible dose of the two drugs in the shortest time. As is well known, morphine can be given in quantity greatly exceeding the maximum if the doses are distributed over a longer time. In the same way more chloroform and ether may be used in an operation lasting five hours than could be employed in a shorter time. But the danger of exceeding the limit at a single dose is much greater with chloro-

form than with ether. Why then is chloroform not discarded entirely?

Ether has certain contra-indications. By its local irritating effect on the mucous membranes of the respiratory organs it causes congestion, swelling, and increased secretion of mucus. For this reason ether is not admissible in all cases where there is hyperæmia or catarrh of the air passages, especially if associated with dyspnœa. The second reason against the exclusive use of ether is that, being effective only in large doses, it takes longer to produce anæsthesia if given, like chloroform, in slowly increasing amounts. This causes a much prolonged and more intense stage of excitement. In order to avoid this drawback ether requires a large initial dose. In this way anæsthesia is very quickly produced, as early as by chloroform if not sooner. For the same reason, when a rapid ether anæsthesia is desired, we need special large masks which cover the face completely, because the ether vapors must be quickly inhaled, in a concentrated condition.

In addition the mask is usually covered with a towel; we adapt to the face of the patient a ring of flexible copper wire so as to exclude the air as much as necessary. In this way it is possible to produce ether anæsthesia in two or three minutes and the stage of excitement is greatly shortened. This rapid method, however, has the drawback that the necessary exclusion of the air causes a certain degree of asphyxia. This explains the alarming sensations, cyanosis of the face, and the heavy breathing of many patients under its influence.

With chloroform such measures for the rapid and concentrated introduction of the drug are unnecessary. On the contrary, care is taken to admit sufficient air. For years we have arranged it so that a free space is left all around between the cover of the mask and the ring which is moulded to the face (Fig. 1). In this way sufficient anæsthesia is produced within ten minutes at the most, without any obstructed respiration or

sensation of suffocation. This is one advantage of chloroform. Moreover, chloroform has no such irritating effect on the mucous membranes as ether; hence chloroform anæsthesia is more quiet and agreeable than that of ether. As a matter of course, in employing a drug intended to inhibit sensation and in many cases also to produce a paralysis of the motor apparatus to the degree of muscular relaxation, care must be taken that the function of the respiratory and circulatory organs is not likewise suspended. The first task after beginning muscular relaxation is to make sure of respiration, particularly the ingress of air into

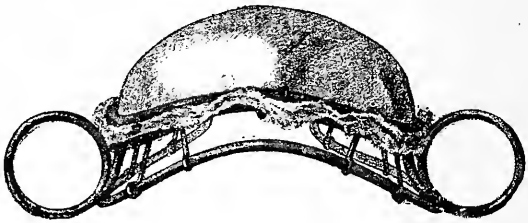

Fig. 1.

the opening of the larynx. This is effected by lifting the maxilla, and with it the root of the tongue, forward. As soon as the stage of paralysis begins the tongue and the maxilla, in the usual dorsal position, drop backward and the epiglottis overlaps the laryngeal opening like a valve, as we may convince ourselves by inspection during resections of the jaw and the tongue. It requires strong forward traction of the base of the tongue or the epiglottis to render the upper portion of the latter so tense that it remains fixed above and forward during inspiration. Pressure behind both maxillary angles is best adapted to raise the base of the tongue along with the jaw, provided the neck be stretched at the same time by bending the head backward, thus making the tongue tense not only forward but also upward. This stretches the glosso-epiglottic ligaments and the epiglottis is held fast. This manipulation positively prevents accidental suffocation during anæsthesia. Previous to it the patient must

be prepared so that respiration be not hindered by other causes, as by full stomach and intestines, constricting clothing, or improper position. At the beginning of the anæsthesia the stomach must be empty or have been artificially emptied, lest remnants of food get into the larynx from vomiting during sleep.

If free respiration before and during anæsthesia is provided for in this manner; if a mask is employed which makes it impossible that concentrated chloroform be inhaled; and if the amount of chloroform in the continually admitted fresh air is increased by an uninterrupted addition of the drug, drop by drop, in quantity just sufficient to produce anæsthesia, then there is no danger,[1] but this becomes imminent when more profound effects on the nervous system are aimed at, namely, complete muscular relaxation, and when the chloroform is given for a longer period. In this way the maximum dose is necessarily more and more approached, and we should be able to recognize the signs of this approach. They are as follows: the dropping of the jaw and tongue with the consequent obstructed respiration indicate the beginning of the more profound effect; then it is shown by the general muscular relaxation and the slowing of the pulse. The maximum is almost reached when respiration becomes labored, while the pulse becomes irregular and weaker. This shows sinking of the blood pressure, which may be followed at any moment by insufficient heart action, with the resulting cerebral anæmia and collapse. It is necessary to guard against this possibility beforehand by placing the patient in a position which favors the cerebral circulation. A patient should be chloroformed only with the trunk in a horizontal position and the lower extremities raised. In our operating table provision has been made to have the legs higher than the trunk. Of

[1] We have never been able to make up our minds to employ the much-vaunted apparatus of Junker and Kappeler, not only because the anæsthesia is rendered more complicated, but because we find that with careful supervision the dose can be much better adapted to individual conditions by adding the chloroform drop by drop than by means of apparatus.

course the administration of the anæsthetic is to be stopped as soon as the above-mentioned dangerous symptoms appear.

In every prolonged operation we advise, after complete anæsthesia has been obtained by chloroform, to continue with ether unless contra-indicated by disease of the air passages. The maximum dose of ether is so much greater than that of chloroform that the danger of reaching that point suddenly is incomparably less than with chloroform. It is not difficult to maintain for hours with ether an anæsthesia once completely effected by chloroform, and this combined method has the great advantage that the ether need not be given in suffocating doses, since small doses and ordinary masks suffice. But for economical reasons it is always well to guard against the too rapid evaporation of the ether by covering the mask with impermeable tissue.

In disease of the heart muscle chloroform must never be given, but only ether.

For an anæsthesia of brief duration bromide of ethyl is an excellent drug: five drachms poured at once on an impermeable mask, and pressed on mouth and nose while air is excluded, will in from thirty to sixty seconds cause an anæsthesia which lasts from one to several minutes. But nothing more should be attempted with this drug, neither prolonged anæsthesia nor muscular relaxation; bromide of ethyl should not be poured on a second time because, owing to its quick effect, sinking of the blood pressure with consequent collapse may ensue with surprising rapidity. Recent experience seems to show that bromide of ethyl anæsthesia may be effected with very small doses of from 80 to 100 minims if it is poured on drop by drop, and that the narcosis can then also be maintained for a longer time, fifteen to twenty minutes, without any danger.

Chloride of methylene is preferred to both chloroform and ether, as being much less dangerous, by such an authority as Spencer Wells. But as this drug is given by Spencer Wells, or by Junker von Langegg, the inventor of the Junker apparatus,

only by means of the latter, it is possible that the excellent results obtained are due as much to their great experience in its administration as to its chemical composition. Our experience with it has been unsatisfactory, probably owing to its inconstant chemical composition.

It is proper, and we have done so for nearly twenty years, to administer one-half hour prior to every anæsthesia a cup of tea with brandy or a glass of Marsala wine in order to strengthen the action of the heart and raise the blood pressure. We are able to prove by pulse tracings the influence exerted under anæsthesia by these stimulants in this direction.

C. The Treatment of Wounds.

The second indication we have to meet during every operation is asepsis. We must guard the patients both during and after the operation against the injury and danger of a wound infection.

It is not to be expected that an exhaustive treatment of this subject will be given within a couple of pages. In this place we mean only to explain the principles underlying this treatment of wounds, and how a rapid and undisturbed healing of every operative wound can be simply secured by excluding infection. When a wound is to be healed quickly it must be guarded against infection, that is to say, against the deposition and development of the agents of decomposition. The truth of the fact may be considered as demonstrated that every wound, with proper care for favorable mechanical conditions, may be caused at once to adhere, provided micro-organisms and their products are kept from the tissues. Micro-organisms, however, adhere to all solid and liquid objects which come in contact with the wound and must be destroyed upon and within them.

Near the end of the sixth decade of this century, Lister demonstrated the decisive importance of atmospheric dust and all

objects touched by it, and he introduced the principle of the antiseptic treatment of wounds, based on Pasteur's proof of the origin and nature of the causes of decomposition in general. Lister first proved that decomposition in wounds occurs only when particles of dust are brought in contact with them. Should these noxious particles be kept off, no decomposition occurs. The splendid results immediately obtained in surgery by having regard to this simple fact, both in the hands of Lister and particularly in those of German surgeons (Volkmann, Schede, Thiersch, and Socin), form the basis of the extraordinary importance of Lister's investigations and observations. The second step taken by Lister was his demonstration that these dust particles are of an organic nature, since they could be destroyed by such measures as destroy organic substances in general. Finally Lister proved that these substances are capable of development, that is to say, that they are organized.

Pasteur had furthermore found some definite germs for certain decompositions outside of the human body. Billroth had published in a remarkable work the results of his investigation on the specific material of wound infection. But it was only toward the end of the seventh decade that Koch proved by means of greatly improved auxiliaries that in wounds as in fluids contained in glass flasks certain kinds of decomposition occur only through the influence of certain micro-organisms. Now the victory was gained upon the field on which the doctrine of the diseases of wound infection could be accurately established and on which even to the present day ever new advances are made in the treatment of surgical and medical diseases.

For the treatment of wounds, however, one preliminary standpoint has already become common property, namely, that we should strive to exclude all micro-organisms from wounds and that we possess the means to accomplish this object in practice in a satisfactory manner.

Lister believed he could meet this indication in the main by

preventing atmospheric infection, and the spray introduced by him remained for a long time the fundamental point of the antiseptic treatment of wounds. The operator and the patient were enveloped in a dense fog of carbolic acid which was to penetrate the dust particles and render them innocuous.

The doctrine of atmospheric infection was based on experiments in which decomposition of an unstable fluid (urine) was positively prevented for years when the drawn-out neck of the vessel was bent downward; while decomposition ensued immediately when the neck of the bottle was broken. It has been recently shown that the spray is not only unnecessary but is even injurious because it agitates the dust particles and actually drags the germs of infection along upon the wound without harming them or arresting their development by the temporary contact with the carbolic spray. It appeared that in order to prevent atmospheric infection it was sufficient to remove the dust particles by ventilation, mechanically by washing the walls and furniture, and finally by allowing the remaining dust to settle, if the operation is performed in appropriate localities which can be shut off and have smooth, clean walls. Even Lister has proved by Tyndall's beautiful experiment that the air becomes perfectly freed from dust by allowing the heavy particles to settle: if a beam of sunlight is allowed to fall through an empty closed bottle it can be seen as a bright streak; but when the bottle is left at rest the streak disappears because the dust particles which reflected the light have fallen to the bottom.

But the doctrine of the relative innoxiousness of atmospheric infection must not be carried *ad absurdum* by avowing that one would as readily operate in any by-place as in an operating-hall, provided instruments and dressings are properly disinfected. On the contrary, it must always be considered a matter of great safety when an operation can be performed in a room with clean, smooth walls, so that dust can neither fall nor be stirred up from

furniture, floor, or particularly from the ceiling or possibly a hanging lamp.

Of vastly greater importance indeed than an atmospheric infection is that form which at present is preferably designated as contact infection. It is this upon which nowadays the greatest stress is laid in the treatment of wounds, even by Lister himself, and as a matter of fact we possess a true antisepsis only since this view has been accepted. This is the infection caused by touching wounds with larger or smaller objects of any kind —instruments, sponges, pledgets, the hands of the surgeon, and irrigating fluids.

It is at once clear how infectious materials introduced in this manner must adhere to the surface of the wound in quite a different way from those coming from the air. When the tissues in the wound are grasped with hands or instruments the infectious matters are at the same time pressed into it, somewhat as in vaccination. The term "infection by vaccination" would be more descriptive, inasmuch as air infection is really that of mere contact.

But it is still more important to separate another mode of infection, namely, that for which we have proposed the name "infection by implantation."

In this class belong in the first place infection by ligatures, and in the second place by other bibulous or porous foreign bodies. If infectious germs are introduced into a wound with a suture we infect not only by the momentary contact or vaccination, but we transplant into the wound a permanent focus of incubation in which the germs at once find an appropriate place of development. Within such a foreign body (necrotic portions of tissue which have been infected act in a similar manner) are contained the most favorable conditions for a lasting and spreading infection, which is by no means the case to a like degree in infection by vaccination. Hence infection by implantation is the worst of all, and disinfection must pay the greatest attention to this mode.

Do we at this time possess the means of positively disinfecting or sterilizing all those objects which come in contact with the wound or remain in it? This question is to be answered unhesitatingly in the affirmative as regards pledgets, dressings, sutures, and instruments, and a physician is no longer permitted to sin against the demands of absolute sterilization of the objects named or to excuse defects in the antiseptic treatment of wounds by untoward external conditions.

What constitutes correct antisepsis? There is a whole series of drugs possessing disinfecting power. Foremost stand carbolic acid and the still more reliable corrosive sublimate. These two drugs, however, do not act instantaneously, but after some little time, so that the dressings must be exposed to their effect for some longer period. If the dressings are to be really sterile, that is to say, if all germs and spores are to be killed in them, we must adapt the duration of the influence of these antiseptics to the resistance of the most refractory spores. There are micro-organisms which can resist even sublimate for two, three, or four hours, perhaps a whole day.[1] We must leave our dressings in the respective solutions for several days, but this would injure many materials. Instruments cannot at all be placed in sublimate, nor for days and weeks in the slowly acting carbolic acid. Chemical disinfection, therefore, finds application only with some materials, especially silk ligatures. These can be kept for a long time in sublimate without injury. One drawback of the chemical method is that the dressings, when brought in contact with the body of the patient, manifest the poisonous effects of the drugs, both by their local influence and by absorption. The chemical mode of sterilization, therefore, is but a makeshift and applicable only to certain materials and under certain conditions.[2]

---

[1] Compare among others the investigations by Vicquerat and Zimmermann (under Tavel's direction), Berne Dissertation, 1889.

[2] With Tavel, we must make a distinction between disinfection and sterilization; for the treatment of wounds we may be satisfied with disinfection, and restrict sterilization to the pathogenic germs.

The dry preservation of dressings sterilized with solutions of carbolic acid and sublimate is to be entirely rejected. Sterilization with these drugs lasts as long as the disinfectant remains present in active form. Positive demonstrations show that this is no longer the case with dry dressings. *Corpora non agunt nisi liquida.* We cannot be sure that during the preservation or at the moment of their use infectious germs did not adhere to such dressings. Chemical sterilization, therefore, is reliable only when the materials are applied to the wound directly from the disinfecting fluids. Before applying, the materials taken from the solutions are expressed in a wringer and immediately placed upon the wound. All dry dressings, supplied ready prepared by the factories, should not be recognized as sterilized.

Ligatures have long been treated according to this view. These, when subjected to chemical sterilization, are wound upon spools which are preserved in the antiseptic fluid, from which they are transferred directly to the wound. This is admissible because we are dealing with a fine, thin substance and the small amount of adhering carbolic acid or sublimate is of no importance with reference to local or general poisonous effect;[1] in the case of large dressings the drawback mentioned as to their direct application from the disinfecting fluid remains in force.

Our best sterilizing agent is heat. With a degree of heat of from 300 to 350° F. we secure satisfactory sterilization or disinfection of all our dressings—gauze, binders, ligatures, and instruments. Still more effective than this dry heat is moist heat. Its safest mode of employment, according to the most recent investigations, is in the form of a current of steam under high pressure. This at 266° F. and above destroys all micro-organisms and their spores present in permeable objects, in the course

[1] Taking the ligatures from the sublimate solutions during the operation has the advantage, on the contrary, that it guards at the same time against accidental infection at the moment of employment.

of a few minutes. At our clinic we use a steam boiler at 293° F. under pressure of three atmospheres.

But even this perfectly reliable method of sterilization is useless unless the objects can be directly transferred from the boiler to the wound. This is not possible in all cases, for extraneous reasons, and instruments in particular suffer more from steam than from dry heat.

The best and simplest substitute for steam which we have used extensively for years is boiling of the instruments and dressings. The boiling must be continued for some time; but we may be sure of working with disinfected instruments when they have remained for half an hour in boiling water, or better, according to Schimmelbusch's method, in one-per-cent soda solution, in which the instruments do not rust. Boiling has the great advantage that the necessary apparatus is everywhere accessible and particularly can be so placed that instruments and dressings can be taken from the sterilizing apparatus directly by the hands of the operator. Quite recently Dr. Tavel has experimented with solutions of table salt, and table salt with soda (we have used the former for a long time in place of plain water for wounds), and has found that they required less boiling for complete sterilization. Dr. Tavel's favorable report shows that a solution of 0.75% of table salt and 0.25% of calcined soda is absolutely sterile after fifteen minutes' boiling (the spores of the anthrax and hay bacillus and of the bacillus mes. vulg. are killed) and keeps very long (a few mould fungi grow only after several weeks). Gauze compresses, pledgets, and silk are absolutely sterile after half an hour's boiling in the solution. Tavel subjected the salt-and-soda solution to a special examination in order to use a solution containing the same amount of salt and alkali as the blood. As regards the salt solution our experience has long shown that it does not irritate the wounds at all. According to Tavel the salt-and-soda solution is also well borne in large doses by intravenous injection, nor does it

injure the peritoneum in any manner. A boiled solution of salt and soda (Tavel's 0.75% of salt and 0.25% of soda) also furnishes a perfectly sterile and unirritating fluid for rinsing and cleansing wounds. This does away with the objection against the flooding system raised by the advocates of the dry treatment of wounds. Warm compresses boiled in the salt-and-soda solution furnish the best dressing for immediate contact with the wound. We always use gauze, deprived of fat for dressings, pledgets of gauze in place of sponges for soaking up liquids, drainage tubes of glass, and silk ligatures.

Though we have arrived at absolute security in the disinfection by relatively simple measures (steaming and boiling) of all inanimate objects, this is not true in like manner of our hands and the skin and tissues of the patient. Yet the cleansing of hands and skin is an indispensable condition of the antiseptic treatment of wounds. We cannot hold our hands in the steam nor can we boil or scald them. Hence we must resort to chemical measures which really should by rights, as we have shown, act for hours. As this is impossible, we must content ourselves with a preliminary thorough mechanical cleansing as we do in the prevention of atmospheric infection. Some days before the operation the skin of the patient is shaved over a large circumference, scrubbed with soap and hot water, protected against gross impurities by dressings, and immediately before the operation scrubbed with a 0.1% sublimate solution and rinsed with an abundance of water. The operator's hands, fingers, and the nails particularly are washed with soap and brush for several minutes under a jet of warm water. Of course, by this means we do not effect sterilization, as ordinary water contains germs, but we make sterilization by simple measures possible, for a similar cleansing with a brush for one or two minutes is next effected with a 0.1 or better 0.2% acid sublimate solution. Bacteriological examination by Drs. Tavel and Vicquerat has proved that the hands, as a rule, are rendered sterile by this

means. If after such cleansing the hands are dipped in gelatin or we inoculate the detritus from under the nails, no bacteria develop. Of course, the antecedent occupation is not without influence. I have tested this on my own person in a case of osteomyelitis in which I opened a large abscess and purposely soiled myself. Despite the above-mentioned method of disinfection, some colonies of staphylococci developed. After soiling with fatty material, washing with alcohol as recommended by Fürbringer is excellent.

Under Tavel's direction Dr. Zimmermann made a number of experiments by instantaneously infecting small pieces of meat with definite micro-organisms and found that the sterilization of such particles of meat by placing them from one to five minutes in 0.1% acid sublimate solution is not always successful, while it is easily effected in the case of infected strips of blotting-paper. Therefore we must have great care not to soil our hands, and those of all persons taking part in the operation, with infectious materials. By no means should we make a post-mortem examination and still less dress infected wounds before an operation, although competent surgeons have declared it to be admissible.

With hands previously cleansed, both bacteriological examination and the healing of the wounds prove that disinfection can be secured by a thorough scrubbing of the nails, fingers, and hands with a brush, soap, and warm water, followed by a final scrubbing with a disinfected brush and a sterilized warm soda or salt solution, several times repeated in fresh liquid. Dr. Zimmermann often showed that our hands and the epidermis scales from around and under the nails were absolutely free from germs. Of course such washing takes time, and every visible stain must be thoroughly removed by prolonged brushing under a warm-water jet. The brushing and washing in 0.1 or 0.2% sublimate solution increases the certainty of sterilization and is doubly necessary in all cases where warm and sterilized

water is not plentiful, as well as when the hands have been previously soiled directly with pus or excrement. For even if this does not kill all the micro-organisms they are greatly weakened.

At all events it can be demonstrated that the disinfection of the hands and of the skin of the patient is not as reliable as the sterilization and the preparation of the instruments and dressings. If we remember in addition that accidental infections by inattention during an operation are never positively excluded, we shall do well to look upon every operation wound, no matter how carefully made, as possibly slightly and superficially infected at the end of the operation. The more unfavorable the conditions the more certainly do pathogenic germs get upon the wound. Hence the question arises: Can the wound itself, can infected tissues be sterilized? And if this is not the case: How can we repair the damage of slight superficial and of grave infection? As regards the sterilization of the wound a few words suffice. If according to the above-mentioned demonstration by Dr. Zimmermann it is impossible to destroy positively all the germs in a piece of meat infected by a momentary contact with micro-organisms, even when it had been left for five minutes in 0.1% sublimate solution, there is no hope that it can be done with a wound. Still Zimmermann obtained by his disinfection quite an important difference in degree, since far less colonies developed and these did so more slowly and at a later time, their virulence having been weakened. Therefore it need not surprise us to learn that Lister[1] takes this stand as to the antisepsis of the wound and washes it with 0.2% sublimate solution at the end of the operation. We have shown[2] that the most excellent results are obtained by proceeding aseptically and using a 0.1% solution of sublimate for a single washing of the wound.

We guard against excessive chemical injury of the tissues

[1] Paper read before the International Med. Congress at Berlin, August, 1890.
[2] Correspondenzblatt f. Schweizer Aerzte, Jan. 1st, 1888.

and overabundant absorption of the sublimate by a final thorough washing of the wound with 0.75% sterilized salt solution.

As to the opening of the large cavities of the body, proof has been furnished that excellent results can be obtained without any antiseptic irrigation; but the condition of the serous membranes and cavities is no guide for other injured tissues such as connective tissue and muscles. With reference to laparatomies we have likewise restricted ourselves for many years to the antiseptic preparations previous to the operation, *i.e.*, to what is now generally called the aseptic treatment of wounds. The wound cavity is merely rinsed with sterilized salt solution. But numerous experiments—for instance, with the peritoneum—prove that the serous membranes are very tolerant of infectious materials or digest them with relative facility and render them harmless, perhaps by the assistance of serous transudation, so long as the endothelium remains intact (experiments by Tavel and Walthard); but that the injured tissues in a wound are not in an equally favorable state. However, observations by Lanz show that micro-organisms develop much more frequently in the clot of drainage tubes when the wound runs a favorable course than in the bloody secretions from the depth of the wound. Hence we may hope that here too a small quantity of micro-organisms, especially when weakened, are exposed in the wound to similar influences which delay or arrest their development. Upon this disinfectant effect, especially of the transuding blood serum and the living tissues, we may rely for supplementing our aseptic wound treatment, which thus far does not offer absolute security and in a concrete case probably never will.

Our last but by no means worst auxiliary for obtaining the aseptic healing of wounds is to render impossible a noxious development of the few infectious materials which may have reached the wound in spite of every precaution. In this respect we must bear in mind the following conditions:

Human tissues through which the circulating blood and

lymph pass form a poor nutrient for bacteria. But their development is favored by stagnant blood and stagnant serum in the wounds. Thence arises the indication to prevent the accumulation of stagnant fluids between the raw surfaces. This is effected in two ways: (1) the exact coaptation of well-nourished wound margins. We avoid chemically injurious applications (disinfection) and unnecessary mechanical influences (traction, bruising, and pressure); we secure good circulation by the proper selection of the incision and the position of the parts; and bring the raw surfaces into close contact by suture and careful compression. (2) Where perfectly exact coaptation is impossible, the wound secretions are conducted outward. The safest and the most excellent means for this is an open treatment of the wound. But the healing in that case would be slow.

For this reason we have re-introduced the method of the secondary suture, and Bergmann has employed it extensively. Spengler, Nussbaum, Helferich, and others have variously modified it. It consists in leaving the wound open for twenty-four or forty-eight hours, rarely longer, and then closing it by sutures. This method unites the advantages of the open-wound treatment with that of the suture.

An easier but less reliable way is drainage of the wound. In conjunction with complete suture of the wound, it should always be effected through special small openings, by means of glass tubes with large perforations, which had been immersed in 0.1% sublimate solution. In twenty-four hours, more rarely after forty-eight hours, and exceptionally only after several days, the drainage tube will have carried off the fluids effused in consequence of the injury and should then be removed. Drainage tubes are allowed to remain longer only when it appears that a wound has been gravely infected. Of course, in such a case an open-wound treatment, with or without an eventual secondary suture, is to be preferred after the use of repeated disinfection.

The middle course, as it were, between the open treatment and drainage is held by Schede's treatment under the moist blood crust. When the immediate coaptation of the wound margins is impossible it utilizes the blood effused into the wound to fill the cavity. The wound is allowed to fill with blood, the edges are but partially united by sutures, and the rest is covered with impermeable tissue. Where neither primary nor secondary suture is possible this method is much preferable to the simple open-wound treatment, with reference to the duration of the healing, by favoring the cicatrizing process.

When every facility is at hand for effecting perfect asepsis according to the above principles, *i.e.*, for preventing beforehand any intense and lasting infection of the wound, the measures here indicated will suffice. But when one must operate under unfavorable external conditions, *i.e.*, when the ingress of larger quantities of micro-organisms cannot be prevented, or when a wound is exposed to subsequent infection, as in operations on the mouth, pharynx, larynx, and rectum, or when operations must be performed within the limits of foci of infection, as in fistulæ and ulcers, a single sterilization of the recent wound does not suffice, but we require a lasting effect of antiseptic measures, namely, continuous antisepsis.

This can be done in two ways: (1) By the repeated application of the above-enumerated antiseptic agents. This procedure presupposes an open wound. If the wound is left open through its entire extent, asepsis may be secured in a short time by the repeated direct application to the raw surfaces of carbolic acid or sublimate compresses, at first every few hours, then at longer intervals. But a corresponding absorption and poisonous action of the drug is necessarily associated with it, and this serious incidental effect must be closely watched. Yet as we do not aim at a single powerful disinfection, but mainly at arresting the development of micro-organisms, the desired object may be also attained by frequently changed warm antiseptic dress-

ings impregnated with a mild solution of carbolic acid (0.5 to 1%) and sublimate (0.01%) or with weaker antiseptics such as thymol (0.1%) and salicylic acid (0.15%). At first we use, as a rule, gauze slips dipped in freshly prepared 5% carbolic acid solution, which are changed every three hours; later, moist warm compresses impregnated with 0.15% salicylic acid solution. Far less reliable than compresses with antiseptics is irrigation through drainage tubes left in the wound.

(2) The other way of securing a prolonged effect consists in impregnating the raw surfaces with substances which render the tissues resistant against the influence of micro-organisms: with permanent antiseptics in the more restricted sense. This class includes caustics and iodoform. In the salts of mercury, silver, zinc, and bismuth we possess substances which combine with the albumin in the tissues and form albuminates which resist the decomposing effect of the bacteria—in fact, these metallic substances act as direct antiseptics upon the micro-organisms. For such purposes we employ a one-per-cent emulsion of subnitrate of bismuth or a similar preparation of zinc. The results of our bismuth treatment are among the best obtained previous to the time of perfected antisepsis. But the drugs mentioned, bismuth in particular, are likewise decomposed by the processes occurring in the wound, a sulphate of bismuth being formed. These applications, therefore, exert their full effect only when employed before the decomposition of the tissues by the micro-organisms begins, *i.e.*, upon fresh wounds. When necrosis of the tissues has set in through decomposition, more powerful antiseptics are required, such as tincture of iodine, pure powdered salicylic acid, or the thermo-cautery.

Iodoform belongs to a different class from the caustics. By the introduction of this drug Mosetig-Moorhof has opened the way for a new form of wound treatment. Iodoform manifests its effect only after the onset of decomposition processes. The latter cause the iodoform to split up and thus the ptomaines and

toxalbumins are fixed and incidentally the further development of the micro-organisms is arrested (De Ruyter). Therefore iodoform has no place in the aseptic treatment of wounds. In wounds appropriate for the aseptic treatment its employment is senseless; on the contrary, the wound may be directly infected by its application. But it is the most active of all drugs for counteracting beginning and advanced decomposition, and hence is to be used on wounds where decomposition must be expected from insufficient asepsis. De Ruyter's investigations show that Bergmann's favorite mode of pouring into the wound a solution in ether and alcohol (iodoform, 10; ether, 20; alcohol, 80 parts) is to be preferred. Iodoform possesses the drawback that it produces marked poisonous effects in certain persons, especially on the central nervous system, so that it should be used with great care and in accurate doses.

Special mention should be made of the fact that wounds made when intense infection already exists, as in fistulæ, etc., are to be united by sutures only in exceptional cases. As a rule, the open treatment, with or without secondary suture, will be necessary.

D. The Selection of the Direction of the Incision.

Before the period of anæsthesia and of asepsis in wounds it was a wise plan to make incisions where they could be done rapidly, where a small size sufficed, and where gravity insured free egress to the secretions.

The latter indication can nowadays be perfectly met by separate, very small incisions for the introduction of drainage tubes. On the other hand we still see some teachers, when instructing students in tying arteries, giving directions how to find an artery through the smallest possible incisions. Such practice is no longer justified. The true surgeon is recognized by his splitting the skin to an ample extent, yet proceeding

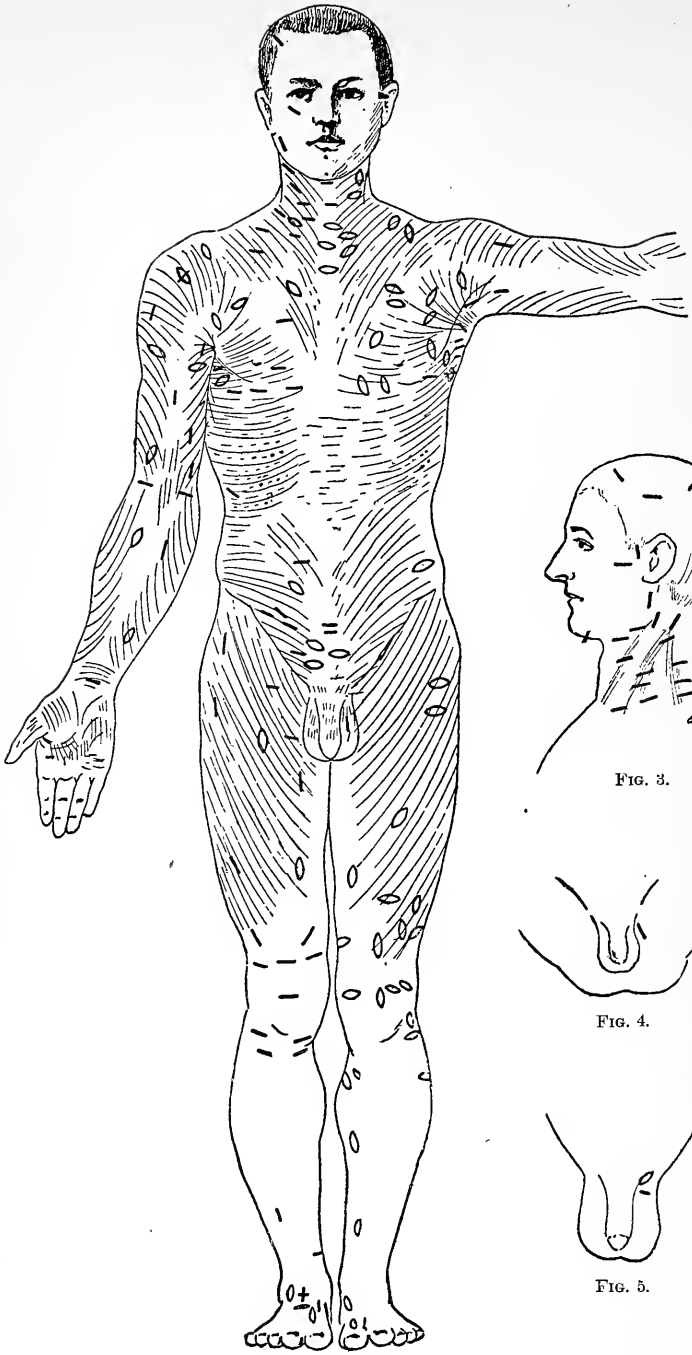

Fig. 2.

Fig. 3.

Fig. 4.

Fig. 5.

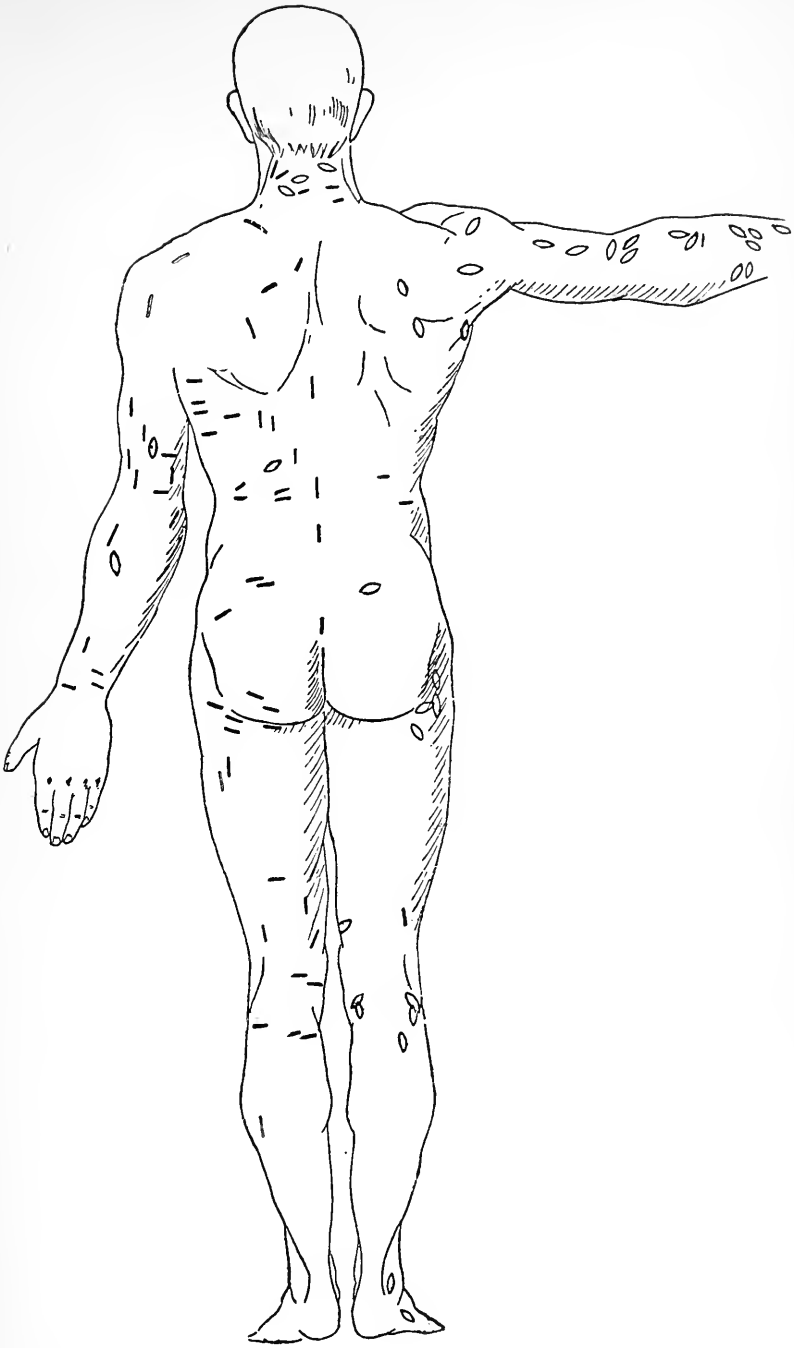

Fig. 6.

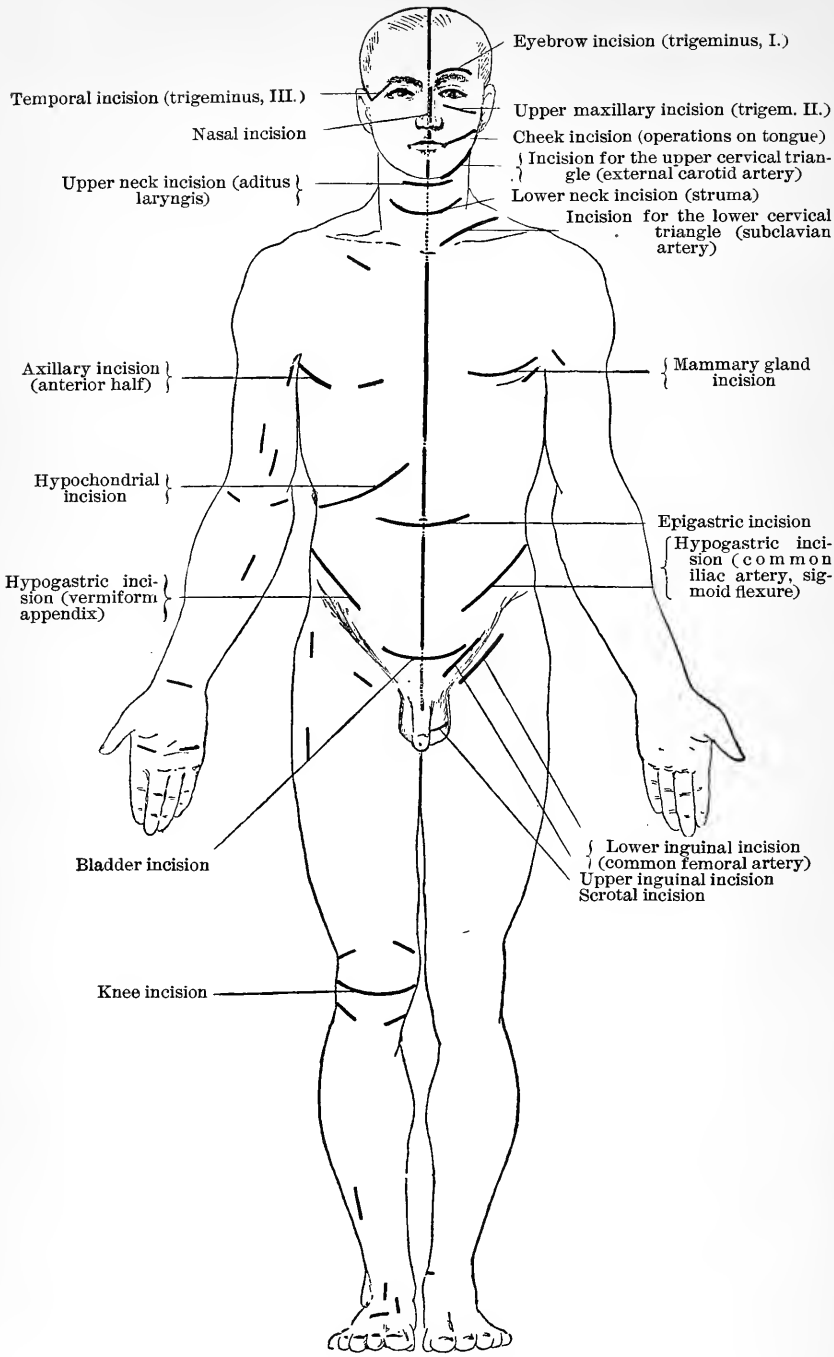

FIG. 7.—Normal Incisions.

with the greatest care and conservatism in the depth of the wound. A large cutaneous incision forms no appreciable additional injury as compared with a smaller one, for an exact suture unites it as quickly, safely, and beautifully as the latter. Moreover, the extent of the cicatrix remaining is of no importance, provided it occupies a suitable direction. This brings us to the point which we have adhered to for years as decisive in placing the incision.

Langer's investigations into the directions in which the skin splits show that the tension of the skin varies greatly in two different directions. Two incisions vertical to each other exhibit a varying retraction of the wound margins: while one gapes widely, the edges of the other remain in contact even without artificial means. This fact has to be borne in mind in choosing the direction of the incision, unless other factors have a determining effect in a concrete case; for the course of the vessels and especially of the larger and smaller nerve twigs is even more important for the direction of the incision. Thus in incisions in the face the first care will be as regards the course of the branches of the facial. Fortunately the course of the nerves and vessels largely coincides with the direction in which the skin shows the greater tension, so that a cutaneous incision adapted to the cleavage line corresponds also with the course of the important nerves and vessels.

For years we have noted our incisions which were not united by suture in a schematic diagram, according as to whether they appeared open or closed when the dressings were changed. For this purpose we made use of the drainage openings made close to the sutured cutaneous wounds. If the drainage tubes are removed after twenty-four and the sutures of the main wound in forty-eight hours, we are enabled to become posted as to the condition of cutaneous wounds not closed by sutures. We give below the results of this practice in juxtaposition with Langer's lines showing the cleavage lines of the human skin.

In Figs. 2, 3, 4, 5, and 6 the drainage openings which closed spontaneously after removal of the tubes are represented by a single line; those in which the openings remained patulous, by a spindle-shaped mark. Fig. 2 shows how largely well-directed incisions correspond with Langer's cleavage lines, as might have been expected *a priori.*

This having been ascertained, we gradually came to prefer the direction of the cleavage lines also for the longer incisions, and have convinced ourselves that the difference in cicatrization after incisions with or against the cleavage lines is so important that it behooves us to indicate normal incisions for every region of the body. These show for that particular region the cleavage lines of the skin and at the same time are so placed as to avoid the course of important superficial nerves and vessels. We have convinced ourselves in the case of our frequent operations for struma that the cicatrices after such a normal incision become so faint in the course of time that they are hard to recognize, while cicatrices after incisions in different directions, especially on the neck, may often cause great deformity by contractions and folds.

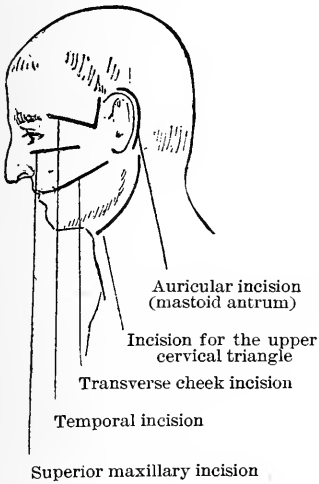

Fig. 8.

We therefore have added diagrams containing our normal incisions (Figs. 7, 8, and 9). Of course, these refer mainly to the large incisions made on the head, neck, trunk, and the articular regions. For the remaining incisions, especially in the inter-articular portions of the extremities, we have retained the straight longitudinal direction in the case of shorter incisions (for ligatures and the exposure of nerves) for the sake of simplicity. One glance at the figures shows that a portion of these

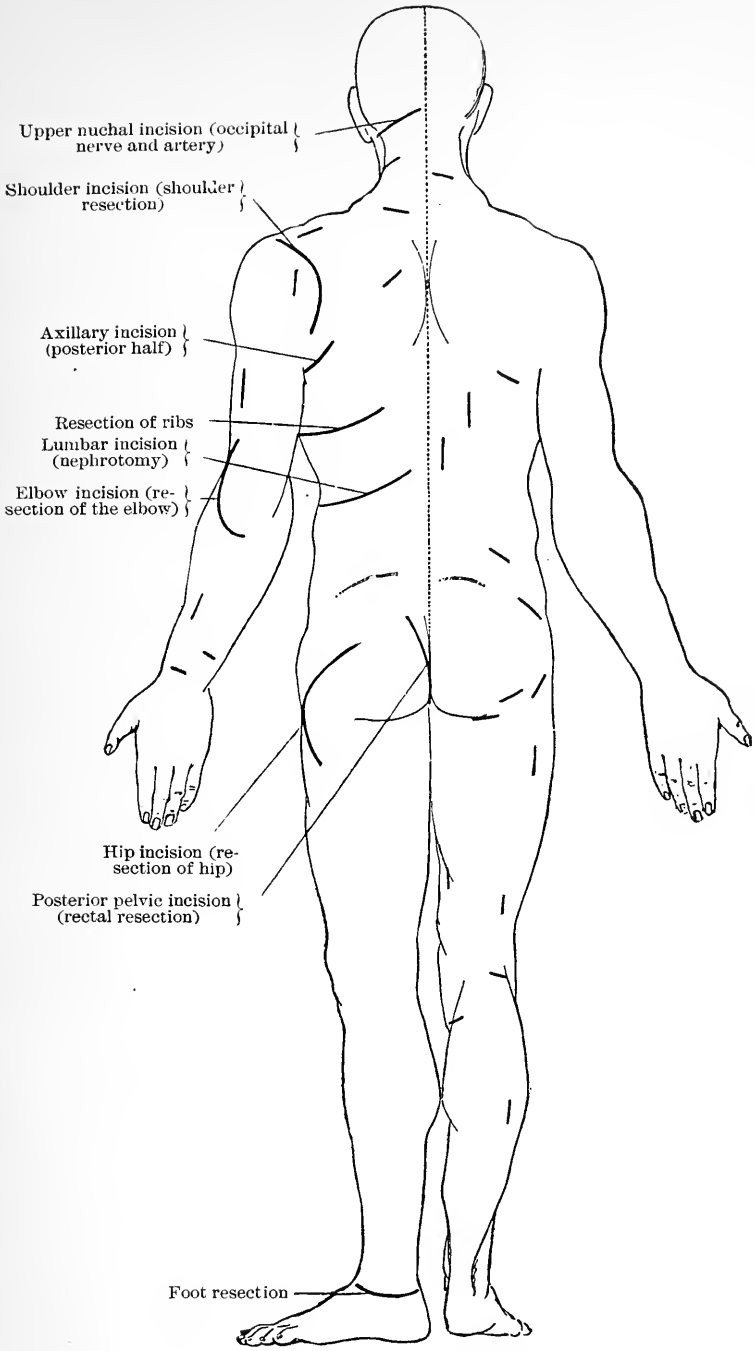

FIG. 9.—Normal Incisions.

longitudinal incisions likewise coincides with the cleavage lines of the skin.

We need hardly say that we include among the normal incisions all the longitudinal incisions placed in the median line of the body, that is to say, all the incisions corresponding to a vertical line from the vertex to the symphysis, across the perineum to the anus, and returning behind to the vertex.

In the case of amputations, of course, a coaptation of segments of skin naturally belonging together is out of the question. But even here it seems to be an advantage to keep to some extent to the cleavage lines of the skin, so as to have less retraction of the flaps.

How well the oblique incisions for amputations specially recommended by us fit the cleavage lines of the skin is shown by a glance at the figures.

PART II.

SPECIAL OPERATIONS.

E. The Skull.

a. Soft Parts.

THE soft parts of the skull are distinguished by a profusion of vessels, but these are easily accessible for ligation, as they pass through the scalp whose cutis and corium are firmly united to the galea. The arteries lie quite loose in the scalp, the veins less so, and hence they do not retract like the arteries. In arterial hemorrhage pressure is made on the skin next to the edge of the wound and the vessel is seized with an artery forceps; should this fail even with our arterial hook forceps, the needle is passed around it close to the wound.

The vessels which carry the blood to the dome of the head come from the forehead, the temples, and the occiput. If in profuse hemorrhages the flow is to be arrested from the centre, attention should be directed to these three points.

1. *Temporal Artery and Vein.—Auriculo-Temporal Nerve (Trigeminus III.).* (See Figs. 10 and 11.)—One centimetre in front of the ear the finger feels at the upper edge of the zygomatic arch the pulsation of the temporal artery; in hemorrhage of one of its branches pressure with one finger can here control it and it may be ligated at the same point. Incision is made in a vertical direction, one centimetre in front of the anterior end of the helix. After dividing the skin the fascia appears, namely, the superficial layer of the galea aponeurotica. Here the artery passes over the zygomatic arch and appears subfascially at its upper edge.

The position of the temporal vein is not constant; usually it lies parallel with the artery and behind it.

Of more importance is the nerve here situated which furnishes the sensory supply to the ear and the temporal region, the auriculo-temporal nerve (see Figs. 10 and 11) from the third branch of the trigeminus. It encircles the artery from behind

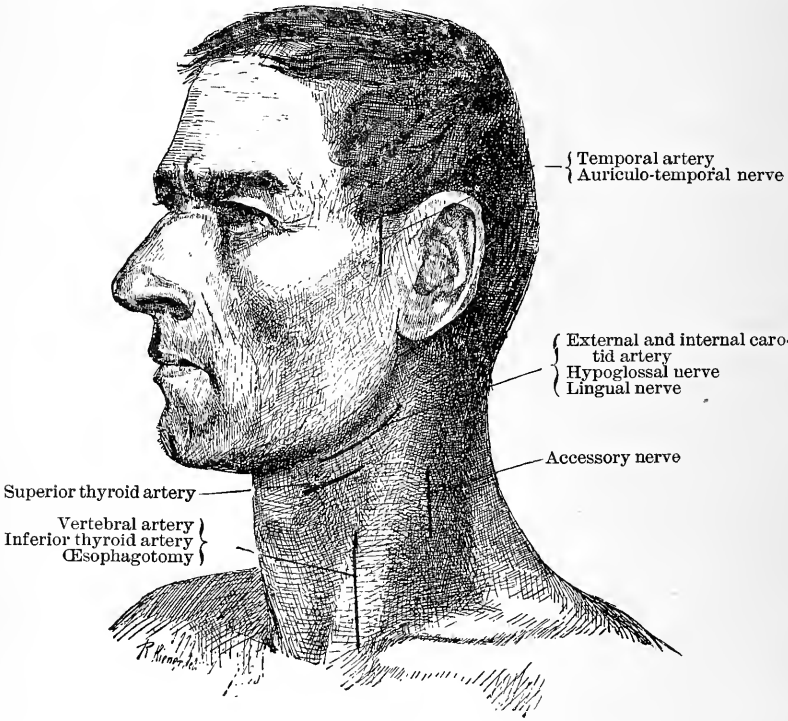

Fig. 10.

forward to above backward and passes upward parallel to its posterior side. If the nerve is to be stretched or exposed in the case of neuralgia, the artery is located and the nerve found nearer toward the ear. Higher up the branches of the nerve and the artery pass into the scalp.

2. *Supra-Orbital Artery.—Supra-Orbital, Frontal, and Ethmoidal Nerves* (Figs. 12 and 13).—The main artery of the forehead is the supra-orbital. It is smaller than the temporal artery.

As guiding-point for its ligation we have the palpable supra-orbital foramen; here the artery emerges in a sagittal direction from the orbit; it passes through the fibres of the orbicularis vertically upward under the galea. After shaving the eyebrow the incision is made transversely at the supra-orbital margin and carried deeper.

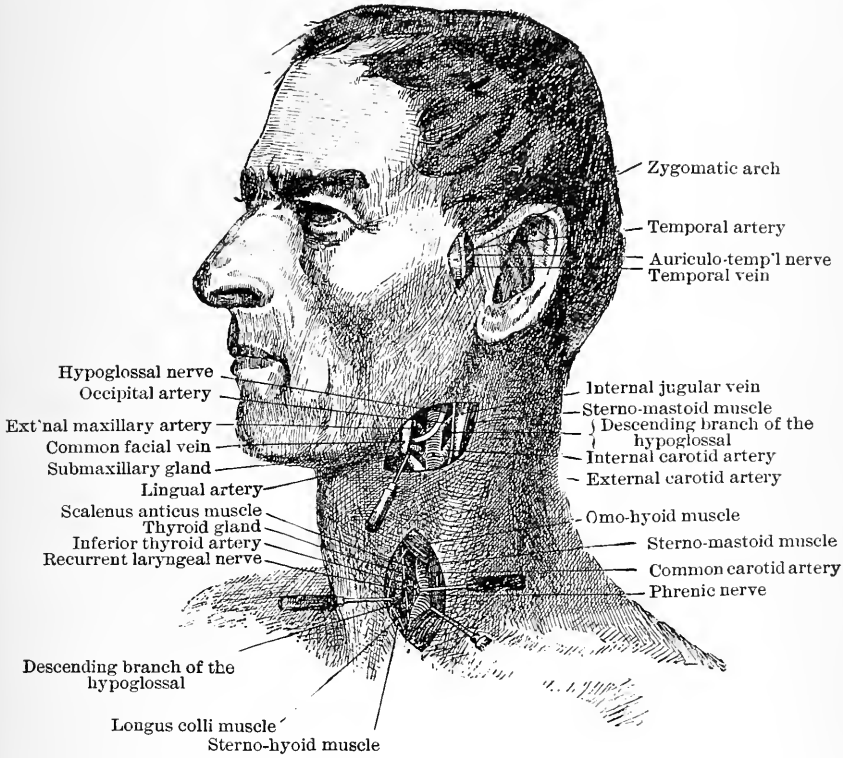

FIG. 11.

At the same point is the supra-orbital nerve. In supra-orbital neuralgia the supra-orbital foramen is likewise the best guiding-point for the incision because it can be positively located through the skin. The nerve lies deeper than the artery, immediately on the periosteum; it is not easy to sever the nerve without injuring the artery at the same time. The incision in the eyebrow has the advantage that it avoids the branches of the facial. The orbicularis and the frontalis muscles are sup-

plied by the facial; the corresponding nerve twigs enter them from a lateral direction and therefore are not touched by the transverse incision recommended.

3. The *frontal nerve* lies about two centimetres toward the median line from a vertical above the inner canthus; it is much thinner and more superficial in the fibres of the orbicularis, ris-

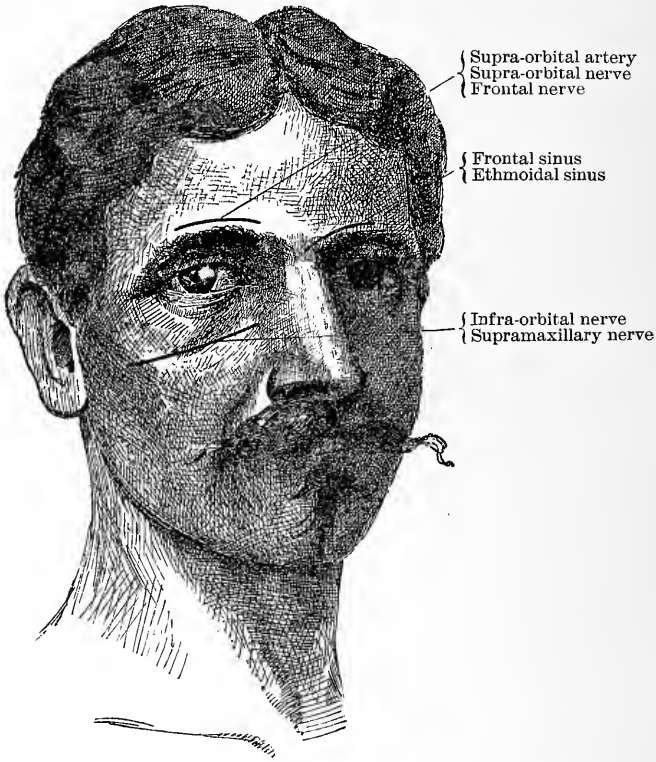

Fig. 12.

ing almost vertically. In order to expose it we use the inner half of the eyebrow incision.

4. The *ethmoidal nerve* (Fig. 12) passes at the inner and upper circumference of the orbit into the cranial cavity and leaves it again through the cribriform bone, spreading over the nasal septum and supplying with its terminal branch the tip of the nose. It can be well seen and ligated with an aneurism

needle, about 2 cm. behind the median end of the supra-orbital margin. The eyebrow incision is somewhat prolonged downward over the root of the nose (the branches of the angular artery and vein being ligated), the periosteum is divided, and at the inner and upper circumference of the orbit it (the peri-

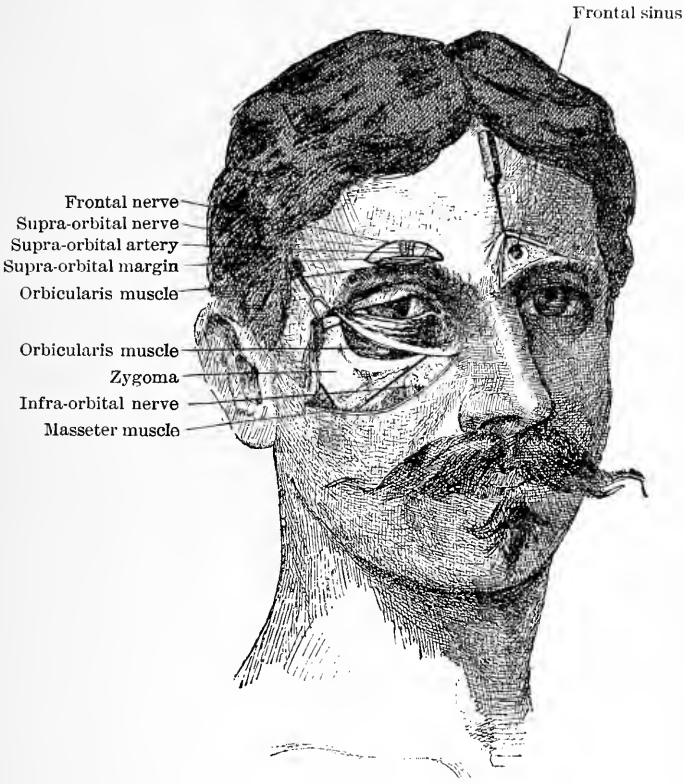

FIG. 13.

orbita) is slowly stripped off backward until the transversely stretched cord running to the anterior ethmoidal foramen is seen to separate from the roof of the orbit. The ethmoidal artery (from the naso-frontalis artery) is torn in this manipulation and the hemorrhage is arrested by tampons.

5. *Occipital Artery.—Major and Minor Occipital Nerves* (Figs. 14 and 15).—The occipital is the thickest artery of the

head. Midway between the occipital spine and the highest point of the mastoid process the artery emerges from under the median edge of the splenius muscle and piercing the fascia it rises toward the occiput, where it lies under the galea. The vessel is ligated at the point where it pierces the thick fascia. The incision for its ligation runs transversely in the line uniting the

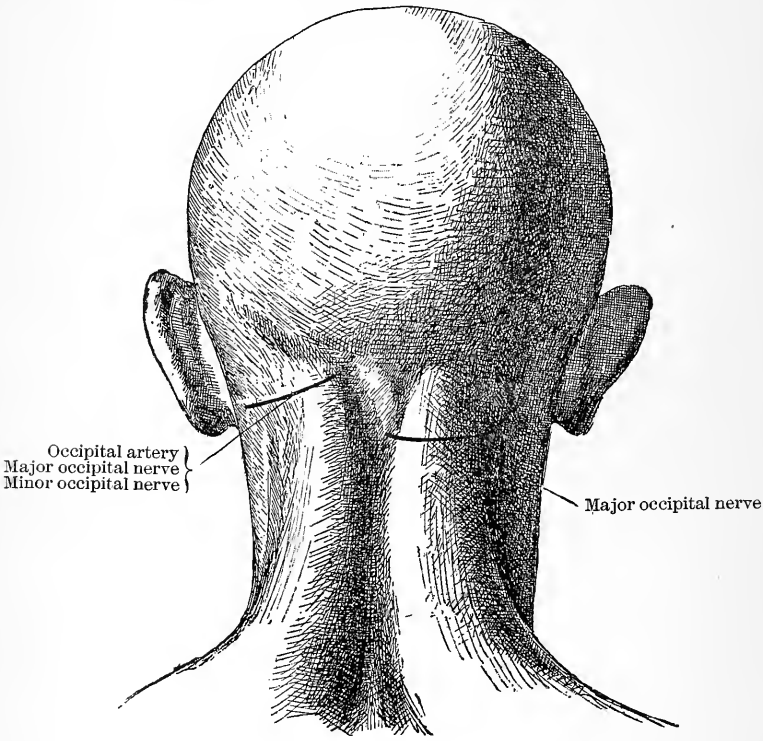

FIG. 14.

abovementioned points along the semicircular line from the posterior lower circumference of the mastoid process to the level of the belly of the trapezius. The skin here is very thick. Dividing the fascia, the posterior edge of the sterno-cleido-mastoid muscle is exposed, avoiding the minor occipital nerve (from the third cervical) which rises to the occiput along this edge (Figs. 14 and 15). Under the sterno-cleido-mastoid muscle ap-

pears the splenius capitis, whose fibres ascend obliquely forward; at its anterior edge is the longissimus capitis muscle. The splenius is divided in the direction of the cutaneous incision; the artery appears beneath it, first resting on the obliquus capitis superior, then on the semispinalis capitis muscle.

The artery can be ligated at the median edge of the splenius muscle, where it rises subfascially in the angle between the

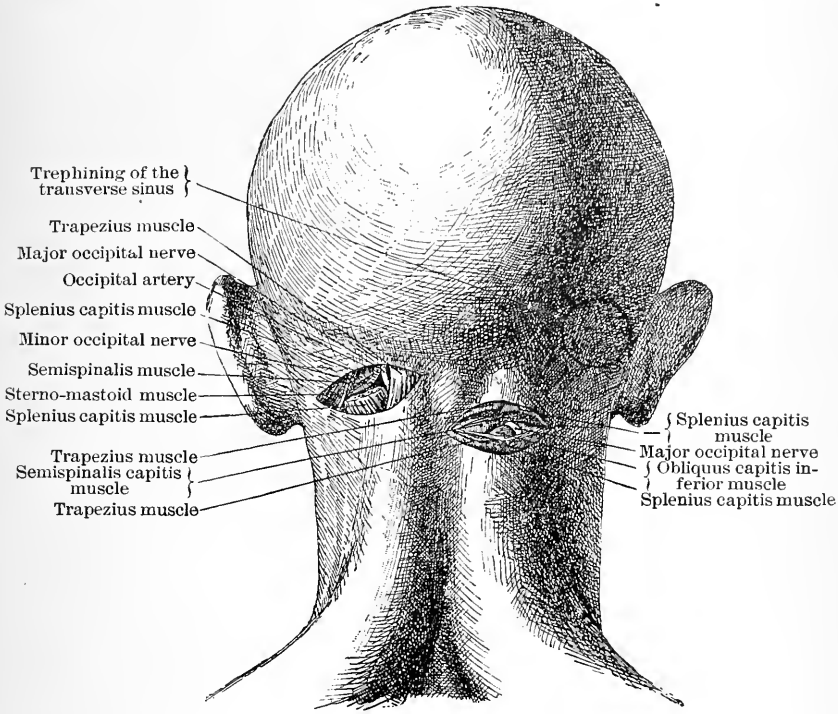

FIG. 15.

posterior edge of the sterno-cleido-mastoid and the anterior edge of the trapezius muscle to the skin of the occiput. At this point it is met by the major occipital nerve which comes from the median direction.

At its origin the occipital artery can be ligated through the same incision as the external carotid artery (which see). At that point it passes under the digastric and stylo-hyoid mus-

cles. The occipital vein is beside the artery, but its position is not constant.

6. The major occipital nerve (posterior branch of the second cervical (Figs. 14 and 15), after piercing the semispinalis capitis muscle, comes to the surface at the lateral margin of the trapezius muscle. On ligating the artery the nerve is usually found near its median side, the two approaching each other.

If a more central point of the nerve is sought for stretching, as in neuralgias, the incision must be made deeper (Figs. 14 and 15). Incision transversely at the height of the strongly projecting spur of the epistropheus, laterally from the median line. The comparatively thin trapezius is cut, beneath it the thick splenius capitis with its oblique fibres running upward and outward, and then the vertical stout semispinalis are divided, until the obliquus capitis inferior muscle appears, which runs outward and slightly upward. The thick nerve is seen upon it; it rises over the lower lateral edge of the muscle and runs transversely medially and upward. At this point the nerve, which is mainly sensory, contributes some motor branches to the nuchal muscles.

The minor occipital nerve (Figs. 14 and 15), from the third cervical nerve. After reaching the posterior margin of the sterno-cleido-mastoid muscle, it passes subfascially upward parallel to this margin to the occiput, giving off branches laterally from the field supplied by the major occipital nerve. (For its exposure see Occipital artery.)

b. The Relations of the Cerebral Convolutions to the Skull.

Since physiological experiments and complementary experiences of surgeons on the living patient have positively demonstrated that certain cortical regions of the brain represent foci[1] for definite functions of a motor, sensory, and tactile variety,

[1] We prefer this term to the word "centres" used by Horsley.

the surgeon is called upon to find strictly circumscribed portions of the brain cortex in paralytic and irritative conditions.

Different methods have been resorted to in order to obtain guiding points as to the relations of the cortex of the brain to the cranium or to points on the surface of the head accessible to palpation and inspection. These can be of service only in so far as they may be promptly applicable to different shapes and sizes of heads.

The method of percentage measurements introduced by Dr. Müller is one of the most reliable for striking again and again the same points. It consists in drawing connecting lines from two main lines which are subdivided in a definite manner. The relations of the points thus obtained to the regions of the brain lying beneath them are ascertained from a larger number of observations. Our procedure is an analogous one: Dr. Schenk, of Berne, has constructed for us an instrument consisting of two spring steel strips, which can be adapted and applied without difficulty to any skull by means of an elastic band running across the forehead, occiput, and temples. Being divided into centimetres and millimetres, the various lines can be adjusted to a relative percentage. By means of the elastic band the instrument is placed transversely around the skull (equatorial lines) so that its upper margin (point A) strikes in front the crista glabellæ (this is the name we propose for this ridge) which unites the arcus superciliares across the root of the nose, in width about equal to the thumb; behind it strikes the lowest point of the occipital protuberance (point B). The band passes directly over the upper attachment of the auricle. In a sagittal direction an elastic strip runs from the glabella to the occipital protuberance (sagittal meridian). On this meridian a second elastic strip bearing a graduated circle is movable and can be fixed at any desired point of the sagittal meridian and at any angle.

From the point midway (Figs. 16 and 17) between the crista glabellæ and the occipital protuberance (the upper pole of the

sagittal meridian = point C) we draw two oblique meridians, each at an angle of 60°, running forward and backward respectively (anterior [line CGHJ] and posterior [line CSTV] oblique meridi-

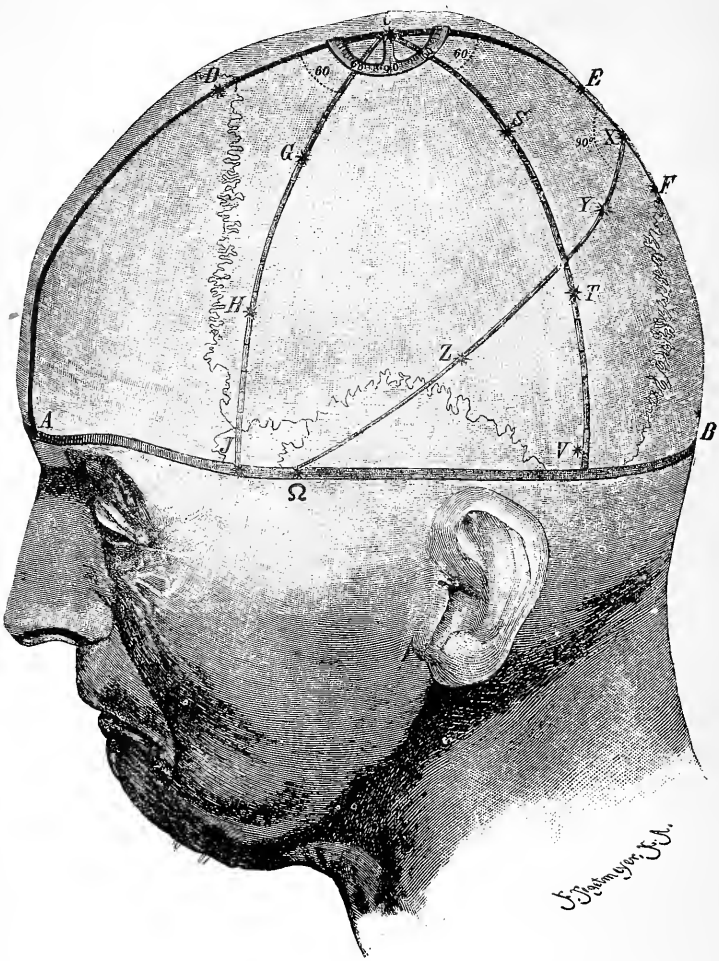

FIG. 16.

an). A third line is more complicated. For its construction the sagittal meridian is divided into three parts (anterior [point D] and posterior [point E] third point of the sagittal meridian). The posterior half of the sagittal meridian is divided into two equal parts (posterior fourth point [point F]). From the centre (point

X) between the posterior fourth point and the posterior third point extends an oblique line XYZΩ, the movable spring strip being applied from here to the surface of the head. At the temple it intersects the equatorial line about 1 cm. behind the oblique

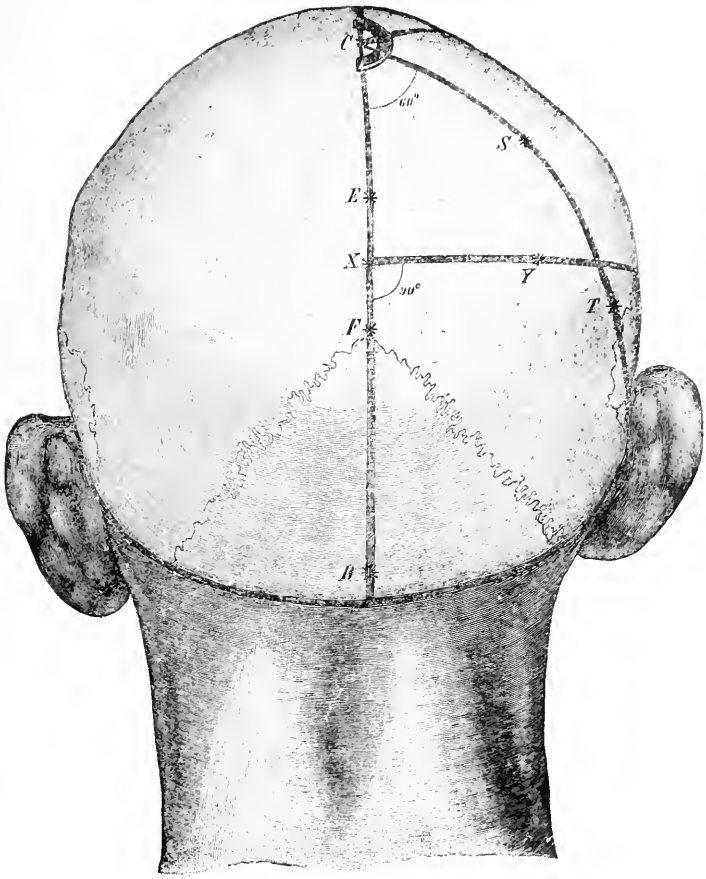

Fig. 17.

anterior meridian. The two oblique meridians and the oblique line are divided into three equal parts and thus we obtain a sufficient number of definite points for localization on the surface of the brain.

We have demonstrated on a large number of brains those points of the cerebral cortex which correspond to the above-men-

tioned points on the surface of the head and have convinced ourselves that we are thus put in possession of the main points whose function is known and whose location comes in question on the living patient. Instead of long explanations we have had the

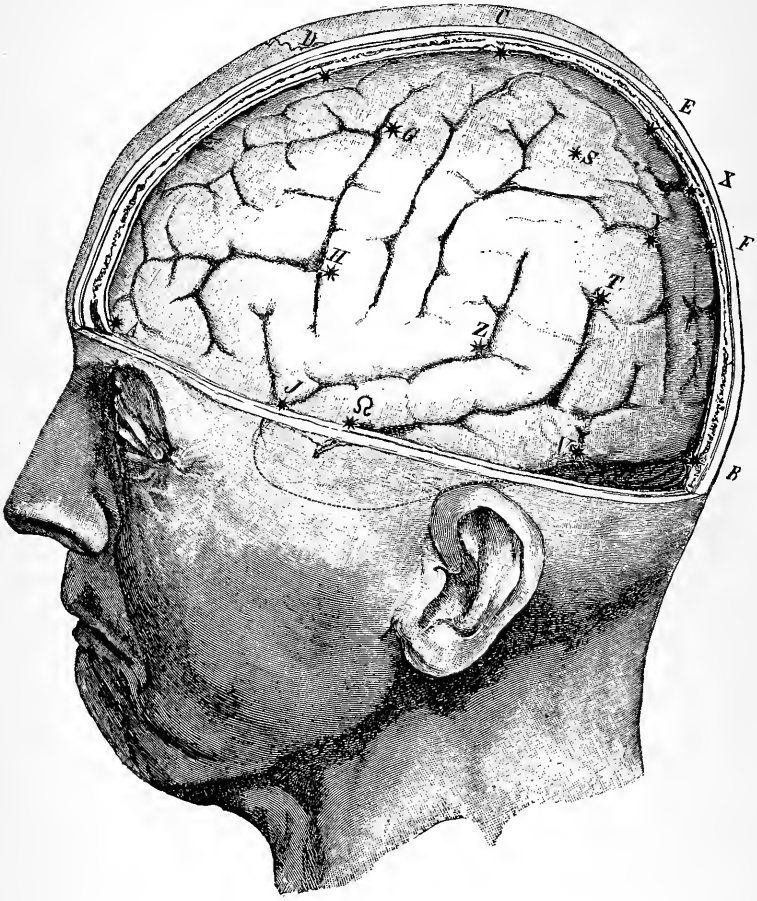

FIG. 18.

artist designate the points determined by the various observations (Figs. 18 and 19) precisely as we had marked them, after perforation of the skull at the respective points, by the injection of a minute drop of aniline solution with a hypodermic syringe.

The following remarks remain to be added regarding the

drawings. The equatorial line corresponds to the greatest horizontal circumference of the brain; in front at A it coincides with the anterior pole of the frontal brain, behind at B it lies nearly 1 cm. below the posterior pole of the occipital brain, and laterally it passes over the temporal lobe. The intersection

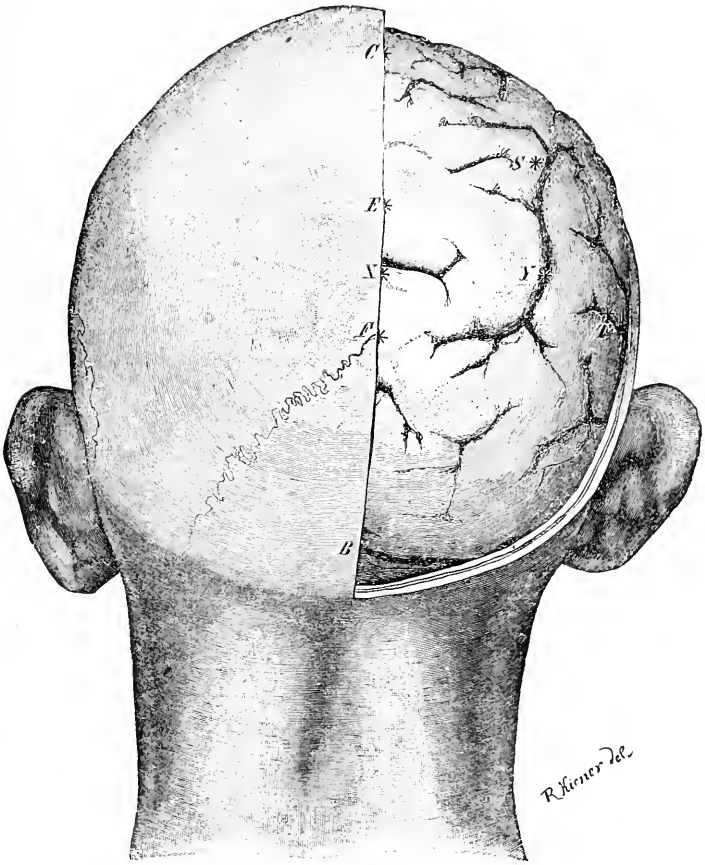

FIG. 19.

(J) of the anterior oblique meridian with the equatorial line is situated on the skull at the pterion (the junction of the frontal, sphenoidal, temporal, and parietal bones), and on the brain at the anterior end of the fissure of Sylvius, where the horizontal ramus of this sulcus passes into the anterior ascending one.

Hence it designates the depression between the frontal and temporal brain.

The intersection of the posterior oblique meridian with the equatorial line (V) marks the limit between the temporal lobe and the occipital brain. This point lies 1 cm. below the margin which divides the external and inferior surfaces of the brain. The upper pole of the sagittal meridian (C) lies at the highest point of the anterior central convolution in front of the fissure of Rolando.

The upper third point of the anterior oblique meridian (G) is the point where the anterior central convolution joins the first and second frontal convolutions.

The lower third point of the anterior oblique meridian (H) marks the place where the second and third frontal convolutions join the anterior central convolution.

On the posterior oblique meridian the upper third point (S) lies over the interparietal sulcus in the upper parietal lobe, exactly above the supramarginal gyrus.

The lower third point (T) of the posterior oblique meridian marks the posterior end of the first temporal fissure and hence lies under the angular-gyrus.

The oblique line at the intersection with the sagittal meridian (X) corresponds about to the tip of the lambdoidal suture on the skull and the parieto-occipital fissure of the brain.

The upper third point of the oblique line (Y) lies in the angular gyrus, the lower third point of the oblique line (Z) in the posterior end of the horizontal portion of the fissure of Sylvius. The intersection of the oblique line with the equatorial line (Ω) strikes the anterior end of the first temporal fissure.

It is at once evident that by these points we have sufficiently marked all the motor and sensory centres thus far known. On the skull the bregma (the point where the sagittal and the coronal sutures join) can be found by dividing the sagittal meridian into three parts. The anterior third point (D) corresponds to it and

marks the limit between the first frontal convolution and the anterior parts.

7. *Centres of the Brain Cortex.*—Basing on Horsley's classical investigations on the centres in the cerebral cortex of the monkey, we give a synopsis of the known centres of the human brain or the points where the skull must be opened in lesions of separate centres. In compliance with our request Professor Horsley was kind enough to send us autograph drawings which we here reproduce (Figs. 20 and 21). Comparison with the drawings shows that the known centres of the cerebral cortex are grouped in a simple manner around the points which our method of measurement enables us to determine.

The crown of the trephine is to be applied directly to the side of C for the lower extremity, or close to the middle line for its peripheral parts (hallux), and farther away, behind G, for its central portions (hip). According to the localizations drawn from certain monkey brains, the focus for the hip would lie half a trephine opening farther forward, and the same distance farther backward for the toes, especially the great toe.

The centres for the upper extremity are found by applying the trephine immediately behind G as far as H, at the upper portion for the shoulder and elbow, at the lower portion for the wrist, fingers, and thumb. According to other experiments, the opening for both fingers and thumb should be made half a trephine circle farther back.

Slightly downward behind the line GH, somewhat above the latter point and over the entire breadth of the two central convolutions, the trephine opening strikes the focus for the ocular portion of the facial, that is to say, for the contralateral closure of the lid. Behind the line HJ in the upper third lies the focus for the contralateral lifting of the angle of the mouth; in the middle third that for retraction of the angle of the mouth, and finally in the lower third above and behind J the centres for the larynx and pharynx, those for deglutition and mastication

and the opening of the mouth in an oblique backward and upward direction, the latter centre lying vertically a good finger's bread above Ω.

Up and down before H lies the focus for moving the head (as well as the eyes, according to our own clinical observations) to the opposite side. In front of the middle of the line HJ lies the point whose lesion is followed by motor aphasia (Horsley has failed to mark this point). Below the posterior half of the

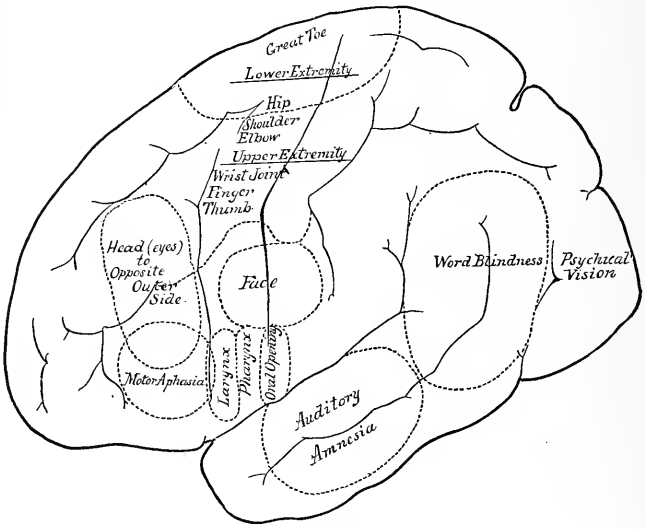

FIG. 20 A.

line ZΩ lies the focus for auditory aphasia; below the point T that for visual aphasia, and above BV the point for psychical vision or psychical blindness.

Exposure and possibly excision might also be effected for the centres lying immediately adjoining the median line on the median surface of the brain—those for the trunk muscles behind the point D or in the anterior half of the line CD; the centre for central vision (or hemianopsia) in front of the upper half of the line XB.

Finally let us indicate the point where in our opinion puncture of the lateral ventricles of the brain can be performed in

the most certain and least harmful manner. This may be done from above, from in front, and from the side. From the posterior half of the first temporal fissure we need only perforate 1

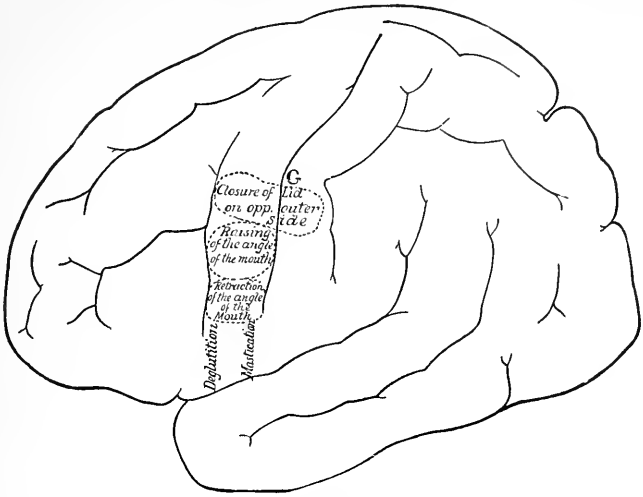

FIG. 20 B.

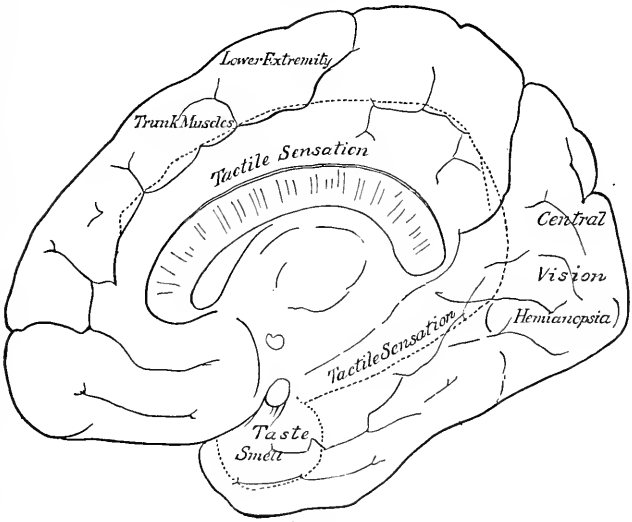

FIG. 21.

cm. of brain substance (counting from the depth of the fissure) in order to reach the posterior horn. In one of our cases of tubercular meningitis in which the trephine was applied behind and above the ear, in front of the posterior end of the crista temporalis

(see Fig. 23), the point below Z was exposed, and the lateral ventricle opened exactly at the bottom behind the posterior end of the caudate nucleus. But despite the exact location, after one thorough evacuation drainage failed—a fact we explained by collapse of the walls of the ventricles after evacuation, owing to the pressure of the brain substance from above.

In another analogous case direct drainage from above succeeded well and had a very good effect. Hence it is preferable to reach the ventricle from above rather than from below, although four or five centimetres of brain substance must be perforated. However, as puncture directly from above injures the centres for the lower extremity, it would be better to effect the object from without the motor region, namely, from above forward, laterally from the point D and forward of the point G. If puncture is made here, about 2½ to 3 cm. from the median line and 3 cm. forward of the precentral fissure, preferably in the fissure between the upper and middle frontal convolution, as shown in the figure, the ventricle is easily reached backward and downward, without the risk of a grave lesion of the cortex. At present we have under treatment a case of tumor of the brain, in which a drainage tube introduced in this manner carries off an ample amount of cerebro-spinal fluid. For this operation the crown of the trephine should measure at least 4 cm. in diameter, since according to Horsley the opening must be rather large.

8. As a guide we first make a puncture with a hypodermic syringe whose needle should be at least 6 cm. long; the dura is divided very slightly so that the drainage tube may be held rather firmly in the opening, and then we introduce one of our arterial hook forceps, by the opening of which we make room for the passage of the tube. As in all our cases, we employ a glass drainage tube, 6 cm. in length, which passes through a special small cutaneous opening, so that the main wound can be sutured throughout its entire extent and in order that the

opening in the skin may aid in keeping the tube in a definite direction. The escaping cerebro-spinal fluid is at first bloody but soon becomes quite clear, and as it often is abundant the dressings should be frequently changed early after the operation.

c. *Trephining.*

Having become posted as to the manner in which after incisions of the skull the right points can be found in the depth, and how and where certain nerves and vessels may be avoided or the latter ligated after injury, the incision for trephining should be made as a rule in the meridian, *i.e.*, rising vertically toward the vertex, because both nerves and arteries run from below upward. When a longitudinal incision does not suffice a flap is formed with the base below and a broad point above. The cross cut which is largely used does great damage. The incisions are made with a resection knife and carried vigorously down to the bone, the periosteum is divided and folded back with the flap, which is easily effected by the aid of an elevator; only at the sutures the periosteum adheres so firmly that it must be loosened with the knife. The bone is divided with the crown of the trephine, of the hand or bow pattern, or in recent times with small circular saws. Instead of the trephine the use of a sharp chisel and a hammer would be simpler, provided there is no ground for fearing the concussion connected with it. The chisel marks out the limit of the opening and the piece of bone thus loosened is lifted out with the elevator as soon as it proves movable; the edges are smoothed with Lüers' paring forceps. Particular care should be taken not to injure the superficial dural vessels.

Wagner's temporary resection of the skull with an omega-incision and chiselling out of the bone in connection with the soft parts for subsequent replacement appears indicated when very large openings are made and in diagnostic trephining.

The attempt to lift out the entire plate of bone with the loosely adhering periosteum does not always succeed.

9. *Trephining of the Longitudinal and Transverse Sinuses.*—Trephining over the sinuses of the dura mater is done only when this is the part to be exposed or opened.

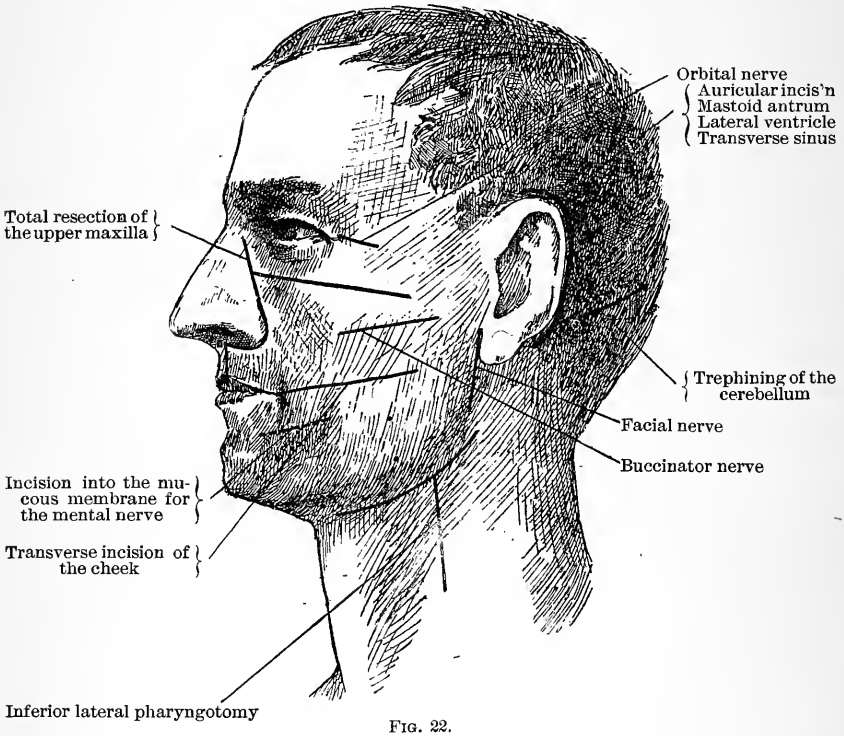

FIG. 22.

The superior longitudinal sinus lies to the right of the sagittal median line.

A much more important point is that of the

10. *Transverse Sinus* (see Figs. 22 and 23).—Here thrombosis and suppuration from extension of inflammations from the middle ear are of the most frequent occurrence. To locate the spot for trephining search is made for the most prominent point at the base of the mastoid process which appears posterior to the edge of the auricle. A finger's breadth higher lies the tem-

poral ridge which rises obliquely backward. Between this ridge and the former eminence on the inner side lies the transverse sinus which can be followed downward for some distance along the mastoid process. The incision is made along the posterior edge of the auricle (auricular incision, Fig. 22) and the posterior

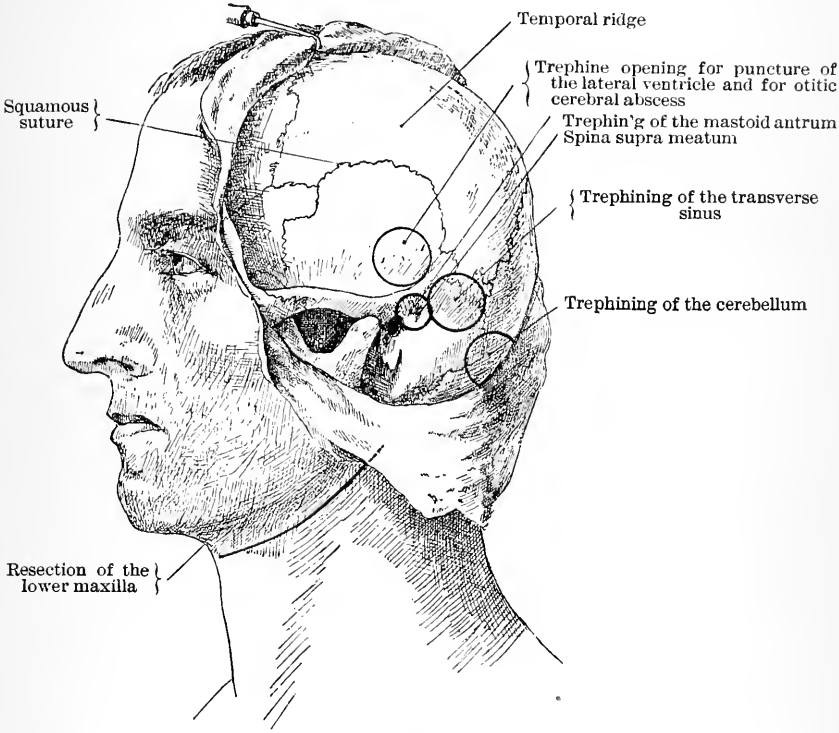

FIG. 23.

margin of the wound is drawn slightly backward. After chiselling through the skull the wall of the sinus is exposed. More frequently we are called upon to avoid the sinus in operations at this point, especially in opening the mastoid cells (which see).

11. *Trephining for Ligature of the Middle Meningeal Artery* (see Figs. 24 and 25).—The middle meningeal artery supplies the cerebral meninges with blood. For ligating it a point is usually selected (Vogt) two fingers' breadth above the zygomatic arch and a thumb's breadth behind the zygomatic process

of the frontal bone. But this point strikes only a part of the artery,[1] namely, its anterior branch. If the posterior branch is to be found at the same time, the trephine opening must be made immediately over the middle of the zygomatic arch (below our points Ω and I). At this point, however, not only must the

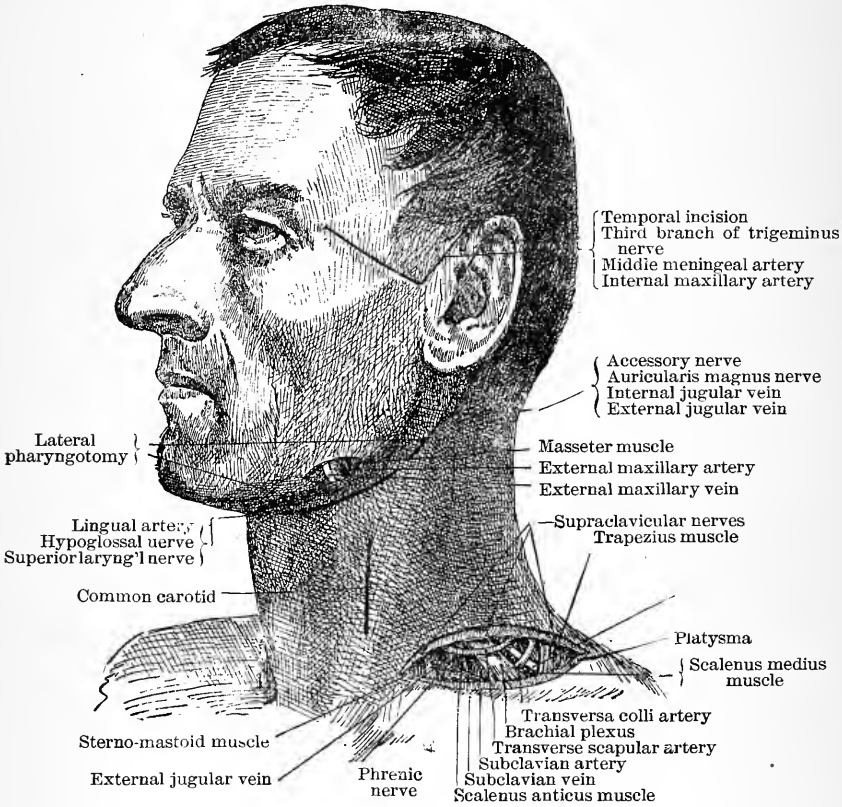

Fig. 24.

scalp and periosteum be divided, but the temporal muscle with its vertical fibres must be taken into account. But as an incision at this point must not extend below the zygomatic arch, owing to the branches of the facial nerve, a longitudinal division is not admissible, and our temporal incision must be used (see Fig. 25). This runs obliquely from the junction of the

[1] See Merkel's Anatomy, p. 65.

frontal bone and the zygoma[1] to the posterior end of the zygomatic arch, thence backward and upward; it divides the skin and the tense temporal fascia, and after ligature of the superficial temporal artery at the posterior edge of the temporal muscle strikes the bone from which the muscle and periosteum are turned forward. In this way we avoid hemorrhage from the

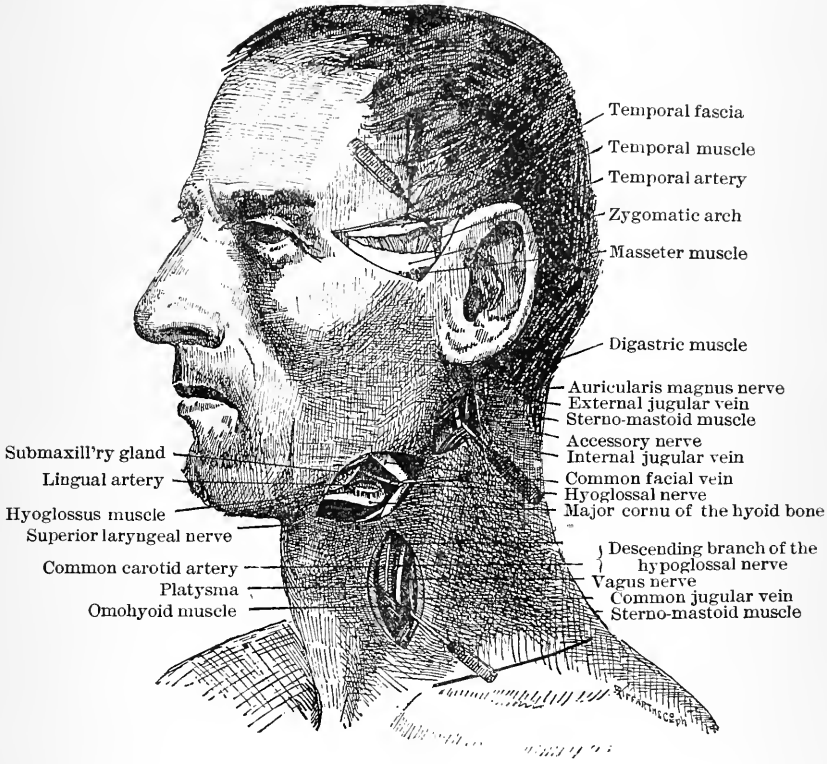

FIG. 25.

deeper temporal vessels and most certainly strike the spot on the squamous portion of the temporal bone under which the artery lies. The bone here is very thin.

There are two more points on the skull which we may either avoid in trephining or oftener purposely expose, namely, the

[1] In Fig. 25 the anterior incision is drawn somewhat too low in its anterior half.

frontal sinus and the antrum with the mastoid cells. Accumulations of pus in these cavities form the most frequent indications for their opening.

12. *Trephining of the Frontal Sinus* (Figs. 26 and 27).—After shaving, the incision is carried in a curve through the eyebrow down to the bone as far as the median line. The upper

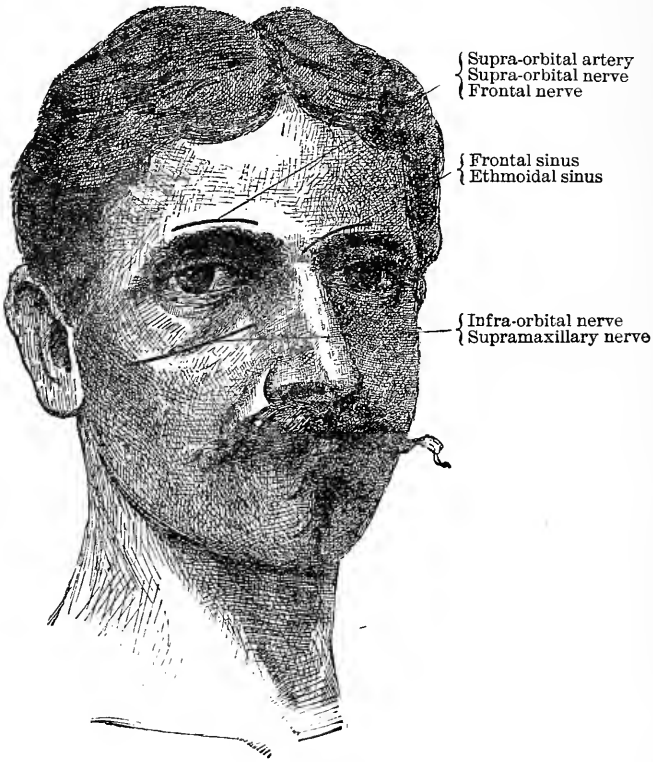

Fig. 26.

edge of the wound together with the detached periosteum is vigorously drawn upward. The incision divides the frontal and supra-orbital nerves and the artery of the same name; but, what is much more important, it avoids the branches of the facial extending to the frontal muscles, the corrugator, and the orbicularis. Rarely an additional vertical incision is required; this is carried obliquely upward alongside the median line. At the

inner end of the superciliary arch, after lifting the flap of skin and periosteum with the elevator, the sinus is opened with the chisel. The anterior wall contains diploë; hence some hemorrhage should be expected from its abundant vessels. The posterior wall is formed by the vitreous layer alone. Under the an-

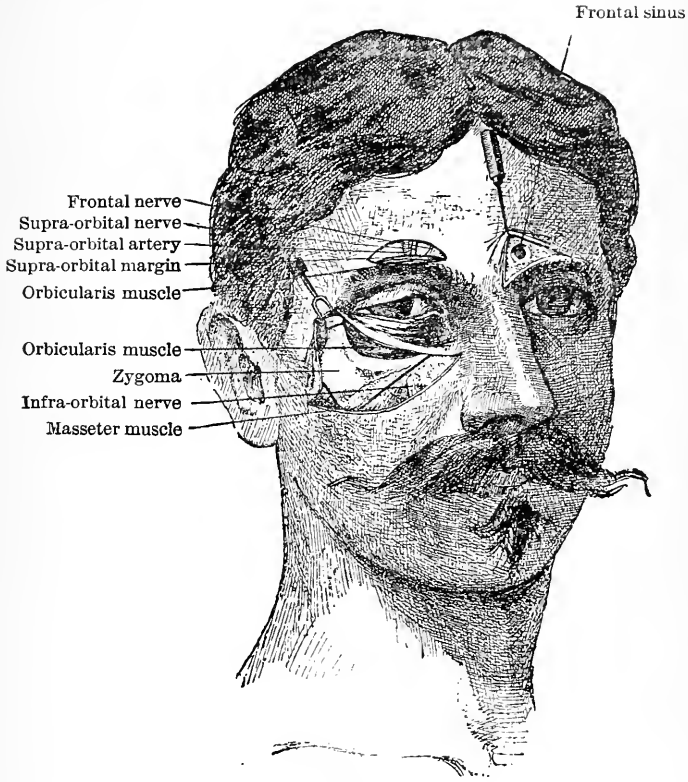

FIG. 27.

terior bony wall is the thin mucous membrane, which may be much thickened in the case of suppuration. After it is detached a probe can be carried backward and downward from the sinus into the nasal cavity beneath the anterior end of the middle turbinated bone, and after forcible dilatation without cutting, a permanent drainage tube may be carried to the same point.

13. *Trephining of the Mastoid Process* (Figs. 28 and 29).—

The surgeon is frequently called upon to open the bony cavities of the mastoid process.

As the drum cavity communicates with the mastoid antrum and the mastoid cells, infectious materials are apt to be carried there; stagnation favors their development, they attack the thin

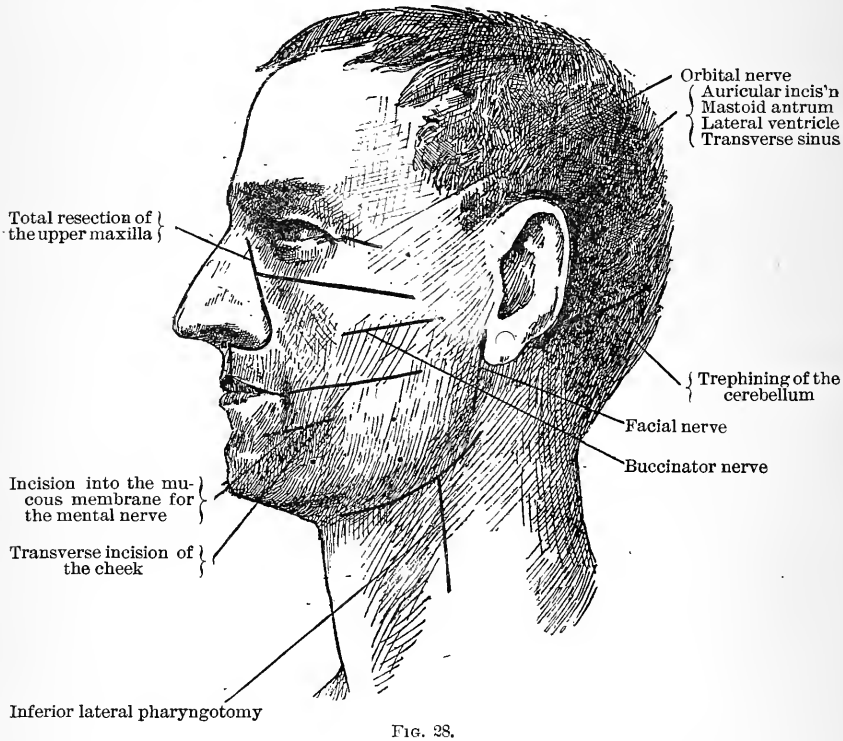

Fig. 28.

bony walls, and extend to the exernal and internal periosteum. Starting from the external periosteum a phlegmon forms behind the auricle. The internal periosteum is the dura mater and periostitis here is identical with pachymeningitis. This leads to the formation of cerebral abscesses in the temporal lobe or the cerebellum, to basilar meningitis, or to phlebitis of the transverse sinus, according to the point where the otitis passed into mastoid osteitis.

In opening the mastoid process we aim first at the mastoid

antrum as the cavity which is earliest involved from the drum cavity in accordance with the direct communication. While egress may be given to pus from the drum cavity by an incision into the membrana tympani, an artificial passage outward must be made for the mastoid antrum, whose anterior opening

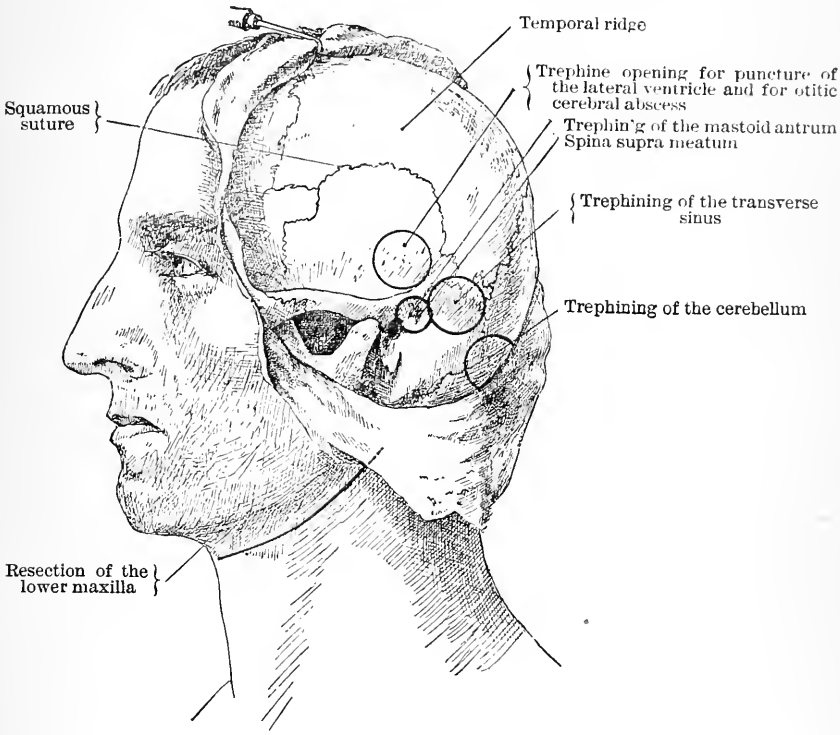

Fig. 23.

lies higher than the base of the cavity. This is still more necessary for the more deeply situated mastoid cells.

In exposing the cavities of the mastoid process, any unnecessary opening of the skull cavity is to be avoided, especially lesion of the transverse sinus and the facial canal or nerve.

In order to reach the mastoid antrum surely by the most direct road without incidental injuries it is necessary to expose the entire process by a large incision. The latter is made parallel to the posterior margin of the auricle, the periosteum is

pushed away as far as needed forward and backward, so as to expose the bony process. The spina supra meatum behind and above the bony auditory meatus serves as a guiding-point for the application of the chisel which must penetrate vertically, *i.e.*, in a median direction. At a depth of about 1½ cm. the mastoid antrum is opened. Downward and somewhat backward of this we strike the mastoid cells by chiselling away the superficial layers of bone as far as the point of the process. In this way all the mastoid cells can be exposed. By deviating forward from the direction indicated, or by penetrating deeper into the bony auditory canal, we strike the facial canal. By deviating backward we strike the transverse sinus, and higher up we open the cavity of the skull (Figs. 28 and 29), and above the base of the pyramid of the petrous bone we come to the posterior part of the temporal lobe of the brain through which the lateral ventricle may be opened at its lowest point. When suppuration has extended in any of these three directions this course is purposely followed.

14. *Trephining of the Cerebellum* (Fig. 29).—This is performed below the superior linea nuchæ behind the mastoid process, by means of a transverse incision down to the bone along that line. The muscles here attached (posterior end of the sterno-cleido-mastoid, splenius, longus capitis) are turned down with the periosteum, and the crown of the trephine is applied back of the mastoid process. The minor occipital nerve is divided, the major occipital nerve and the occipital artery are lifted and turned down with the soft parts.

F. The Face.

The condition of the skin of the face differs from that of the skull in being looser, but it is likewise exceedingly vascular. Hence we must be prepared for spurting arteries even in the cutaneous incision. Most of the vessels lie beneath the cutis.

As to the direction of the incisions the same rules apply as

were given for placing normal incisions in general. The first care in operations on the face should be to avoid the facial nerve; incisions must be chosen which run parallel to the branches of this nerve, for every injury to it means deformity.

It matters very much less when an arterial twig is severed than when ever so small a nerve is cut. Accordingly the incisions will be so placed as to radiate from the point of entry of the facial nerve into the parotid as a centre. In this way we guard against disturbances of facial expression. Of course a portion of the vessels will thus be cut across. On the other hand the normal incisions coincide with the direction of Steno's duct to which they are parallel. The muscles must be divided in part. In general, however, division of muscles is avoided and the direction of their interstices is preferred, because wounds of muscles heal badly after infection. The latter factor no longer enters into the question under asepsis; with it we may obtain a rapid cicatrization of the muscle with complete restoration of its function, provided the afferent nerve twigs have been left intact.

In our operative surgery we always come back to this point: rather divide even a strong muscle (as for instance the rectus abdominis) and produce an artificial *inscriptio tendinea* than injure the afferent nerves, and thus cause paralysis and atrophy of the muscle. The chief artery of the face is the external maxillary.

15. *Ligature of the External Maxillary Artery.*—The point of ligature of this artery can be exactly determined: it passes up over the edge of the jaw, precisely at the anterior margin of the masseter muscle, accompanied by the anterior facial vein, whose course is not quite constant. An incision is made through the skin and platysma at the anterior edge of the masseter, parallel to the margin of the maxilla, and the artery is dissected out with careful avoidance of the marginal branch of the facial nerve which passes along the border of the maxilla.

16. *Operations on the Nose and the Nasal Cavities.*—Penetration into the nasal cavities through the nostrils finds no application in serious nasal affections such as the deep inflammations or malignant neoplasms. In such diseases the interior of the nose must be made directly accessible to palpation and inspection.

A simple method for this purpose is furnished by the splitting of the nasal septum recommended by us. The blades of a strong pair of scissors are passed into both nostrils as far as possible and the cartilaginous septum is divided; this causes the small arteries of the septum to spurt. Then the finger can be easily introduced into the nose and the walls palpated. In ozæna this manipulation suffices to render further procedures clear, especially to find circumscribed disease of the bones and to remove affected pieces of bone. Two sutures suffice to effect so exact a coaptation that no sign of the operation remains.

17. But if a view into the nose is desired further access must be gained. This is obtained by a division of the nose by means of a median section (see Nasal incision, Fig. 7). But the division should not be made exactly in the middle, because the nasal cartilage shows a depression at its most prominent part and the cicatricial retraction after exact median division marks the above-named depression externally, thus leading to no inconsiderable deformity. Therefore the cartilage and nasal bones are divided slightly to one side of the median line, thus securing a cicatrix which later is hardly visible. When, after the anterior division, the frontal process of the upper maxilla and the base of the nasal bone are chiselled through past the lachrymal sac and upward from the pyriform aperture, one-half of the nose can be turned over and a good view is obtained throughout the entire cavity in question.

Another method is the lateral division of the nose (see Fig. 28). When the disease is situated laterally and extends to the upper maxilla, the incision is carried only around the ala nasi

and upward in its groove, either merely along the osseous pyriform aperture, when the loosened half of the nose is turned over toward the centre, or the incision is carried higher, the chisel being used to split the frontal process of the maxilla upward and the nasal bones transversely. This procedure gives free access to the anterior portion of the nose. By this means tubercular ulcerations may be subjected to a very exact local treatment. Of course, the method has the disadvantage that it destroys the function of some muscular fibres, namely, the nasal muscle which springs from the alveolar margin of the upper maxilla and goes to the dorsum and ala nasi, and the levator alæ nasi. Yet as the divided muscles may be made to heal by first intention and the afferent nerve fibres remain partly intact, no material disturbance of the expression results. When correctly sutured, the cicatrix becomes in a short time invisible. Of the vessels, the alar branches of the angular artery are divided; the latter artery is to be preserved in the upper portion of the incision. If a deeper view into the nasal passages is desired than can be gained by the above method, a partial osteoplastic resection of the upper maxilla may be made (see Fig. 28), and the inner, anterior, and a portion of the upper wall of the maxillary sinus turned outward, when inspection can be carried to the choanæ. Further details will be found among the methods of resection of the upper maxilla.

Another way of obtaining free access to the posterior portion of the nasal cavity consists in division of the hard and soft palate by a median incision. The mucous and periosteal tissues are detached toward both sides and the horizontal plate of the palate with a portion of the vomer is chiselled out (Gussenbauer). By this means we expose the most posterior part of the nasal cavity as far as the upper pharynx, and tumors of the base of the skull (fibromas and fibro-sarcomas) can be removed under thorough control. In a case recently operated on for relapsing sarcoma of the base of the skull and the posterior roof of

the nose, we gained a very full view of the field of operation by splitting of the upper lip, transverse separation of both alveolar processes from the upper jaw, and median division of the hard and soft palate, while the subsequent disfigurement was trifling.[1]

18. For opening the cavities of the sphenoid bone the above-mentioned method of Gussenbauer is the most appropriate. The sphenoid cavities open into those of the nose at the posterior margin of the upper turbinated bodies. They can be opened at the upper circumference of the choana between the posterior margin of the middle turbinated body and the ala of the vomer, by perforating the roof of the nose with a narrow sharp spoon.

Through the opened nasal cavity, under the anterior end of the lower turbinated body, 1½ cm. behind the margin of the pyriform aperture, we reach the naso-lachrymal canal beneath the middle turbinated body; 2½ cm. behind the same margin in a lateral direction we strike the antrum of Highmore; above this opening, beneath the same turbinated body, a probe can be carried into the efferent duct of the frontal sinus. The direction of this latter canal, as well as that of the nasal duct, is about parallel to the lateral margin of the pyriform aperture.

Another operation for exposing the nasal cavities without injuring the facial nerve is an incision from the sublabial mucous membrane. Without touching the face, the mucous membrane is detached at the junction of the gums with the upper lip, the attachment of the cartilaginous nose to the pyriform aperture is divided, and the whole of the soft parts (nose and cheek) is turned up to the eyes (Rouge); if the septum is divided in addition, the entire nasal cavity is accessible from in front. This operation has the advantage of leaving absolutely no deformity, but it causes profuse hemorrhage.

19. *Free Exposure of the Antrum of Highmore* (*Maxillary Sinus*).—One method of reaching the antrum we have learned

[1] Dr. Lanz will furnish a more minute description of this method of operation.

in connection with exposure of the nasal cavity. Even when ample exposure is desired it is customary to avoid an external incision and to proceed through the mucous membrane, either from the mouth or from the nose. The antrum frequently contains purulent foci after prolonged inflammations, and therefore we are often called upon to open the maxillary sinus permanently. The point from which access is most readily gained for the purpose of free exposure and careful examination is the canine fossa. We lift the upper lip, divide the mucous membrane and periosteum at the point of flexion above the root of the three anterior molars, lift the periosteum upward and outward with the elevator to below the infra-orbital foramen, and cut through the thin bony wall with the hollow chisel. The two strong bony ridges beside the canine fossa, namely, the frontal process and the edge of the zygoma, are left intact.

A second mode is an upward opening with a perforator through the alveola of a missing or drawn tooth, preferably the third or fourth molar.

20. A third method of opening the antrum without a cutaneous incision is from the nose. The thin median wall of the sinus is perforated exactly below the middle of the lower turbinated body from the lower nasal fossa, with a curved-pointed instrument (Mikulicz). This method has the advantage that the pus does not escape into the mouth, but into the nose. Its drawback is that it does not open the lowest part of the antrum as do the operations through the mouth. The two last-mentioned methods do not permit direct inspection, or palpation of the antrum with the finger. But this is possible in opening through the canine fossa.

Operations on the Nerves of the Face.

21. *The Facial Nerve* (see Fig. 22).—The surgeon is called upon to expose the facial nerve in order to protect it during operations in the retro-maxillary fossa, as in excision of swollen

lymphatic glands and tumors of the parotid. Besides, the facial is occasionally exposed in order to stretch it in cases of spasm of the facial muscles. The guiding points for the incision are the anterior margin of the mastoid process and the posterior margin of the maxilla (Hüter, Löbker, Kaufmann). The lobe of the ear is divided at its anterior edge as far as the auricle along the point of attachment; this incision is prolonged downward to behind the angle of the jaw; the point where the facial nerve comes forward corresponds about to the middle between the angle of the jaw and the zygomatic arch. The skin and the parotid-masseteric fascia are divided, the parotid is exposed at its posterior margin and completely drawn forward. The tendinous fibres of the attachment of the sterno-mastoid muscle are then visible and along them the incision is carried deeper at the anterior circumference of the mastoid process. The facial nerve is seen 1 cm. deeper, where it emerges from the stylo-mastoid foramen toward the surface.

The Trigeminus Nerve.—The main indications for exposure of the fifth cranial nerve are neuralgias. For finding its first branch see "Ligature of the Supra-Orbital and Frontal Artery," pp. 34 and 35, Figs. 26 and 27.

22. *The Second Branch of the Trigeminus* (see Figs. 30 and 31).—The main branch of this nerve, which is most frequently attacked by neuralgia, is the infra-orbital. In order to stretch it the mucous membrane at the point of transition of the upper lip may be divided from the mouth as far as the canine fossa. Having reached the periosteum, this is lifted upward to the infra-orbital foramen. One-half centimetre below the middle of the infra-orbital margin the nerve can be exposed and stretched with an aneurism needle and vigorously drawn forward with the finger.

A very good method, though it requires an external incision, is the following: Incision in the course of our normal upper maxillary incision (Figs. 12 and 13), beginning 0.5 cm. below

the median end of the infra-orbital margin, extending somewhat obliquely downward and outward to the most prominent part of the zygoma so as to strike the zygomatic muscle at its origin, and spare the branches of the facial supplying the muscles below and the orbicularis oculi. The incision goes down to

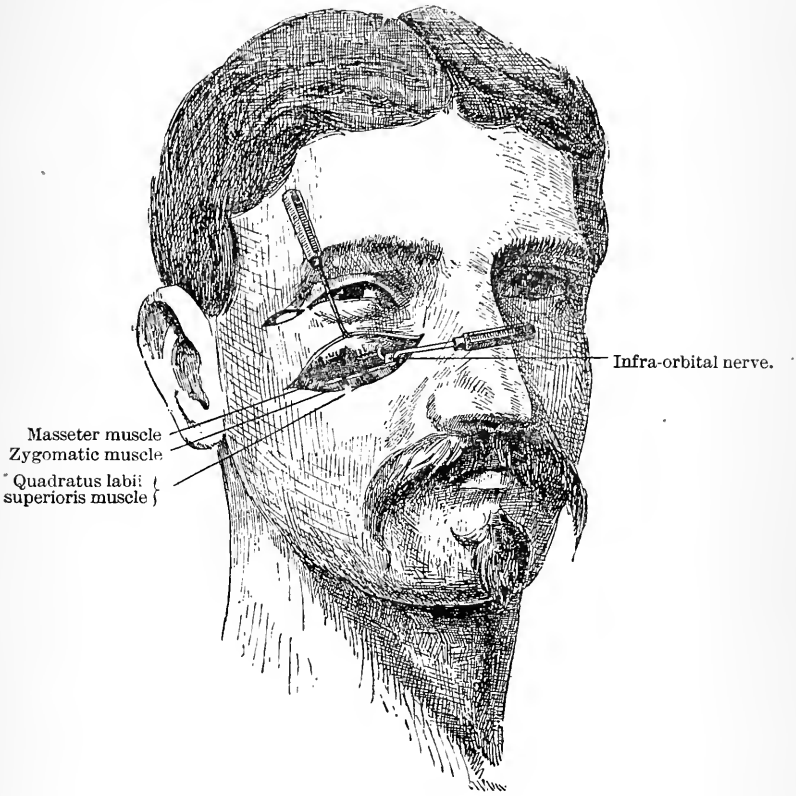

Fig. 30.

the bone and divides the attachment of the quadratus labii superioris muscle. The periosteum is turned down as far as the point of emergence of the nerve from the infra-orbital canal, where it is to be isolated from the infra-orbital artery and an aneurism needle passed around it. Above, the periosteum is turned back over the infra-orbital margin and from the floor of the orbit until the beginning of the infra-orbital canal

is felt or seen (Wagner); then the thick upper wall of the canal is chiselled out with two blows of the instrument. In this way the nerve can be exposed, stretched, or resected for a considerable distance. If the antrum of Highmore has not been opened, the wound will certainly heal by first intention, without resulting deformity; this is, however, the rule even after opening the antrum.

If, however, a permanent result is to be obtained in operations for neuralgia, the second branch of the trigeminus must be resected at the foramen rotundum. For the infra-orbital nerve subdivides into the orbital and the superior posterior alveolar before it enters the orbit, and the trunk of the second branch of the trigeminus, the supra-maxillary, gives off in the spheno-palatine fossa, besides the infra-orbital, the spheno-palatine nerve which passes downward to the nasal ganglion. The latter branch is not to be found isolated, but some of the twigs of the infra-orbital can be.

23. *Resection of the Orbital (Zygomatic) Nerve* (Fig. 30).—Incision 1 cm. long at the outer margin of the orbit, running obliquely outward and downward, beginning near the outer canthus and extending to the bone. The periosteum is detached from the lateral wall of the orbit, and with it the nerve is torn from its point of entry into the orbital surface of the zygoma.

The superior alveolar nerves have been isolated in the following manner (von Langenbeck). After lifting the lips a large incision is made over the teeth down to the bone, and the saw or chisel divides the lateral wall of the antrum with the mucous membrane from the nasal cavity to the pterygoid process.

24. In proportion as operations for neuralgia are limited to the division of peripheral branches the prospects for permanent recovery become less. When, however, the supra-maxillary nerve is exposed at the foramen rotundum (Figs. 12, 13, 30, and 31), the only branch missed is the recurrent supra-maxillary

passing to the dura mater. On the other hand, this central operation has the drawback of causing paralysis of the motor branches of the facial for the palatal muscles, which enter the nasal ganglion and join the palatal nerve through the Vidian.

The foramen rotundum is reached with difficulty. Von

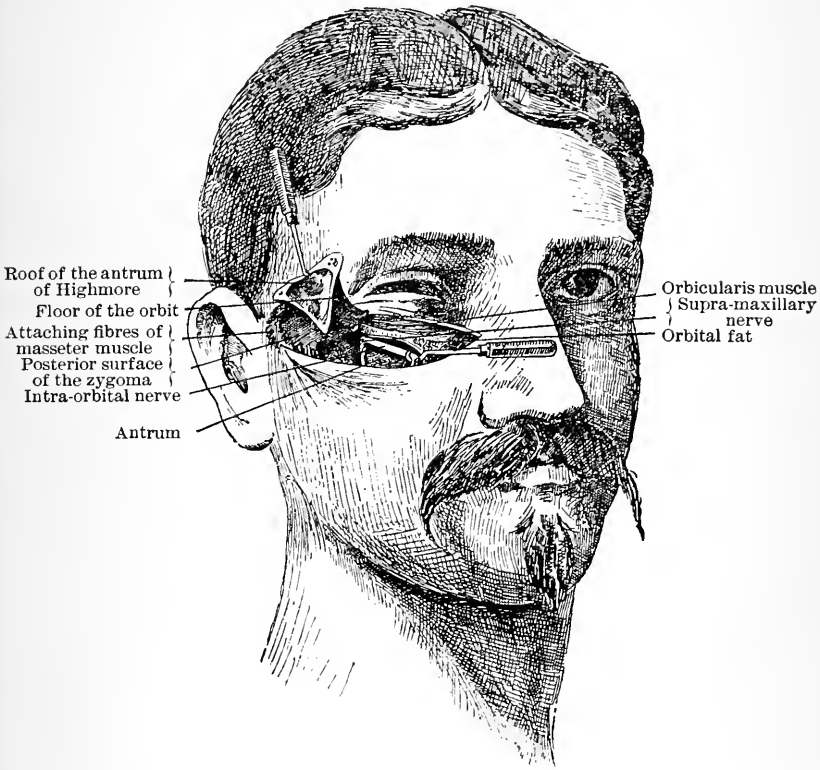

FIG. 31.

Langenbeck inserts a tenotome at the external orbital margin under the external palpebral ligament. This method has been abandoned because it does not guard against incidental injuries and wounds the infra-orbital artery. For this reason resection of the zygoma is now generally practised (Lücke, Lossen, Braun). On the principle that all incisions are incorrect which run across the branches of the facial, we proceed in the following manner. Incision as for exposing the infra-orbital nerve

(see Figs. 12 and 13), but longer, *i.e.*, beginning 1 cm. in a median direction from the palpable infra-orbital foramen, running somewhat obliquely downward, but mainly horizontally outward over the lower part of the zygoma to the anterior edge of the masseter muscle. At the inner end of the incision the angular artery and at the lateral end the transverse artery of the face are drawn down or ligated; Steno's duct remains below. At the median end the incision passes down to the bone between the lower margin of the orbicularis oculi muscle and the origin of the quadratus labii superioris; the former muscle is lifted off with the periosteum as far as the orbit, the latter is detached under the periosteum until the infra-orbital nerve is exposed, where it emerges from the canal of the same name and can be grasped with an artery tenaculum.

The lateral portion of the incision passes above the attachment of the zygomatic muscles to the anterior edge of the masseter. The former are divided at their origin, and the foremost portion of the attachment of the masseter to the lower and inner surface of the zygoma is detached.

The body of the zygoma is freed inward and outward in a vertical direction by means of an elevator (Fig. 27) so as to be chiselled through. The zygomatic process of the upper maxilla is freed at its anterior surface to the infra-orbital foramen, at its posterior surface to the inferior orbital fissure so that the upper wall of the infra-orbital canal can be lifted with it, and the infra-orbital nerve drawn with a hook in a median direction through its entire length. Then the upper maxilla is chiselled through so that the orbital plate and the lateral wall of the antrum together with its posterior angle remain in connection with the zygoma and can be lifted with it.

In order to effect luxation of the zygoma, the connection of the frontal bone with the zygoma is exposed by a small incision (see Fig. 30), and the chisel carried through to the posterior part of the inferior orbital fissure so that it is possible to remove

simultaneously also its upper border, namely, the crista zygomatica and orbitalis of the sphenoid bone. The zygoma is luxated upward and outward from the large wound by means of a strong, sharp hook, the orbital fat is carefully lifted with a blunt hook, and then it is easy to follow the tense infra-orbital nerve across the gaping Highmorian cavity to the foramen rotundum, and to introduce a small hook, behind the spheno-palatine nerve which runs vertically downward, around the main trunk and to divide it, or tear it as Thiersch does. The infra-orbital artery is torn when the zygoma is detached and luxated; the hemorrhage is arrested by tampons. At the end of the operation the zygoma is replaced. No bone sutures are needed for its fixation. Then the cutaneous wound is closed. The cicatrix causes absolutely no disfigurement.

The third branch of the trigeminus (Figs. 32 and 33) at the foramen ovale contains both portions, namely, the motor (postero-externally) and the sensory, so closely intertwined that they cannot be separated. Hence a central division of the nerve has the drawback of an incidental injury which is not intended, namely, unilateral paralysis and atrophy of the muscles of mastication. Fortunately experience (our own included) shows that this unilateral paralysis *per se* does not seriously limit the function of the maxilla; it merely lessens the force of the closure of the jaw and the amplitude of the lateral motions. Still the above drawback connected with the division of the trunk at the foramen ovale would justify the attempt to stretch or divide only single branches in neuralgia, despite the uncertainty of the result.

Particularly the lingual and the alveolar nerves are frequently the seat of neuralgias, especially the latter in its course through the infra-maxillary canal, from which it again emerges as the mental nerve. Besides we occasionally meet with neuralgias in the auriculo-temporal and the buccinator nerves which supply the region of the angle of the mouth.

The *inferior alveolar nerve* (Fig. 28) can be rendered accessible at different points.

25. If the terminal branch alone, the mental nerve (Fig. 28), is sought, the lower lip is vigorously pulled away from the maxilla, the mucous membrane is incised vertically at its turning-point under the interstices of the first and second premolar teeth of the lower jaw, the periosteum is divided, and the nerve is seen to emerge from the mental foramen. Usually, however, the seat of the neuralgia is higher up in the region of the teeth. Hence the nerve must be exposed before it enters the infra-maxillary canal. To reach it there two methods have been chiefly employed.

26. *Inferior Alveolar Nerve* (Fig. 29).—*a.* Trephining of the ascending ramus by an incision at the margin of the angle of the jaw. But at this very point run the branches of the facial which supply the muscles of the chin and lower lip. Hence the angle of the jaw must be approached by a curved incision, the marginal branch being withdrawn and the facial carefully dissected out (compare the posterior part of our normal incision for the upper cervical triangle, Fig. 29). Then the fibres of the masseter are partly detached upward from the maxilla by means of the elevator without cutting, the muscle together with the upper margin of the wound is held up with a blunt hook, and a piece of bone is chiselled out exactly in the middle of the ascending ramus (Velpeau, Linhardt). Thus we reach at the inner surface of the maxilla the point of entry of the nerve. This method is very exact and we are sure of striking the nerve. If healing ensues by first intention, the function of the maxilla remains unimpaired.

b. Paravicini's method. The mouth being opened wide (White's speculum), we palpate at the anterior margin of the ascending ramus of the jawbone its sharp inner edge upon which we divide the mucous membrane and periosteum down to the bone. The inner margin is sufficiently detached subperi-

osteally with a blunt instrument from the inner surface of the ascending ramus until the lingula is felt as a pointed projection at the inner circumference of the infra-maxillary canal. Behind this the nerve is sure to be found. The operation is exceedingly simple and far less serious than that from without; but it has the drawback of necessitating a wound in the mouth which possibly may be infected, while in operations from without infection can be positively prevented. The slower healing of an infected wound, and the fact that the internal ligament is attached at the lingula, may have the consequence that the opening of the mouth is for some time interfered with.

27. The *lingual nerve* can be exposed after Paravicini's intrabuccal method. The following procedure is simpler. At the point where the nerve passes forward between the anterior palatine arch and the base of the tongue it is situated very superficially under the mucous membrane. Therefore only a small longitudinal incision is needed to expose it with certainty. The opening should not be too near the tongue. The transverse division of the cheek after Roser is not a necessary preliminary. The operation has the disadvantage that a wound is made inside the oral cavity.

In order to avoid this, the attempt has been made to expose the nerve from without and below at the point where it passes above the submaxillary gland. The incision (part of our normal incision for the upper cervical triangle) at the neck simply exposes the submaxillary gland at its lower margin. The gland is turned upward and the nerve is grasped at the point where it is in connection with the submaxillary gland through the lingual ganglion. The operation is far more difficult than the former, but it has the advantage that healing by first intention is certain to be obtained. Thirdly, the nerve can be found, like the inferior alveolar nerve, by trephining of the ascending ramus of the maxilla.

28. The *auriculo-temporal nerve* (see Figs. 10 and 11) is exposed at the posterior surface of the temporal vessels under which it passes upward. A longitudinal incision from the root of the zygomatic arch upward through skin and fascia renders the thin nerve trunk accessible.

29. The *buccinator nerve* is the sensory nerve for the region

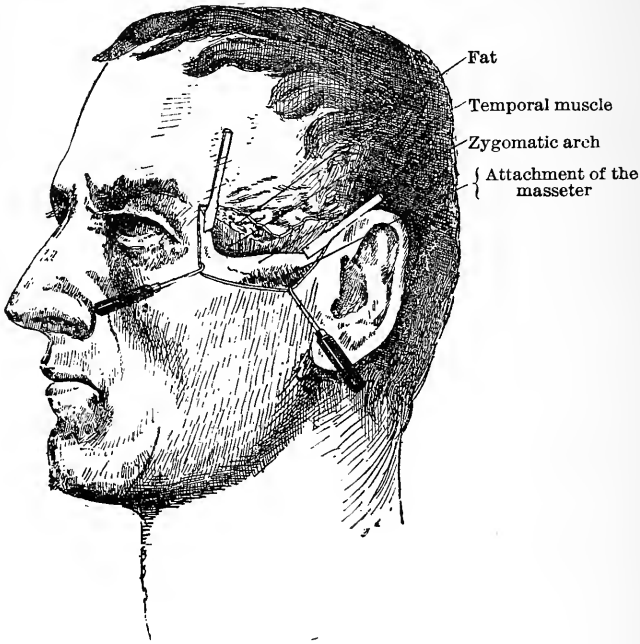

Fig. 32.

of the angle of the mouth. It lies at the inner side of the coronoid process of the lower maxilla. The nerve can be grasped at the anterior margin of the process, both in operating from without and from within. The operation from within is more simple. After opening the mouth wide, the edge at the anterior margin of the process named is felt without difficulty; we cut down upon it, dividing the mucous membrane and the fibres of the buccinator muscle. The nerve passes transversely forward upon the process.

The operation from without (Zuckerkandl) is effected by an

incision below the zygomatic arch and bone, extending forward from the anterior margin of the masseter in a horizontal direction above Steno's duct, the transverse facial artery being left intact (Fig. 22); at the anterior margin of the masseter we strike the mass of fat of the cheek; after this is pushed aside or removed, we reach the anterior margin of the coronoid process

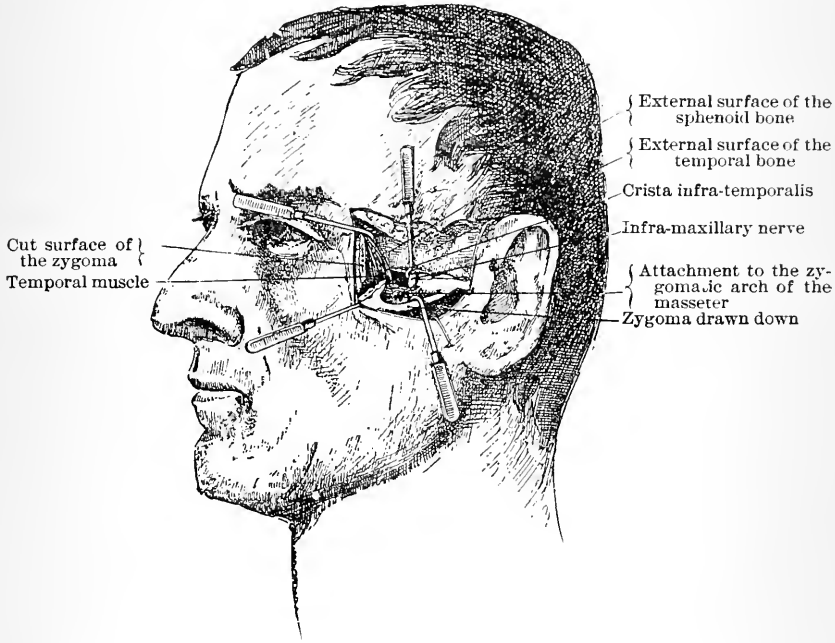

FIG. 33.

on the inner side of which the nerve passes forward upon the fibres of the buccinator muscle.

30. *Infra-Maxillary Nerve.*—All operations on the branches of the third trunk of the trigeminus are so often followed by relapses that nothing is left but to look for the third trunk of the trigeminus at the foramen ovale (Figs. 24, 25, 32, 33). This operation is most certain in its results if the zygomatic arch is resected (Lücke, Braun, Lossen, Krönlein).

We adhere to the rule that here, too, only those incisions must be made which avoid injury of the branches of the facial nerve.

The incision begins behind the frontal process of the zygoma and is carried obliquely downward as far as the posterior end of the zygomatic arch. From the posterior end of this incision another one is carried down to the bone at a right angle, rising obliquely backward in front of the ear (ligature of the temporal artery and vein). We divide the skin, some fibres of the orbicularis, and the tense temporal fascia, which is drawn down, together with the branches of the facial nerve supplying the eye and forehead. Immediately behind the ascending frontal process of the zygoma the latter is now exposed in a vertical line within and without, and chiselled through. At the posterior end of the zygomatic arch its root is likewise divided close to its origin, and the arch drawn down with a strong hook.

The outer surface of the temporal muscle, covered with fat, is now laid bare. This muscle is lifted from the skull by its posterior margin and drawn vigorously forward with a blunt hook. Only if the access gained is insufficient is the attachment of the muscle at the coronoid process divided, or else the point of this process is severed with cutting forceps when properly isolated (Krönlein). It is not a matter of special importance that the muscle be spared; but detachment diminishes the injury as compared with cutting, and gives a clearer field of operation. Then the periosteum along the crista infra-temporalis is divided from the anterior edge of the origin of the zygomatic arch at the temporal bone and all the soft parts together are lifted subperiosteally from the lower surface of the skull in a median direction. Thus we reach without further injury the outer surface of the base of the pterygoid process, and behind its sharp posterior edge the foramen ovale is distinctly palpable, about 3 cm. deeper than the temporal origin of the zygomatic arch. Occasionally there are two openings from which the nerve emerges. The large arteries, branches of the internal maxillary, remain in the soft parts which have been turned down, with the exception of the middle meningeal which

lies posteriorly. The zygomatic arch is replaced and fastened, and the resulting cicatrix is almost invisible. It is unnecessary to resect the zygoma, in addition, at its orbital plate or as far as its junction with the upper maxilla, for no more room is gained thereby for the isolation of the nerve.

31. Resection of the Upper Maxilla (see Figs. 22 and 23).—If the surgeon is to have courage enough to perform partial or total resection of the upper maxilla with the necessary thoroughness in the early beginning of malignant new-formations, that is to say, to expose the diseased part so perfectly that all suspicious tissues can be removed, he requires to be acquainted with operations which are not followed by serious disfigurement. Especially facial expression should not be injured unnecessarily. The aim, therefore, is not only to secure small cicatrices, but the facial muscles and particularly their motor nerves must be kept intact. In order to attain this, the following procedure is to be recommended. A median incision is made (see Fig. 22) which passes upward beside the filtrum from the slight depression in the upper lip into the nostril, from the nostril close around the ala nasi, along the pyriform aperture obliquely upward and in a median direction to the junction of the nasal bone with the upper maxilla as far as the height of the inner canthus or to the root of the nose. In this way only the levator alæ nasi is divided, which is of no consequence in facial expression.

Should the incision described prove insufficient to permit a good view, it may be enlarged as follows. Entering between the upper and the lower fields supplied by the facial nerve, a transverse incision is added which runs laterally and slightly downward, from the lower margin of the orbicularis oculi muscle across the attachments of the quadratus labii superioris and the zygomatic muscles (our normal upper maxillary incision below the infra-orbital margin, Fig. 22). The entire flap together with all the healthy soft parts and nerve twigs is turned

outward and the bone or the tumor laid bare. By grasping the base of the turned flap sufficient compression can be exerted and the vessels easily and safely ligated (angular, labial, and infra-orbital artery, possibly the transverse facial). Immediate, thorough arrest of hemorrhage is an eminently important factor in operating correctly. For this reason and the loss of blood in general, a preliminary ligation of the external carotid artery is to be highly recommended in resection of the upper maxilla and renders the operation much cleaner and easier.

The upper maxilla is then freed from its attachments. With the chisel or cutting forceps we divide, in extensive disease, the frontal process of the upper maxilla together with the nasal bone from the upper part of the pyriform aperture backward, passing through the lachrymal and ethmoid bones to the posterior end of the inferior orbital fissure, in the course of which no serious injuries are inflicted. For the connection of the upper maxilla with the zygoma we make the division, according to the indications, either at the point just named, or else the zygoma is removed altogether with a vigorous blow of the chisel, after dividing the zygomatic arch and the frontal process of that bone through a separate small incision. During this step the wound margins must be drawn vigorously aside with sharp hooks. There remains the third connection with the upper maxilla of the opposite side. The chisel is applied medially between the incisors, and the plate of the palate throughout its entire length is cut, after the mucous membrane and periosteum of the palate at the limit of the disease has been divided down to the bone and the soft palate, too, separated transversely from its attachments, with the knife or, better, the thermocautery.

Lastly we have the connection with the pterygoid process. If the flap is vigorously drawn back, the soft parts can be divided from without as far as this process, with the necessary control of the hemorrhage, *i.e.*, mucous membrane, buccinator,

external and internal pterygoid muscles; then the bony process is cut from without with the chisel, the flap containing the soft parts being drawn out of the way. Where this bone is not to be removed its connection with the maxilla is broken by drawing the latter strongly downward; this should be done quickly so that the bleeding may be arrested. For during this act the large terminal branches of the internal maxillary artery are torn (the spheno-palatine, pterygo-palatine, and infra-orbital arteries).

32. Less radical is the osteoplastic total resection of the upper maxilla, during which the jaw is bent out and again replaced. This operation is indicated in tumors of the base of the skull (os basilare and its neighborhood), especially in retro-maxillary tumors, when sufficient room cannot be gained by Gussenbauer's method of dividing the soft palate and chiselling out the hard palate. The difference between this and the preceding operation consists in the fact that after the cutaneous incisions the soft parts are not detached from the bone; but, the bony connections having been severed, the maxilla is bent over laterally together with the soft parts. The frontal process of the zygoma must be severed through a special oblique incision, in like manner as in the above-described method of resection of the supra-maxillary nerve at the foramen rotundum (see Fig. 30).

For exposing the retro-maxillary fossa use is made of the method of resection of the zygoma described in connection with the division of the second trunk of the trigeminus.

When only the nasal cavity, alone or with the antrum of Highmore, is to be rendered accessible, a partial osteoplastic resection of the upper maxilla (Fig. 23) suffices and is performed as follows. Cutaneous incision as for resection of the upper maxilla, except that the upper lip is not split (Fig. 28), that is to say, from the nostril around the ala nasi up to near the inner canthus and beneath the infra-orbital margin across to the zygoma.

Starting from the upper end of the pyriform aperture the parts are severed in the following order: First the connection of the nasal bone, laterally the junction of the latter and of the frontal process of the upper maxilla and that of the lachrymal bone with the frontal bone, then obliquely backward and downward the orbital plate of the cribriform bone as far as the inferior orbital fissure, by means of the bone forceps or a fine chisel. From the lowest portion of the pyriform aperture the chisel divides the median and anterior wall of the antrum to the infra-orbital canal; finally backward along the latter the orbital plate of the upper maxilla, from the horizontal cutaneous incision. Then the bones with the soft parts can be turned outward, thus exposing as a single space the nasal cavity and that of the antrum of Highmore.

We have stated in connection with the nasal operations (p. 63) how by a simple cut through the upper lip and a median incision through the hard and soft palate, the two halves of the upper maxilla can be opened and the base of the skull rendered accessible.

33. Resection of the Lower Maxilla.—This operation is a simple one, but even here unnecessary disfigurement due to lesion of the oral branch of the facial, especially its marginal ramus, should be avoided.

As the simplest may be recommended the median incision (Fig. 23), which divides the lower lip and eventually extends to the middle of the hyoid bone. This incision alone gives ample room in disease of the middle portion and a large part of the horizontal rami of the lower maxilla. In disease affecting the region of the angle of the jaw and the ascending ramus, and when it is necessary to expose and clear the submandibular fossa of malignant new-formations, a lateral incision is added. This should not be placed, as is often done, at the margin of the maxilla, on account of the branches of the facial passing there; but it should be carried from the hyoid bone, extending back-

ward and upward in the fold between the floor of the mouth and the neck, the width of the thumb behind and below the angle of the jaw, if necessary as far as the tip of the mastoid process (compare our normal incision for the upper cervical triangle, Fig. 29). The flap limited by these incisions is turned up and fastened to the skin of the face with sutures. Withal the surgeon must keep as close as possible to the bone, and detach the muscles with the flap (anteriorly the mental, triangularis and quadrangularis mentis muscles, posteriorly the buccinator and masseter). On the inner surface of the maxilla the muscles detached are, anteriorly the digastric, genio-hyoid, mylo-hyoid, and genio-glossus, posteriorly the internal pterygoid.

Before the muscles are detached it is proper to saw through the maxilla in front so that it can be vigorously drawn forward and the soft parts rendered tense. After the muscles and the mucosa are divided the maxilla is drawn down so that the coronoid process may be seen and felt. Its point is removed with cutting forceps and thus the attachment of the temporal muscle severed. The head and neck of the maxilla are not freed with sharp instruments, lest the internal maxillary artery be injured; but after all the other connections have been divided the head is simply twisted out and the joint capsule and the external pterygoid muscle are torn by torsion. The external maxillary artery has been severed and tied during the turning over of the flap composed of soft parts. When the horizontal portion of the maxilla is sawn through, the inferior alveolar artery is lacerated in the infra-maxillary canal and tamponed with a plug of wax; should one-half of the maxilla be totally removed, the artery is ligated in the posterior upper angle of the wound, either before or after the maxilla is twisted off or while the internal pterygoid is detached.

The inferior alveolar nerve is torn or else it is divided when the internal pterygoid muscle is detached.

In this operation, as in resection of the upper maxilla, it is advisable, as soon as the cutaneous incision has been made, to ligate the external carotid artery above the superior thyroid or possibly above the point where the lingual artery branches off.

34. *Osteoplastic resection of the lower maxilla* is an important preliminary operation for exposing the floor of the mouth, the root of the tongue, the isthmus of the fauces, and the tissues in the lower pharynx. Satisfactory access is gained to the tissues situated in front of the isthmus of the fauces by the median division of the lip and the lower maxilla. This operation has the great advantage that, if exactly sutured with iron wire, the movements of the lower jaw are not even temporarily hampered to any notable extent, and the fragments knit readily if well coaptated.

For cases requiring division of the maxilla in disease around the isthmus of the fauces and in the pharyngeal tissues situated behind it, the normal procedure is division of the maxilla in front of the ascending ramus. The incision is like that for resection of the lower maxilla, in a line from the mastoid process toward the hyoid bone, the length being adapted to the requirements. After ligature of the internal maxillary artery at the anterior circumference of the masseter the lower margin of the maxilla is exposed; the periosteum is detached forward and backward, the mucous membrane is torn with the elevator, and the bone is divided with the fret-saw behind the molars.

Before this last step it is proper to make one or two drill openings for the subsequent suture with iron wire. The saw should move obliquely so that the external lower side is farther forward than the inner and upper, for the posterior end of the maxilla tends to be displaced medially and upward. The ascending ramus is now turned upward with a sharp hook, and the anterior portion of the maxilla is drawn forward.

35. The oral and pharyngeal organs can also be made accessible without osteoplastic resection of the lower maxilla. An

excellent method is the transverse incision of the cheek recommended by Roser for exposure of the lingual nerve (see Fig. 22). This incision extends from the angle of the mouth transversely backward, parallel to the branches of the facial nerve, as far as the prominence of the masseter, all the soft parts being divided (skin, orbicularis oris and buccinator muscles, and mucous membrane). Of course this incision leaves a cicatrix with subsequent retraction, but the resulting disfigurement is unimportant, since the expression is in no way restricted, thanks to the preservation of all the branches of the facial. Steno's duct and the transverse facial artery remain above the incision, but the external maxillary artery is cut and requires double ligature.

36. *Incisions in the Tongue and the Floor of the Mouth.*—These should not be made except after thorough opening of the mouth with proper specula (White's), the tongue being drawn forward with a loop of thread introduced deeply through its sagittal median line. Thorough opening of the mouth presupposes profound anæsthesia, especially if the motion of the jaw is restricted by inflammation or other painful infiltration of the soft parts between the upper and lower maxilla or in the region of the latter. Incisions can be made on the dorsum of the tongue without fear of injuring the larger vessels and nerve trunks. The median line is to be preferred, as here the damage is least.

Laterally and on the floor of the mouth are large vessels (the lingual and sublingual arteries and veins), nerve trunks (hypoglossus, lingual, and behind the glosso-pharyngeus), and the efferent ducts of the salivary glands (Wharton's and Rivinus'). The closer the incision is kept to the maxilla the more certainly are these structures avoided. Near the lateral margin of the tongue, under the prominence of the lingual muscle and on the outer side of the genio-glossus muscle, the lingual artery and nerve can be exposed. Posteriorly the artery is covered by the fibres of the hyo-glossus muscle. Toward the tip of the tongue the vessels approach the lower surface. Where profuse

hemorrhage is to be feared from incisions about the tongue a prophylactic ligature of the lingual artery is to be recommended.

G. The Upper Lateral Cervical Triangle.[1]

The Normal Incision for the Upper Cervical Triangle.

In accordance with our principle to place cutaneous incisions in the direction in which the skin splits naturally, we recommend for the exposure of the organs in the infra- and retromandibular fossa an incision (Fig. 29) already indicated for resection of the maxilla; namely, passing from the anterior end of the tip of the mastoid process to the middle of the hyoid bone, extending a finger's breadth below and behind the angle of the jaw, and intersecting at this point the anterior margin of the sterno-cleido-mastoid muscle. This incision has the great advantage that it lies on the border line where the muscles coming from above and below meet or end, in so far as they concern the organs within the neck: above, the digastric, stylohyoid, genio-hyoid, and mylo-hyoid; below, the sterno-hyoid, thyreo-hyoid, and omo-hyoid. The muscles crossing this border line are either unimportant as the platysma, or they remain at the side or behind as the sterno-cleido-mastoid and the muscles of the vertebral column.

Moreover, this incision enables us to avoid the important nerves in so far as their main trunks lie either above or behind or can be drawn aside, while their branches running up and down radiate from the direction of the incision. Thus the vagus and sympathetic lie posteriorly with the sterno-cleido-mastoid muscle, together with the spinal accessory and the descending ramus of the hypoglossal. The inferior branch of the facial, the hypoglossal, the lingual, and the glosso-pharyngeus

[1] For practical reasons we limit it above by the margin of the lower maxilla, inward by the median line as far as the upper margin of the thyroid cartilage, and backward by the anterior margin of the sterno-cleido-mastoid muscle.

are above; the superior laryngeal branch of the vagus is drawn down.

In the third place the incision strikes the points where the branching of the large vessels of the neck begins and, in the main, terminates. At the level of the upper margin of the thyroid cartilage the common carotid divides and immediately above are given off the branches of the external carotid in close proximity. At the same level the anterior and posterior facial veins join the common facial vein, and the latter the common jugular vein. Hence from the normal incision the great number of branches and even the trunks of the larger vessels of the neck can be ligated.

For this reason we designate this incision the normal one for the upper cervical triangle, and all the longer and shorter incisions here required coincide with it.

37. *External and Internal Carotids* (Figs. 10 and 11).—The point of our normal incision at which we feel the pulsation of the artery and ligate it lies at the anterior margin of the sterno-cleido-mastoid muscle. The margin of this muscle ascends much more vertically than it is usually represented; the fascia draws it forward toward the angle of the jaw. The point for our ligature, therefore, lies a finger's breadth vertically under the angle of the jaw. Here the artery ascends vertically from below. For its exposure we employ a corresponding portion of our normal incision, forward and backward of the point mentioned. After the skin the platysma is divided, which often forms quite an extensive muscular layer. Its fibres pass upward and forward over the margin of the maxilla. In the posterior portion of the incision the external jugular vein which passes up exactly over the sterno-cleido-mastoid muscle is not divided but drawn back with the large auricular nerve that runs behind it. By dividing the fascia the anterior margin of the sterno-cleido-mastoid muscle is exposed, and then appears the common facial vein as far as its termination in the common

jugular vein. The former descends over the digastric muscle. These veins have to be drawn forward and downward; their smaller branches must be ligated. We now strike the external and internal carotid arteries, the latter lying at its origin posteriorly and somewhat more superficially, which fact is apt to lead to error. The internal carotid gives off no branches, while

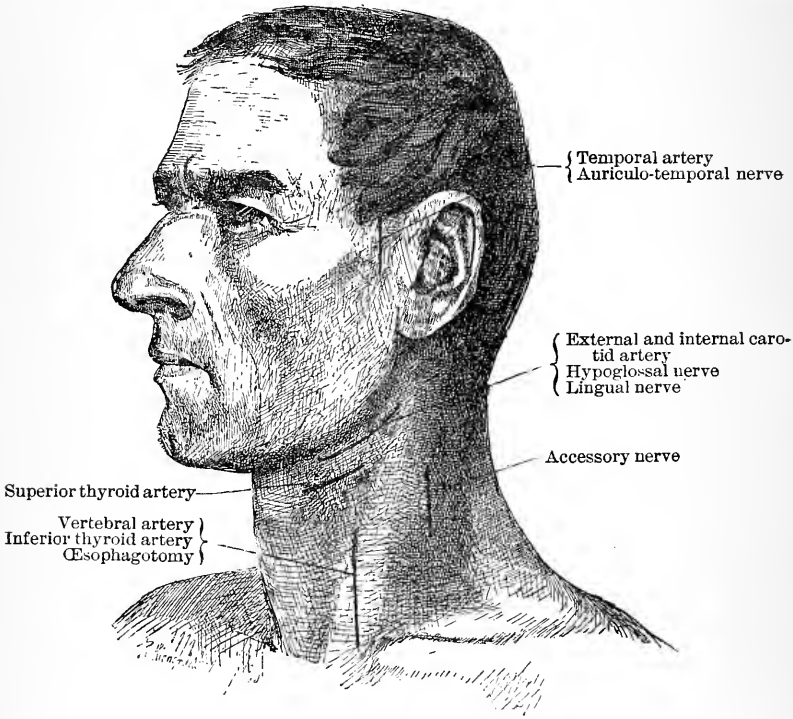

Fig. 34 A.

the external is characterized by a branch, the superior thyroid artery, immediately above its origin. Hence the vessels cannot be mistaken for each other. Moreover, the external carotid, at the point where the external maxillary artery is given off, is surrounded from behind and without by the hypoglossal nerve. The small cleido-mastoid artery bends backward over the nerve. Ligature of the external carotid is not easy, since its guiding-points consist only of soft parts (anterior margin of the sterno-

cleido-mastoid) which may be displaced with every incision. In exposing the artery we must preserve the descending hypoglossal branch which supplies the muscles of the sternum and larynx.

Through the same incision we can ligate a large number of the branches of the external carotid at their origin, as the

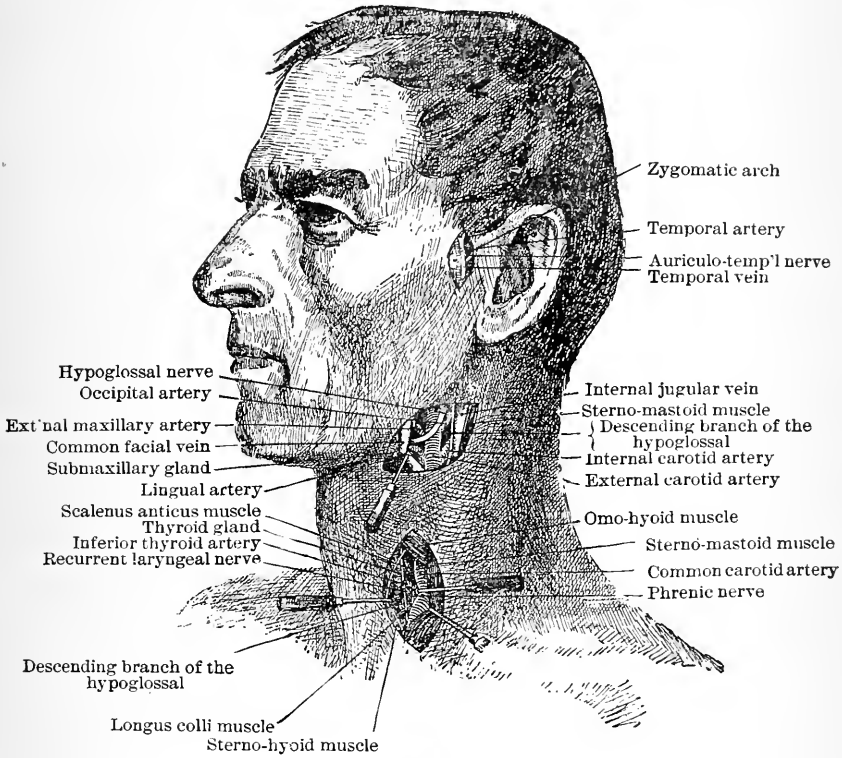

FIG. 34 B.

superior thyroid, the lingual, the external maxillary, and the occipital artery. The course of these four main branches is sufficiently characterized by their direction, downward, forward, upward, and backward, respectively. For the peripheral ligature of these vessels there are more accessible and more reliable points.

38. *Superior Thyroid Artery* (Fig. 10) —The ligature of the superior thyroid artery is effected at the tip of the upper cornu

of the thyroid gland. The incision chosen is that portion of our normal incision which passes from the anterior margin of the sterno-cleido-mastoid muscle to the body of the hyoid bone. The lower edge of the skin wound is drawn vigorously downward. Where the superior cornu of the thyroid gland does not rise so high, it is better to make the transverse incision 3 cm. deeper, corresponding to the upper margin of the thyroid cartilage. The anterior branch of the superior thyroid artery, in cases of enlargement of the gland for which alone this ligature comes in question, can always be felt on the median anterior side of the superior cornu, passing downward along the larynx. By following this branch beyond the tip of the upper cornu the trunk of the artery is sure to be found.

39. *Lingual Artery* (Fig. 35).—Ligature of the lingual artery is of importance because it supplies a more deeply seated organ in which the arrest of hemorrhage is not always easy. Hence prophylactic ligature is often desirable. The course of the lingual artery is well marked, for it passes toward the hyoid bone, with the posterior end of whose large cornu it comes in close proximity.

This point is best for ligation because in most persons the end of the large cornu of the hyoid bone can be felt through the skin and thus furnishes a definite guiding-point for incisions. We open in the direction of our normal incision from the margin of the sterno-cleido-mastoid muscle along the large cornu of the hyoid bone as far as the body of this bone. The incision divides the skin, platysma, and fascia as if the large cornu of the hyoid bone alone were to be laid bare. When this is done the cornu is seized with a hook and the bone drawn upward; thereby we secure the great advantage that the entire field of operation is made more superficial. At the thickened posterior end of the cornu the fibres of the hyo-glossus muscle ascend vertically in a characteristic manner. Care is required so that close above the club-shaped end of the cornu no more and no

less is divided than these muscular fibres. Then the artery appears immediately above that extremity. This mode of ligature we believe to be the most reliable.

A second method recommended for this ligature is that over the digastric muscle. The incision is made parallel to the large cornu of the hyoid bone; extends through skin, platysma, and

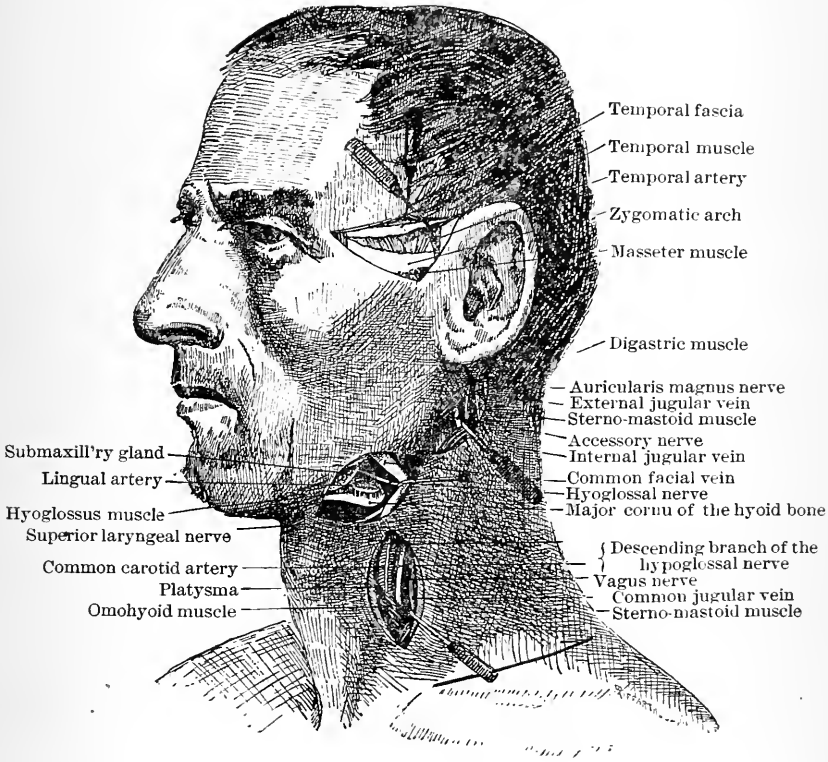

FIG. 35.

fascia; and the lower margin of the submaxillary salivary gland with the anterior facial vein is drawn forward. In the angle formed by the upper margin of the digastric and the stylo-hyoid muscles with the posterior margin of the mylo-hyoid, the artery lies under the ascending fibres of the hyo-glossus muscle. On the external surface of this latter muscle lies the hypoglossal nerve and often one of the lingual veins.

All hemorrhages about the head, excepting those which are intracranial and within the orbit, can be arrested by ligation of the external carotid, which is a reliable and safe operation. The common carotid should never be ligated in place of the external, because it is impossible to foresee whether a permanent disturbance of the cerebral circulation (especially in persons of advanced age) will not ensue in consequence thereof.

40. In the case of intracranial hemorrhages ligation of the internal carotid (Fig. 11) is to be preferred to that of the common carotid because the collateral circulation from the angular artery into the branches of the ophthalmic artery is preserved. The ligation equals that of the external carotid, but upward between both vessels pass the stylo-glossus and stylo-pharyngeus, and the deep fascia with the stylo-maxillary ligament.

During pharyngeal operations in which profuse hemorrhages may suddenly occur, and occasionally even during tonsillotomies, it is important to be certain as to whether a hemorrhage comes from the internal carotid or from branches of the external carotid (pharyngeal and tonsillary artery). In tonsillotomy injury to the internal carotid is not the one to be most feared, although the artery is felt pulsating behind the gland; for in the region of the tonsil the artery is separated from the pharyngeal wall by the stylo-glossus and stylo-pharyngeal muscles. But injury may be inflicted on the pharyngeal artery and the ascending palatine with its tonsillary branch (Zuckerkandl).

41. The exposure of the hypoglossal nerve coincides with that of the external carotid artery which it surrounds from without, and in its anterior portion it coincides with that of the lingual artery. But the nerve lies on the external surface of the hyo-glossus muscle, the artery on its internal surface.

42. If the submaxillary salivary gland is turned out, the posterior fibres of the mylo-hyoid muscle are incised, and we work upward along the outer surface of the hyo-glossus muscle toward the mucosa of the floor of the mouth, it is possible to

expose the lingual nerve, though it lies very deep, from the neck through our normal incision (Fig. 10).

43. *Superior Laryngeal Nerve* (Fig. 35).—This branch of the vagus, which furnishes the main sensory supply of the larynx, is rendered visible at the lower edge of the skin when the hyoid portion of our normal incision is drawn down. It passes forward in the depth behind the external carotid (where the external maxillary artery is given off), parallel to the large cornu of the hyoid bone, above the pharyngo-laryngeal muscle on the outer surface of the hyo-thyroid membrane, and disappears under the posterior margin of the thyro-hyoid muscle. It is exceedingly important to bear the course of this nerve in mind, for its injury causes insensibility of the larynx, and where this follows operations on the pharynx and mouth the patients are very liable to die of foreign-body pneumonia.

44. *Ligation of the Internal and Common Jugular Vein* (Figs. 11 and 35).—This operation is the same as that for ligation of the external and common carotid. The vessel lies on the outer side of the internal carotid. Aside from hemorrhages, the ligation is of special importance in infectious thrombosis in the afferent region of the vein. For instance, when an otitis media and mastoidea extends to the bone, thrombi may form in the transverse sinus. When such thrombi break up, embolic pyæmia ensues. Ligation of the internal or common jugular vein is to prevent this.

45. The spinal accessory nerve (Figs. 10 and 35) passes downward dorsad of the large vessels, giving off branches to the sterno-cleido-mastoid and trapezius muscles. In spasm of these muscles stretching of this nerve is indicated. Its preservation in operations about the upper end of the sterno-cleido-mastoid is still more important, especially during the excision of glands frequently performed at this point. For exposing the nerve we use the mastoid portion of our normal incision, and after the external jugular vein and the large auricular nerve have been

lifted off, the muscle is drawn back. The course of the nerve is well marked: from the distinctly palpable anterior circumference of the transverse process of the atlas it runs obliquely downward and backward under the anterior margin of the sterno-cleido-mastoid muscle. The occipital artery passes backward over it. Above, the nerve is covered by the digastric muscle. In front the sterno-cleido-mastoid artery (from the external carotid) runs parallel to the nerve.

46. *Lateral Pharyngotomy.*—The above-described normal incision forms the foundation for all operations intended to lay bare from without the lateral pharyngeal region with the tonsil and the base of the tongue.

The incision for the lateral opening of the pharynx, which permits full inspection of the lateral margin of the tongue as far as the epiglottis, and the lateral pharyngeal wall with the entire retro-pharyngeal space, corresponds to our complete normal incision for the upper cervical triangle (Fig. 24). The large auricular nerve and the external jugular vein must occasionally be severed if the posterior portion of the incision is to be made fully accessible.

After dividing the skin, platysma, and fascia the infra-mandibular region is exposed; but further progress toward the floor of the mouth and the pharyngeal wall is interfered with by the vessels which pass from below toward the outer surface of the maxilla. These hindrances are: the anterior facial vein on the external surface of the posterior belly of the digastric, the external maxillary artery under the maxillary gland, and finally the latter gland itself. The vessels named must be doubly ligated and cut; the submaxillary gland is lifted out and turned upward or extirpated. It may be useful to ligate also the lingual, pharyngeal, and palatine arteries at their origin, or else to ligate the external carotid. This will make it possible to draw the large cervical vessels with the vagus and spinal accessory nerves backward, and the arch of the hypoglossal nerve up-

ward. The superior laryngeal nerve and the superior thyroid artery remain under the lower wound margin. We must save all we can of the presenting muscles in the interest of the mechanism of deglutition, and therefore proceed along the internal surface of the maxilla and the internal pterygoid muscle toward the mucous membrane. If adhesions or the limitation of the field force us to divide the muscles, we must do so in a way to preserve the innervation of the intact muscles. For instance, the posterior belly of the digastric and stylo-hyoid are severed as close as possible to the hyoid bone, being supplied from behind (through the facial nerve); the stylo-glossus, for the same reason, is cut near the tongue so as to preserve the lingual and glosso-pharyngeal nerves which adjoin it. The stylo-pharyngeus is divided near its attachment to the pharynx; the hyo-glossus and myo-hyoid (supplied from above through the hypoglossal nerve), at their attachment to the hyoid bone, so far as may be necessary. Now the pharyngeal wall is exposed, limited above by the cephalo-pharyngeal, below by the laryngo-pharyngeal muscle. Of course, adhesions would necessitate cutting the lingual and glosso-pharyngeal nerves.

The upper part of the pharynx, however, can only be rendered completely accessible to the eye by adding the above-mentioned osteoplastic resection of the lower maxilla; or, to express it more correctly, the oblique division of the maxilla in a direction from behind inward and above, to in front outward and below, at the anterior margin of the masseter muscle; after which the ascending ramus of the jaw is vigorously drawn upward and the horizontal ramus forward.

Should the new-formation in the tongue and pharynx have extended to the transition fold between the upper and lower maxilla, it will be best to saw through the jawbone at the above-named point, if necessary detach the soft parts (the masseter externally, the internal pterygoid internally) from the bone by twisting the joint capsule and the external pterygoid

muscle, and to exarticulate and remove the ascending ramus of the maxilla. This will most certainly prevent subsequent ankylosis of the jaw. In this operation as in the above-described resection the inferior alveolar nerve and artery are cut and the latter ligated.

If the lowest part of the pharynx behind the larynx is to be exposed, the muscles of the tongue and pharynx with their nerves remain intact, as well as the branches of the external carotid. The pharynx is opened below the superior laryngeal nerve, between the latter and the superior thyroid artery (which may have to be cut), the incision reaching from the larynx upward to the point where the descending ramus of the hypoglossal nerve is given off, at the anterior margin of the carotid. In order to expose the lowest part of the pharynx it is often necessary to add to the normal incision (which is then to be shortened behind correspondingly) a longitudinal incision downward along the anterior margin of the sterno-cleido-mastoid muscle (Fig. 22).

47. *Median or Subhyoid Pharyngotomy* (Fig. 36).—To expose the entrance of the larynx when disease is limited to this region it is best to proceed from in front. Transverse incision upon the body of the hyoid bone and the anterior portion of the large cornu of this bone, extending from one side to the other through the skin and muscular fibres of the platysma, thus exposing the hyoid bone. Vertical connections of the subcutaneous veins are ligated. The hyoid artery and vein run upon the bone of the same name and must likewise be ligated. The incision divides the attachments of the muscles to the hyoid bone as far as necessary, at first the sterno-hyoid and omo-hyoid and laterally the thyro-hyoids. It is desirable to preserve some of the fibres of these muscles. The hyo-thyroid membrane is now laid bare. After dividing it we work up under the hyoid bone in order to open the mucous membrane between the base of the tongue and the epiglottis. We object to making the

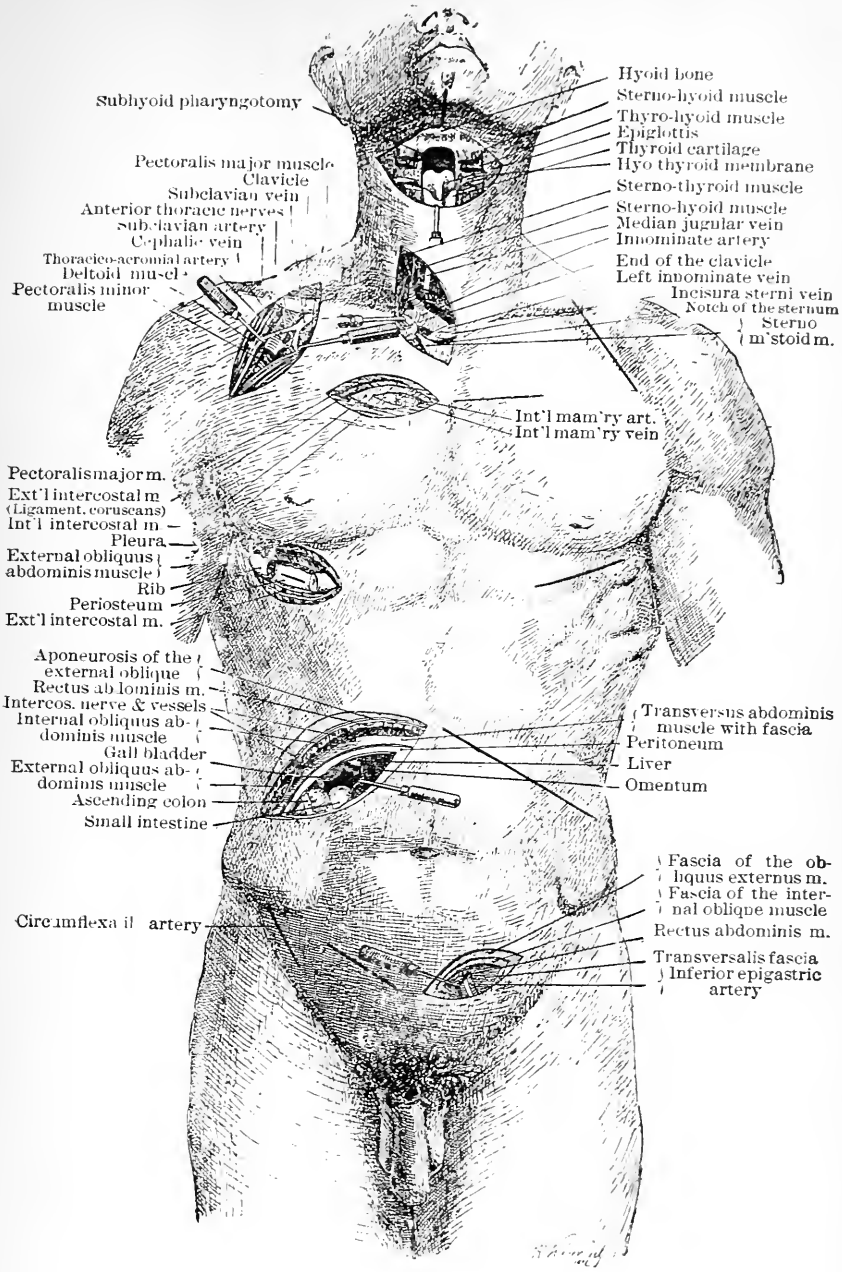
Subhyoid pharyngotomy
Hyoid bone
Sterno-hyoid muscle
Thyro-hyoid muscle
Epiglottis
Thyroid cartilage
Hyo thyroid membrane
Sterno-thyroid muscle
Sterno-hyoid muscle
Median jugular vein
Innominate artery
End of the clavicle
Left innominate vein
Incisura sterni vein
Notch of the sternum
Sterno m'stoid m.
Pectoralis major muscle
Clavicle
Subclavian vein
Anterior thoracic nerves
Subclavian artery
Cephalic vein
Thoracico-acromial artery
Deltoid muscle
Pectoralis minor muscle
Int'l mam'ry art.
Int'l mam'ry vein
Pectoralis major m.
Ext'l intercostal m
(Ligament. coruscans)
Int'l intercostal m
Pleura
External obliquus abdominis muscle
Rib
Periosteum
Ext'l intercostal m.
Aponeurosis of the external oblique
Rectus abdominis m.
Intercos. nerve & vessels
Internal obliquus abdominis muscle
Gall bladder
External obliquus abdominis muscle
Ascending colon
Small intestine
Transversus abdominis muscle with fascia
Peritoneum
Liver
Omentum
Fascia of the obliquus externus m.
Fascia of the internal oblique muscle
Rectus abdominis m.
Transversalis fascia
Inferior epigastric artery
Circumflexa il artery

FIG. 36.

division away from the hyoid bone, owing to the course of the superior laryngeal nerve which, piercing the thyro-hyoid membrane, enters the larynx. If its branches are cut the larynx is rendered insensitive and this gives rise to the entrance of food particles, mucus, and wound secretions into the larynx. Such substances are not removed by reflex cough and dangerous foreign-body pneumonia is the result.

The epiglottis can now be seized with a sharp hook and drawn forward, thus affording a very good view of the entrance of the larynx, especially the region of the arytenoid cartilages which is subject to many diseases (tuberculosis, cancer). In order to permit undisturbed operation we must, as in laryngotomies, reduce the irritability of the mucous membrane by painting it with a ten-per-cent cocaine solution.

The described operation, which was introduced by von Langenbeck, is to be highly recommended for the entrance of the larynx and especially the septum between the latter and the pharynx, since it is not followed by incidental functional disturbances.

In the after-treatment of the wound made by pharyngotomy we must bear in mind that we have to deal with tissues infected *ab initio*, for the pharynx cannot be completely disinfected. For this reason it is advisable, in the case of ulcerations and ulcerated tumors, to make the resection in two steps: first the dissection as far as the pharynx, then the wound is allowed to granulate by filling it with aseptic gauze and keeping it well open. Not until three or four days later is the pharynx opened and the tumor or ulcer removed, best with the thermo-cautery. Where operation in two steps is not feasible and the whole must be performed in one sitting, the main thing is an open antiseptic wound treatment, *i.e.*, the wound is filled with carbolic gauze, each time freshly prepared by immersion in five-per-cent carbolic solution and expression. The gauze is changed every two hours, when necrotic points are painted with tincture of iodine,

or powdered iodoform or bismuth is rubbed into them. Should the effect of the carbolic acid be too strong, thymol gauze tampons are substituted. These must likewise be each time freshly prepared by immersion in 0.1-per-cent thymol solution and expression.

It is self-evident that under favorable conditions—that is, when the wound is small and an exact suture can be applied—the attempt at healing by first intention may occasionally be justified in pharyngotomy, the wound surface in the pharynx having been thoroughly dusted with iodoform. Every tamponade of the pharynx and the entrance of the larynx presupposes a tracheotomy which is indicated even for the sake of securing a quiet operation; it had best precede the main operation by several days.

H. The Anterior Cervical Triangle.[1]

If we are to enter deeply between the contents of the neck and the sterno-cleido-mastoid muscle, transverse incisions corresponding to the cleavage lines of the skin do not always suffice, and we are often forced to make longitudinal incisions, either median or lateral along the sterno-cleido-mastoid muscle.

48. *Common Carotid Artery* (Figs. 24 and 25).—The common carotid ascends vertically in the shortest direction from the chest to the head. The incision exposing it, therefore, lies vertically and crosses the anterior margin of the sterno-cleido-mastoid muscle or the line corresponding to it from the angle of the jaw to the sterno-clavicular articulation. The artery can also be exposed very readily by a transverse incision, whose centre corresponds to the anterior margin of the sterno-cleido-mastoid, made at the height of the cricoid cartilage. This incision, corresponding to the cleavage line of the skin, leaves

[1] The limits of this triangle are the upper margin of the thyroid cartilage and the anterior margins of the sterno cleido-mastoid muscles as far as the jugulum.

a better cicatrix. The artery can be felt throughout the entire neck alongside of the trachea and œsophagus and may be compressed with certainty against the vertebral column, best at the height of the cricoid cartilage. By its side we feel the markedly projecting transverse process of the sixth cervical vertebra, the so-called tuberculum caroticum. Now and then compression of the carotid will incidentally cause pressure symptoms on the part of the vagus nerve, slowing of the pulse, and dyspnœa to a feeling of syncope. The preferred point for ligating the artery is likewise at the height of the cricoid cartilage. This cartilage can nearly always be distinctly felt. After dividing the skin and platysma, the transverse subcutaneous colli nerve appears, passing forward over the sterno-cleido-mastoid muscle from its posterior margin. It is cut (preserved in the transverse incision) and the fascia divided so that the body of the sterno-cleido muscle is laid bare. Its anterior margin is drawn outward with a blunt hook. Under this margin the omo-hyoid muscle is seen passing upward and somewhat medially. The artery is approached through the angle, open above, between the two muscles named. The vessel is still covered by the second fascia which forms its sheath at the same time. After this is divided the artery is exposed. The descending branch of the hypoglossal, the motor nerve for the muscles rising to the larynx, passes down on the sheath of the vessel. The nerve is carefully drawn to the median side. The greatest caution is required lest the vagus nerve, which lies close to the posterior surface of the artery, be included in the ligature. The common jugular vein lies outward and the sympathetic backward of the artery.

49. *Ligation of the Common Jugular Vein* (Figs. 24 and 25). —At the same point the common jugular vein can be ligated. It lies on the antero-lateral side of the common carotid artery. The ligation is indicated, aside from hemorrhages, when thromboses have formed in the afferent field, especially in the transverse sinus by extension of infectious inflammations from the

ear. The vein is very frequently ligated when it is adherent to tumors such as malignant struma, carcinoma and sarcoma of lymphatic glands.

50. At the same point and for the last-named reasons resection of the vagus nerve (Fig. 25) may become necessary. Unilateral division of this nerve can be performed without danger to life, even without any disturbance of the patient.

51. *Ligation of the Inferior Thyroid and the Vertebral Artery* (see Figs. 37 and 38).—Ligation of these two large branches of the subclavian artery is properly performed from the same vertical incision which was described for the common carotid, laterally from the cervical structures in the anterior cervical triangle, crossing the margin of the sterno-cleido muscle, but prolonged as far as the clavicle.

We have often ligated the thyroid artery for struma vasculosa in recent years, since Wölfler has recommended the operation for struma in general. A well-marked point for exposing the vessel is where it changes its upward direction to a median, toward the posterior surface of the thyroid gland. Here the horizontal artery lies on the median side of the common carotid, resting on the spinal column or the longus colli muscle. The operation resembles that for exposing the common carotid at the lower part of the neck. The skin and platysma are divided, the anterior margin of the sterno-cleido-mastoid muscle is laid bare and drawn vigorously outward; if more room is needed it is incised. The common jugular vein and the carotid with the vagus are drawn outward. At the inner side of the bundle of vessels, between this and the margin of the thyroid gland or the muscles covering it, the sterno-hyoid and sterno-thyroid, we proceed toward the spinal column. Here the pulsation of the artery is felt. The thyroid gland must be drawn in a median direction and lifted up. The artery is characterized by a curve whose convexity is upward and outward, for the ascending vessel turns in a median direction to the point where the thyroid

gland and trachea join. The thyreo-cervical artery gives off, besides the thyroid artery, the ascending cervical and the superficial cervical. The operation must be performed under careful control and thorough arrest of hemorrhage, so as to enable us, on the one hand, to preserve the inferior laryngeal nerve where it crosses the artery; for that nerve furnishes the chief motor

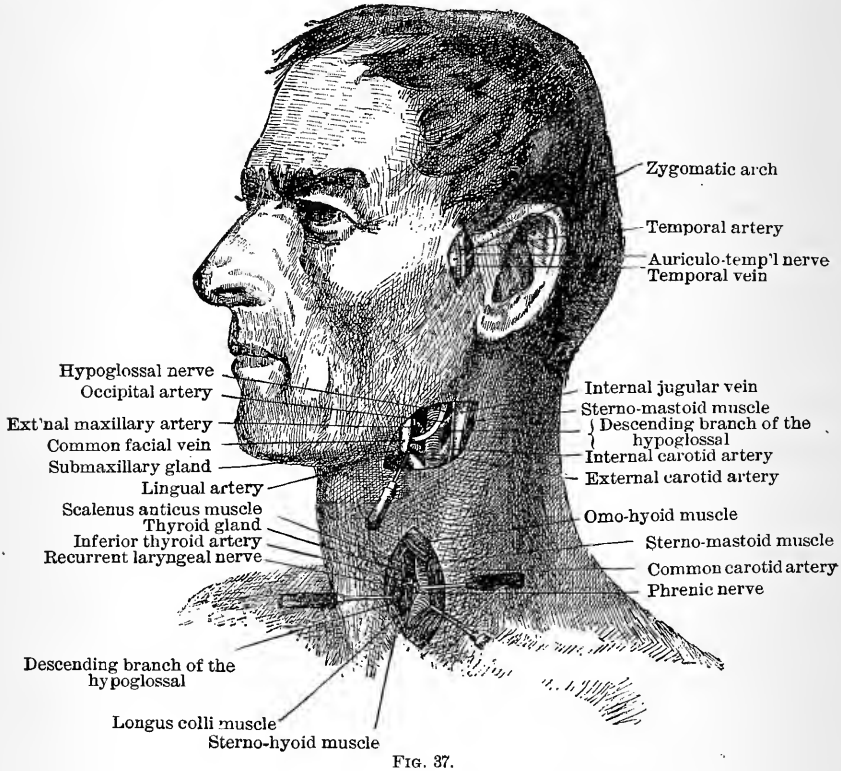

FIG. 37.

supply of the larynx. On the other hand we must guard against lesion of the cardiac branches of the sympathetic or division of the trunk of the sympathetic which occasionally surrounds the artery with an anterior and posterior branch. When the thyroid gland is enlarged the capsule must be divided and the gland drawn in a median direction with a blunt hook. At the same time the inferior accessory thyroid vein should be doubly ligated and cut.

52. *Vertebral Artery* (Fig. 38.)—Ligation is effected in an analogous manner to that for the inferior thyroid; it is more difficult because the artery lies still deeper. Its course is not only upon but within the deep cervical muscles, under the prevertebral fascia. The main guiding point for the artery is the so-called tuberculum caroticum at the transverse process of the sixth cervical vertebra, the most prominent portion of the antero-lateral surface of the cervical spinal column. This tubercle is also used in ligation of the carotid, whence the name. It is not of much importance in ligation of the carotid, but is undoubtedly so for ligation of the vertebral artery which here enters the transverse foramen. It would be more appropriate, therefore, to name this prominence the vertebral tubercle. The artery ascends toward the lower surface of this tubercle. After the sterno-cleido muscle with the large cervical vessels has been drawn outward, and the sterno-hyoid and sterno-thyroid inward, the prevertebral fascia is divided above the curve of the inferior thyroid artery; then the vertically ascending artery, which disappears above under the vertebral tubercle, is felt upon and partly within the fibres of the longus colli muscle. In a lateral direction lies the scalenus anticus muscle and upon it the phrenic nerve. The latter passes from the outer margin of the muscle over its anterior surface and enters the upper thoracic aperture.

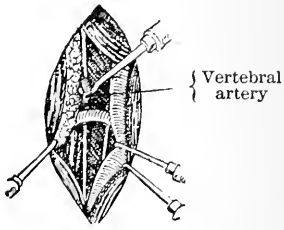

FIG. 38.[1]

53. *Œsophagotomy* (Fig. 10).—The œsophagus is opened in the anterior cervical triangle from the left side, where it projects beyond the trachea. If it is to be exposed on account of a new-formation or a foreign body, the incision is made exactly like that for ligation of the common carotid and the inferior

[1] This figure represents the incision for the inferior thyroid artery shown in Fig. 37, but on a larger scale.

thyroid artery, but it should be longer. After withdrawal of the sterno-cleido muscle and the large cervical vessels the inferior thyroid artery must be doubly ligated, and the thyroid gland lifted in a median direction together with the sterno-hyoid and sterno-thyroid muscles covering it. The capsule of the gland, forming a part of the deep fascia which adheres laterally to the sheath of the large cervical vessels, must be divided. The œsophagus becomes accessible only after dividing the deep fascia. Great care is to be taken to preserve the recurrent laryngeal nerve which runs upward in a groove between the trachea and œsophagus; for this reason the œsophagus must be opened quite laterally or latero-posteriorly. Its opening is more difficult when the tube is collapsed, hence the œsophagus is first dilated by the introduction of a sound or olive-tipped bougie.

54. *Retro-œsophageal Space.*—The same operation gives access to retro-pharyngeal and retro-œsophageal abscesses. These abscesses, which are largely due to tubercular disease of the vertebral column and the glands, may endanger life not only by closing the entrance of the larynx, but by their rupture causing sudden suffocation. Opening them from without instead of from within has the advantage that no communication is established with the lumen of the pharynx and œsophagus, thus permitting a relatively aseptic course.

Laryngotomy and Tracheotomy.—Median incisions in the anterior cervical triangle are among the most frequent operations the surgeon is called upon to perform for the opening of the larnyx and trachea.

55. *Tracheotomy* (Fig. 39.)—In the great majority of cases in which we are forced to perform this operation very rapidly, crico-tracheotomy is the safest and least bloody.

The upper tracheal rings are covered by the isthmus of the thyroid gland, which is often rather thick. At its upper and lower margin the communicating veins run as stout transverse branches between the thyroid veins. Twigs are given off by

them and the anterior branch of the superior thyroid artery to the pyramidal process when present, so that even arterial vessels may cross the middle line at the upper end of the isthmus. At the posterior surface of the isthmus runs an inferior laryngeal branch from the inferior thyroid artery below, and beneath the isthmus we constantly find the thick inferior venæ thyreoideæ

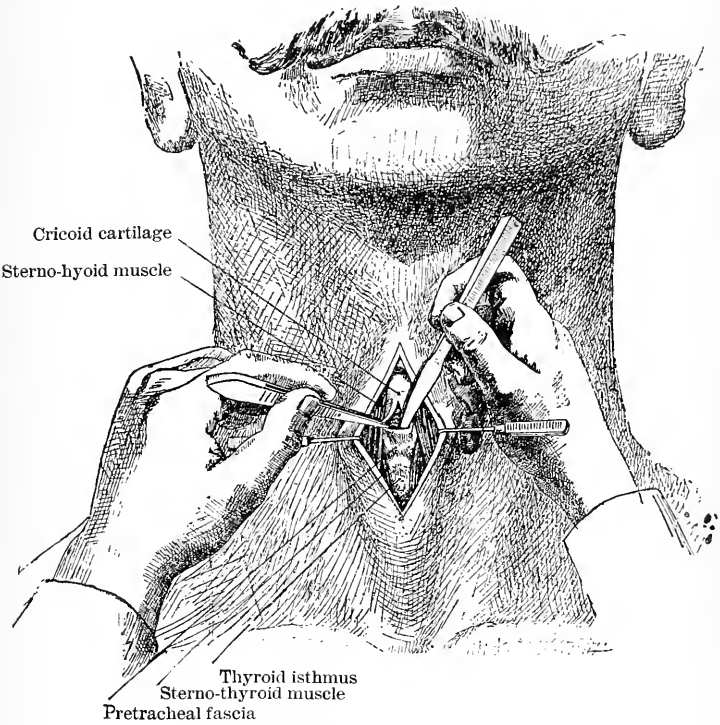

FIG. 39.—Tracheotomy, Bose's Method.

rising vertically on both sides of the median line; occasionally there is also an inferior arteria thyreoidea. All these vessels can be spared in performing crico-tracheotomy. The skin and superficial fascia are divided, and the margin of the sterno-thyroid muscle is drawn upward with blunt hooks. At first the incision is directed only against the anterior circumference of the cricoid cartilage which can always be felt, and the cartilage

is entirely exposed. The cricoid artery on the crico-thyroid ligament is preserved. After the cartilage is laid bare the deep fascia which fastens the thyroid gland to the anterior surface of the cricoid cartilage is detached from the inferior edge of the latter. By entering with a blunt instrument the upper tracheal rings can all be laid bare without cutting, by lifting the fascia with the thyroid isthmus and all the vessels in its region downward from the bared trachea (Fig. 39).

If crico-tracheotomy does not afford sufficient room or it is desired to make the tracheal wound farther from the larynx, the cutaneous incision must be prolonged downward and the fascia between the sternal muscles below the isthmus divided exactly in the median line. The inferior venæ thyreoideæ always remain to the right and left, as they pass vertically downward. The deep fascia having been divided without cutting, we come upon the trachea and may open it below the isthmus (inferior tracheotomy), or else we may introduce an aneurism needle between the trachea and the isthmus which latter has been bluntly detached from above and below. Then the isthmus is firmly ligated with strong thread to the right and left of the median line and divided. This mode is preferable where the trachea is to be adequately exposed.

Where such an operation is to precede a subsequent laryngotomy or laryngectomy, inferior tracheotomy is to be preferred, as it leaves the field free for the second operation. Wherever possible such preliminary tracheotomies should precede the main operation a number of days.

56. *Laryngotomy and Laryngectomy.*—There is an absolute indication for opening the larynx in the case of intra-laryngeal malignant tumors; the operation may become necessary in relatively benign tumors such as papilloma of the larynx, ulcers, infectious diseases, and tuberculosis of the larynx. Median exposure of the larynx is comparatively a simple operation. The incision passes downward in the median line from the hyoid

bone to the upper part of the trachea. This causes injury of some vessels: the hyoid artery (branch of the lingual) at the hyoid bone; the crico-thyroid artery (branch of the superior thyroid) on the crico-thyroid membrane; a transverse branch of the superior thyroid passing to the pyramidal process of the thyroid gland; also numerous veins and transverse connections of the venæ medianæ colli and deeper veins. All these vessels must be ligated. After dividing the skin and fascia, the muscles passing from the sternum to the larynx and hyoid bone are drawn aside. The median hyo-thyroid membrane is divided above the thyroid notch, and the perichondrium of the cartilaginous plates of the thyroid inferiorly. Now a hollow sound can be passed beneath the anterior edge of the thyroid cartilage and sever it, or it may be freely divided from without and the plates drawn asunder with sharp double tenacula before the mucous membrane is cut.

It must be laid down as a rule that several days before this operation it should be preceded by an inferior tracheotomy, so as to secure perfectly free respiration during and after the operation and in order that the entry of blood and mucus into the air passages may be positively prevented by the insertion from above of soft little sponges. Instead of tamponing simply through the laryngotomy wound above the tracheal canula, the tamponade can also be effected from the tracheotomy wound by tying a flat soft sponge like a diaphragm to the lower end of the tracheotomy canula. To obtain an unobstructed view into the interior of the larynx we require complete anæsthesia during which the cough reflex is inhibited. It is best to use besides chloroform a local application of a ten-per-cent cocaine solution. By this means malignant neoplasms can be thoroughly inspected and extirpated. Should more room be needed the epiglottis can be divided above. For exact coaptation of the plates of the thyroid cartilage the cricoid cartilage forms a good support, provided it can be spared.

57. *Laryngectomy.*—Where the entire larynx is diseased, a transverse incision along the hyoid bone is added to the longitudinal incision for the purpose of laryngectomy. This additional incision is like that for subhyoid pharyngotomy. A tracheotomy a number of days before this operation is particularly indicated. Through the longitudinal incision the anterior surface of the larynx is laid bare and the sterno-hyoid and thyro-hyoid muscles are severed close to the hyoid bone. Then the hyo-thyroid membrane which is attached under the hyoid bone, especially its strong median ligament, is divided along with the mucosa beneath, and the epiglottis is drawn out with a stout hook. The latter organ is divided close to the diseased point; then the morbid portion is circumscribed above with the knife. Generally the thyroid cartilage is now divided, eventually also the cricoid cartilage and a portion of the trachea, so as to furnish a clear insight into the extent of the disease; but this information can be gained also by introducing the finger. When a neoplasm completely fills the larynx the mucous membrane at its limit toward the pharynx is divided, and likewise forward toward the epiglottis. If we have operated in the median line, the mucous membrane will also be exactly divided along the lower limit in the larynx and in the trachea. Not until then is the outer surface of the larynx laid bare. As far as possible the muscles are preserved which cover the lateral and anterior surface of the larynx (the sterno-thyroid and hyo-thyroid). If the muscles are diseased they are removed. The cartilages are exposed and as far as they adjoin the neoplasm directly they are removed, in total disease over the entire circumference. On the posterior surface of the cricoid cartilage the œsophageal mucosa is preserved if it is healthy and movable. Thus we reach the lower limit of the disease and make a transverse division in healthy tissue, whether it be the trachea or the cricoid cartilage.

The anterior pharyngeal and œsophageal wall is sutured up-

ward as far as possible in order to restore the septum between the air and food passages.

The after-treatment is the same as in pharyngotomy.

58. *The Innominate Artery* (Fig. 36).—This artery is the one nearest the heart, which is accessible to ligation; it is always a grave operation, in view of secondary hemorrhages. As a rule, therefore, we ligate at the same time the main branches which carry the blood back. These are the common carotid and the vertebral artery. The pulsation of the artery may be felt in the jugulum. For the purpose of ligating it we make an oblique incision at the anterior margin of the right sterno-mastoid muscle, extending from its middle third to the anterior surface of the manubrium of the sternum. Skin and fascia are divided and the attachment of the sternal portion of the sterno-mastoid muscle is separated from the sternum. Two veins are to be preserved: the transverse connection of the two venæ medianæ colli in the notch of the sternum and the transverse vein behind the attachment of the muscle. Thus we reach behind the sterno-clavicular articulation the common carotid artery. The right inferior vena thyreoidea is to be ligated and cut. The lateral margin of the sterno-hyoid and sterno-thyroid muscles is incised transversely and these muscles are drawn in a median direction together with the branches of the descending hypoglossal nerve, and finally the deep fascia is severed. Between the sterno-mastoid and the other muscles we follow the carotid down to its junction with the subclavian under which the trunk of the innominate is ligated; the pleura lying postero-externally must be protected. The left innominate vein, coming from the left, lies in front of the artery. The vagus and the loop of the recurrent laryngeal remain laterally and so does the phrenic nerve.

59. *Excision of the Diseased Thyroid Gland.*—The description here given for this operation is based on a case of moderate severity. For slighter cases, *i.e.*, movable circumscribed nodules

of struma, it is best to use the method which we designate as enucleating resection. Very difficult cases can be undertaken only by a surgeon who has gathered experience in less complicated excisions.

The best cicatrices result from the transverse curved incision (collar incision, Fig. 7) along the cutaneous folds, but this gives less ready access and is therefore to be reserved for the slighter cases. Amply sufficient room for all cases is furnished by the angular incision. This begins at the height of the thyroid cartilage on the prominence of the sterno-mastoid muscle, passes transversely in the direction of the cutaneous fold as far as the median line, and then down along this to the jugulum. In more deeply seated struma it is prolonged to the manubrium sterni. In the transverse portion we divide the skin and platysma, and toward the median line the thick mediana colli vein which is doubly ligated. The external jugular vein is preserved. After the superficial fascia is sufficiently divided the muscles are laid bare. The sterno-mastoid is drawn outward. At its anterior margin, as a rule, a vein must be ligated (the connecting branch between the external and median jugular veins). In the median line the fascia is divided which unites the sterno-laryngeal muscles; above the sternal notch a transverse vein is often ligated. The medial margin of the last-named muscles is freed and the finger is inserted beneath them so that their upper end may be incised but not severed, the vessels belonging to the upper stump being ligated. Then these muscles likewise are drawn aside with hooks.

The connective-tissue layer, which is usually thin, is then lifted above the goitre, whose capsule is raised and divided until the brownish-red or bluish surface of the goitre with its thick veins is exposed. The finger is passed carefully around the goitre so as to make sure that no larger veins run anteriorly or laterally from the capsule to the surface of the struma. Should this not be the case, the struma is lifted and displaced forward

over the withdrawn muscles. This is especially desirable in cases associated with marked symptoms of pressure and stenosis, because this step suddenly relieves the trachea and respiration becomes easy. But it should be done only when no large veins are torn thereby. Accessory veins often pass from without to the surface of the goitre and must be doubly ligated before the luxation.

Where the goitre can be turned sufficiently, we see and feel behind it the inferior thyroid artery and associated vein; these pass in a curve from without toward the attachment of the tumor to the trachea and can be ligated. This should be done, however, only after careful isolation, because the vessels are crossed by the recurrent nerve; for the same reason the artery is not severed but merely tied.

We now turn to the upper or lower pole of the tumor, whichever is more readily isolated. When the struma is not deep, *i.e.*, when the lower cornu does not extend into the thorax, we isolate at the lower pole the inferior thyroid vein, which is usually very thick and near the goitre divides into several branches. These vessels become tense when the tumor is lifted and can be doubly ligated and cut without fear of incidental injury.

The external capsule being properly separated as far as the upper pole, we seize the superior cornu at its upper end and thus isolate the upper pedicle with the superior thyroid artery and vein, which are included in a common double ligature (very firmly tied) and divided.

At the upper and lower margin of the thyroid isthmus we find respectively a communicating superior and inferior vein, and now and then an artery of the pyramidal process above. If possible they are ligated separately. Then a struma sound can be passed between the trachea and isthmus and the latter surrounded with a strong ligature and divided under traction.

Usually more or less of the thyroid-gland tissue remains

normal and may be preserved. To this end, after the goitre has been freed as far as the isthmus, it may be rested on the fingers of the left hand, thus lifted out and stretched, and the incision carried through the tissue parallel to the trachea at some distance from the isthmus as far as the nodule. The bleeding vessels are ligated while the median circumference of the nodule is enucleated without cutting, until the healthy glandular substance at the posterior surface is reached, when this portion, too, is divided at some distance from the trachea. By this enucleating resection we also avoid injuring the recurrent nerve at the median circumference of the tumor. A semi-lateral excision should never be made until we have assured ourselves of the presence of a lobe on the other side.

J. The Lower Lateral Triangle of the Neck.

The supra-clavicular triangle is limited by the clavicle, the sterno-mastoid muscle, and the trapezius muscle. The surgery of this region is simpler than that of the upper lateral triangle of the neck. Here the large vessels and nerves run to the arm, and here, too, we strike the branches of the subclavian artery and vein. The background of the triangle is formed by the first rib and the first intercostal space, together with the lateral neck muscles, especially the scaleni.

The normal incision (Fig. 25) for this region, which corresponds to the cleavage line of the skin, lies almost transversely, from the attachment of the sterno-mastoid muscle at the clavicle, rising somewhat obliquely to the margin of the trapezius. The incision is used for the ligation of the subclavian artery, under which head it is described.

60. *Subclavian Artery* (Figs. 24 and 25).—This vessel springs from behind the manubrium sterni, passes over the pleura of the apex of the lung, over the first rib between the scalenus anticus and medius muscles, then it reaches the outer surface of the thorax under the middle of the clavicle between the sub-

clavius and serratus muscles. It can be with certainty compressed at the outer margin of the scalenus anticus muscle.

In order to ligate the vessel a transverse incision is made, beginning a finger's breadth above the clavicle on the clavicular portion of the sterno-mastoid muscle and extending to the anterior margin of the trapezius muscle, slightly ascending in a lateral direction. After dividing the skin we strike the platysma and the sensory supra-clavicular nerves from the upper cervical plexus, which supply the upper portion of the thorax and the shoulder. These are divided transversely. Then the fascia is severed. At the lateral margin of the sterno-cleido-mastoid muscle the external jugular vein must be preserved; it bends down over the posterior margin of the muscle toward the common jugular vein. Lesion of this vein is dangerous because the fascia through which it passes keeps it tense and hence air may be aspirated. If it cannot be drawn inward it must be doubly ligated before being cut. After the fascia is divided, there appears in the inner angle of the wound the omo-hyoid muscle, rising obliquely inward in the adipose tissue of the triangle with imbedded glands. In this adipose tissue lie the transverse scapular artery behind the clavicle, the superficial cervical artery ascending posteriorly, above the latter but under the deep fascia the rather thick transversa colli artery which passes backward upon or through the nerve plexus.

After removing the adipose tissue, the thin deep fascia covers the brachial plexus, now becoming visible, whose thick nerve trunks emerge between the scaleni muscles and descend steeply under the clavicle. The relation of the artery to the nerve plexus is very characteristic. If we pass down toward the first rib along the anterior surface of the nerve plexus we find the attachment of the scalenus anticus muscle at the rib marked by a prominence—the tubercle of Lisfranc; behind this the artery passes covered by the nerves. In a median direction from the scalenus anticus muscle lies the bulb of the common

jugular vein; in front of the muscle and upon the first rib, the subclavian vein, hence apart from the artery. On the anterior surface of the scalenus anticus muscle the phrenic nerve passes into the thoracic cavity. Alongside of the scalenus muscle the thoracic duct passes from the thorax into the neck and termi-

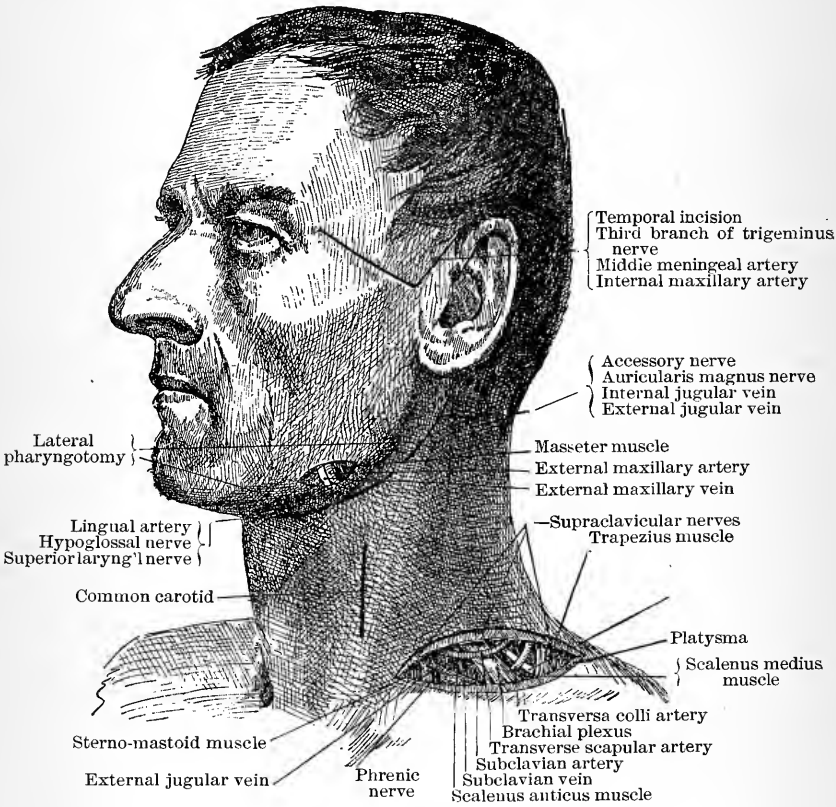

FIG. 40.

nates in the angle between the subclavian and common jugular veins.

The branches of the subclavian artery, three of which we have already mentioned, spring from the main trunk in a central direction from the scaleni muscles, excepting the transversa colli. The guiding points for finding the vertebral and the inferior thyroid artery have been given above.

The ligation of the internal mammary artery will be discussed below.

61. The external branch of the spinal *accessory nerve* (Fig. 10) becomes visible in the lower cervical triangle beneath the middle of the sterno-mastoid muscle immediately under the first fascia, that is, quite superficially; its course is obliquely backward to the trapezius muscle. When the nerve is to be stretched or divided in spasmodic conditions it is exposed by a transverse incision which intersects the posterior margin of the sterno-mastoid muscle at its centre. At the same point the

62. *Subcutaneous colli nerve* and the

63. *Auricularis magnus nerve* surround the posterior margin of the muscle.

64. Through the normal incision for the lower cervical triangle may be exposed, besides the large nerve trunks of the axillary plexus, also all its shorter branches. They spread in a conoidal form over the thorax, posteriorly, exteriorly, and anteriorly. Posteriorly we have the dorsal scapular nerve passing to the levator scapulæ and the rhomboid muscles, through the scalenus medius; exteriorly, the suprascapular nerve passing to the incisura scapulæ to supply the supra-spinatus and infra-spinatus muscles; the axillary nerve, passing along the lateral wall of the axilla between the teres major and minor on the one hand and the anconæus longus and humerus on the other hand to the lower surface of the deltoid to supply the latter, the teres minor, and by a sensory branch the dorsal side of the arm; the subscapular nerves which pass at the posterior wall of the axilla to the teres major, subscapularis, and latissimus dorsi; the thoracic posticus (longus) nerve which extends from the medial wall of the axilla to the serratus anticus major; anteriorly, the anterior thoracic nerves which surround the subclavian artery and pass between the pectoralis major and minor to supply these two muscles.

K. The Nuchal Region.

The surgery of the upper nuchal region has been discussed with the occiput (which see for the occipital artery and the major and minor occipital nerves).

There are no large vessels and nerve trunks in the lower nuchal region. Incisions are very often made at the nucha in inflammations, especially furuncles and carbuncles. Deep incisions can be made without the fear of wounding important structures.

For opening the spinal canal see the dorsal spine.

L. The Thorax.

The main indications for incisions on the thorax are furnished by diseases of the pleura and the ribs, less often by disease of the lungs, and most rarely by affections of the pericardium. Among the larger vessels to be ligated are the internal mammary artery and the intercostal arteries, but above all the subclavian artery and its branches.

65. *Internal Mammary Artery* (Fig. 36).—This supplies the inner surface of the anterior thoracic wall and its branches pass through the latter to the skin. With its concomitant vein it lies upon the pleura from which it is separated by a very thin layer of fascia and below by the anterior thoracic muscle. In front the artery adjoins the costal cartilages and the intercostal muscles.

It is ligated through a transverse incision in the intercostal spaces where the sternum is narrowest, hence by preference in the second. The incision is carried from the middle of the sternum transversely outward between the costal cartilages, and divides the skin, fascia, and the pectoralis major muscle. Now appear the obliquely inward descending fibres of the fascia of the external intercostal muscle (ligamentum coruscans); this

fascia is often very thin and beneath it the obliquely outward descending fibres of the internal intercostal muscle become visible. As soon as these are divided the artery is seen passing down on the pleura, about 0.5 to 1 cm. from the edge of the sternum. The vein lies more medial.

66. *Intercostal Artery* (Fig. 36).—The main branch of this artery passes between the two intercostal muscles to the lower edge of the rib, while a smaller branch runs along the upper edge. Its ligation is not easy because the artery is hidden under the overhanging antero-inferior edge of the rib.

The external intercostal muscle which descends obliquely inward is divided, the artery is surrounded from behind with a ligature, very carefully lest the pleura be injured, or for safety's sake a subperiosteal resection of a portion of the covering rib may be made.

67. The *intercostal nerve* passes below the artery and must be drawn aside. It can be exposed like the artery in order to be stretched in neuralgias.

68. *Thoracotomy.*—The best method for the free opening of the pleural cavity is that preceded by resection of the ribs. For mere puncture we enter between the ribs, nearer to their upper than their lower edge, on account of the nerves and the larger vessels. The skin is pressed as deeply as possible into the intercostal space, and the trocar vigorously pushed in beside the finger above the upper edge of the rib. For large trocars a small cutaneous incision is made first.

69. For resection of the ribs (Fig. 36) the incision is made over their largest curvature, parallel to both margins. In cutting directly upon the bone no larger vessel or nerve is injured, only the covering skin and muscle. After the periosteum is divided it is very carefully detached with an elevator, above, below, and behind the rib, and a piece cut out of the latter, thus laid bare, with strong bone forceps.

Behind the rib, covered besides the periosteum with a very

thin fascia (the endothoracic), lies the pleura, which can then at once be incised in the direction of the exsected rib, the presence of the exudation having been determined, in doubtful cases, by puncture.

Very often the resection of a single rib does not suffice. In such a case the upper rib is cut in like manner (Fig. 41) through the same cutaneous incision, the skin being drawn strongly upward; a piece is resected also from this rib and the underlying pleura opened likewise longitudinally as with the first rib. An aneurism needle is now passed at the lateral and medial end of the two pleural incisions under the intervening tissues of the intercostal space, the vessels are ligated together with the pleura and muscles, and after this is done the two pleural incisions are connected in the centre by a vertical cut; thus we obtain a gaping opening in the form of a recumbent H (I).

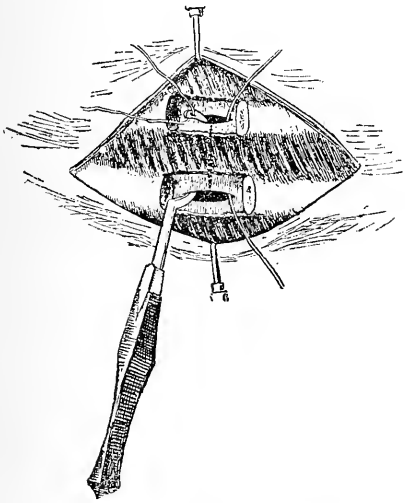

Fig. 41.—Free Opening of the Thorax, with Resection of two Ribs.

If permanent drainage is to be provided for, the opening must be made in the lowest part of the cavity. In the line of the nipple we still strike the pleural cavity after removal of the cartilage of the sixth rib. In the lateral region the pleura is struck on the right after removal of the ninth rib and on the left even of the tenth rib; behind in both scapular lines after removal of the twelfth rib. But there is a contra-indication to the inconsiderate opening of the pleura at these lowest limits, especially with pointed instruments, because the diaphragm of the anterior chest wall might immediately adjoin it; it is advisable, therefore, to open the pleural cavity at first at the point where fluid

is sure to be met, *i.e.*, where its presence has been determined by aspiration. Only after free access has been gained here a sound is introduced to the lowest part of the cavity, or else this is ascertained by the finger from within. A second opening is then made in the same way by costal resection at the latter point and through-drainage thus provided for.

70. *Resection of Larger Portions of the Chest Wall.*—Extensive excisions of the chest wall are apt to be called for in pleural disease with retraction of the lung, where a closure of the pus cavity is mechanically impossible through rigidity of the wall: in neoplasms, especially chondromata and sarcomata of the ribs which have involved the pleura. The operation bears Estlander's name, although isolated extensive resections were performed and reported before his time (De Cerenville).

Through every large incision running parallel to the ribs a number of ribs can easily be resected. But if larger portions of the chest wall must be removed in one piece, flap incisions are required. For these two directions are to be recommended: incision beginning at the anterior axillary fold, running obliquely backward and downward over the lateral surface of the thorax between the attachments of the serratus anticus major and the latissimus dorsi posteriorly and the external oblique of the abdomen anteriorly. To this is added an oblique incision along one of the ribs at the desired height. The second direction of the incision runs vertically along the margin of the extensors of the back to the posterior angles of the ribs, dividing the tendinous portion of the latissimus and partly of the trapezius and serratus posticus inferior. To this incision, which runs from above downward and strikes the border line of the large muscular regions and their nerve twigs, is likewise added a second incision parallel to the course of the ribs, according to requirements.

71. *Operations on the Lungs.*—At any desired point where abscesses, cavities, or, exceptionally, new-formations in the pul-

monary tissue call for interference, the lung may be exposed in the same manner as the pleural cavity is opened; with this difference, however, that we must be sure, either by adhesions artificially induced (cauterization) or by direct fixation previous to free opening, that the portion of the lung in question is kept in contact with the chest wall, unless adhesions have been caused by the disease.

For the opening of cavities at their most frequent seat, namely, the apex, the operation is performed as follows:

Incision through skin, fascia, and pectoralis major muscle along the first intercostal space, parallel to the clavicle, and in a lateral direction from its sternal end. Division of both intercostal muscles, medially only the internal. At this point the internal mammary artery should not be injured, nor the subclavian vein at the lateral end of the incision.

At the lower edge of the first rib the periosteum on its anterior surface is divided and carefully displaced forward and backward; then the lower two-thirds of the rib are resected, leaving a bridge above, lest any of the large vessels resting upon the rib be injured. Aspiration with a hypodermic syringe is now resorted to in order to determine the position of the cavity, a small incision is made through the pleura, and enlarged with a pair of arterial forceps.

M. Opening of the Spinal Canal.

Horsley by his brilliant operations has shown the excellent results to be obtained by relieving the pressure on the cord caused by tumors, even in very advanced cases, and other surgeons have reached equally satisfactory effects by relieving the pressure due to fracture and luxations of the vertebræ or by opening abscesses.

72. The operation is performed in the following manner:

Long median incision down to the spinous processes, detach-

ment of the muscles on both sides with the knife, close to the bone (especially the transverso-spinalis muscle), if necessary by the aid of transverse nicking of the thick covering fascia. The exposed spinal processes are removed at their base with bone forceps, together with the interspinal ligaments. The posterior arches are removed by making a transverse incision through the stout intercrural (flava) ligaments along the upper and lower margin of the arches close to the bone. The arches are severed on both sides and lifted out, one after the other, until the cord is sufficiently exposed.

Adipose tissue and large vessels (circuli venosi) are divided with the knife and ligated if necessary, then the dura is opened in the median line. Of course, when the pressure is due merely to a displaced or broken vertebra, or an extradural tumor or abscess, the dura is not opened.

Even when the dura has been opened, a complete suture is to be applied after drainage, and thus healing by first intention may be secured in the course of forty-eight hours.

N. Lumbar Region.

73. *Nephrotomy and Nephrectomy* (Fig. 42).—The incisions for exposing the kidney best illustrate the normal incision for the lumbar region. Nephrotomy is performed for wandering kidney so as to fasten the organ to the skin and fascia, for opening the pelvis and the calyces of the kidney in hydronephrosis, pyonephrosis, nephrolithiasis, and neoplasms. Nephrectomy is performed for the total removal of the kidney in the case of tumors and extensive disease by lithiasis, inflammations, and tuberculosis. The same incision exposes the ureter.

The correct direction is a transverse incision beginning on the prominence of the sacro-lumbar muscle and passing under the twelfth rib to the anterior axillary line. It divides the skin, subcutaneous tissue, the thick lumbo-dorsal fascia with its cor-

responding muscles, the latissimus dorsi and beneath it the serratus posticus inferior. The most lateral serration of the former muscle appears as a flat, thick muscular bundle. The remaining part of the muscle is cut laterally from the sacro-lumbar margin, as are the thin fibres of the serratus posticus inferior which ascend obliquely outward and are not always recognized as a separate layer. The sacro-lumbalis is slightly nicked at its margin or vigorously drawn in a median direction with a blunt hook. In the case of longer incisions the external oblique abdominal muscle with its descending fibres is transversely divided for a short distance, and at its posterior margin and beneath it the obliquely ascending fibres of the internal oblique are treated in the same way. At the margin of the sacro-lumbalis and between the divided ends of the above-mentioned two abdominal muscles appears the tense, glistening lumbo-costal fascia, from which spring the fibres of the transversus abdominis muscle.

After this fascia is divided, the margin of the quadratus lumborum muscle becomes visible, running almost vertically and parallel to the margin of the sacro-lumbalis; beneath it appears the twelfth intercostal nerve with its concomitant thick vessels, passing antero-inferiorly. The first lumbar (ilio-hypogastric) nerve descends more deeply than the twelfth intercostal, at the margin of the quadratus muscle. Anteriorly the nerves perforate the transversus and pass between it and the obliquus internus muscle. They are drawn upward and downward, and the vessels, if necessary, are ligated and cut.

At the lateral margin of the quadratus muscle, which according to requirements may be nicked or withdrawn, under the thin transverse fascia lies the abundant retro-renal loose adipose tissue, with vessels. A finger is inserted, carefully separates these tissues (capsula adiposa), and reaches the kidney without meeting with resistance. For nephroraphy the thin fibrous capsula propria which covers the kidney tensely is nicked and detached from the organ without cutting.

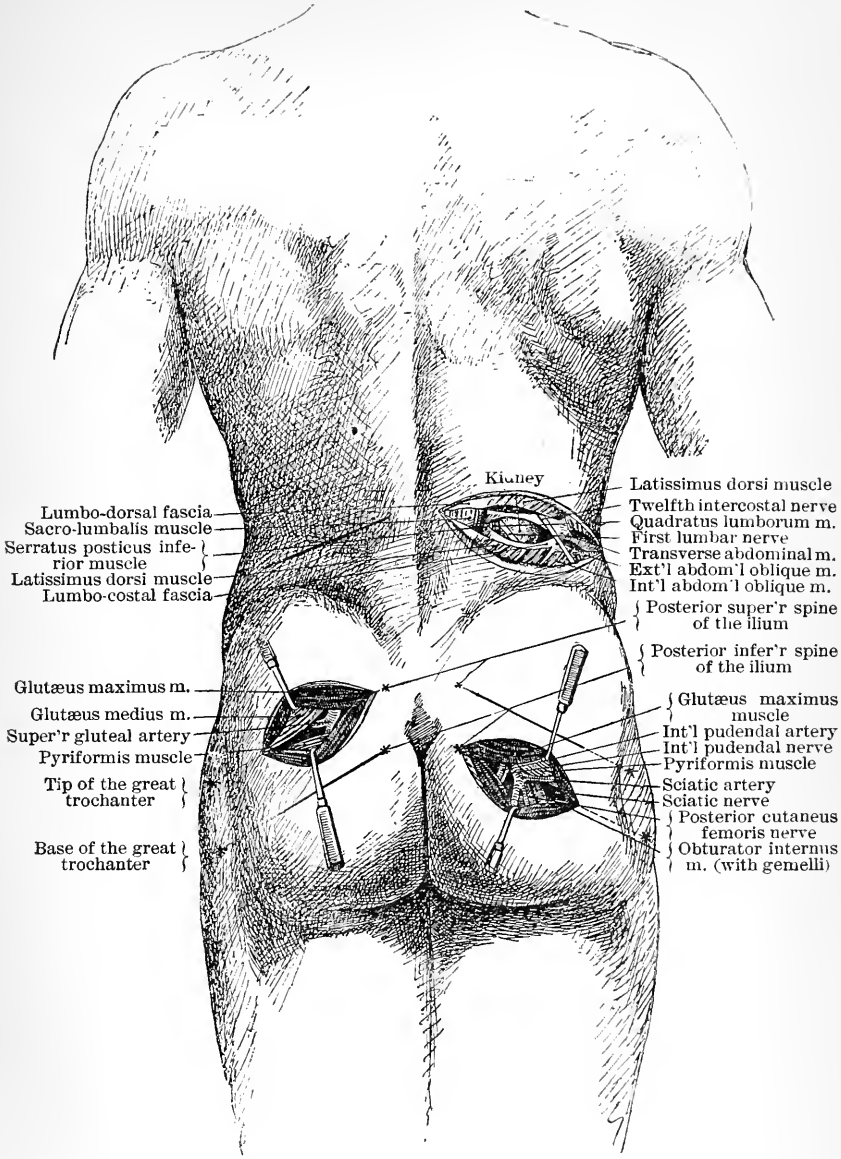

FIG. 42.—Nephrotomy. Gluteal and sciatic arteries.

If the kidney is to be luxated *in toto* for examination, incision, or excision, the detachment of the fibrous capsula propria is omitted. The renal pelvis can be palpated from behind by passing the finger toward the hilus, the ureter lying behind the vessels.

The renal pelvis is incised directly from behind if it is dilated; in other cases it is better to make a short longitudinal incision from the convexity of the kidney and insinuate the finger in the direction of the hilus as far as the pelvis of the kidney.

Where the parenchyma of the kidney has been injured it is advisable to adopt the open wound treatment or secondary suture, not only on account of the discharge of the urine, but because, according to our experience, gained by the aid of Dr. Tavel, injuries to the kidney are apt to infect the neighborhood. The kidney usually contains (by excretion?) micro-organisms which give rise to inflammation. For this reason it is a good plan to prepare such patients for the operation by the administration of salol, 45 grains *pro die.*

As regards nephrectomy we have in recent years invariably adhered to the practice of lengthening the transverse incision so far forward as to strike the transition fold of the peritoneum adjoining the colon, which comes within the region of the axillary line, and to open the peritoneum first at this point. From here we always succeed in insinuating the hand far enough into the abdominal cavity to palpate the other kidney, ascertain its size and consistence, and feel the renal artery. After determining the presence of a well-developed kidney on the opposite side, the peritoneum was sutured and the operation performed in the above-described manner.

74. *Ureter.*—The ureter can be exposed at various points:

a. At its lowest point; see Exposure of the seminal vesicles and vasa deferentia from the perineum, in surgery of the perineal region, and from the posterior pelvic incision.

b. On the internal iliac fossa; see Ligation of the common iliac artery.

c. In the neighborhood of the kidney by the same incision as for nephrotomy; or, in case it must be followed for some distance downward, by a longitudinal incision along the margin of the sacro-lumbar muscle.

75. In an analogous manner to the kidney the spleen can be exposed on the left side, the incision being lengthened forward. We abstain from giving a detailed description because the method of operation depends too largely on the individual relations of the case, especially the size and nature of the tumors.

O. Abdomen.

Normal Incisions.—Access to the contents of the abdomen is obtained with the least amount of incidental injury by a vertical incision in the anterior median line. No large vessels are met with, aside perhaps from an unobliterated umbilical vein and a few veins in the subserous adipose tissue.

The incision divides the skin, superficial fascia, and the linea alba, *i.e.*, the union of the aponeuroses of the recti abdominis muscles. Beneath this lies the transverse fascia and under this the peritoneum, covered with more or less subserous fat. Above and below the peritoneum can be displaced on the linea alba; in the region of the umbilicus it adheres firmly.

For the deeper organs lying more laterally the median incision does not always suffice, *i.e.*, it inflicts an unnecessary injury because the intestines present; especially organs near the hypogastrium and hypochondrium are too far for a median incision. The rather common lateral longitudinal incisions along the margin of the rectus abdominis muscle should be rejected because they divide the nerves supplying the latter muscle. In the case of long incisions this drawback should not be undervalued, especially in the upper part of the abdomen. Paralysis of the muscle favors the development of abdominal hernias.

Aside from the median incision the only rational ones with

reference to the course of the nerves are transverse incisions (Fig. 36) or transverse oblique incisions placed parallel to the nerve trunks. It is true these transverse incisions divide the three broad abdominal muscles, but the nerves lying between the several layers, especially the internal oblique and the transversus, can be pushed out of the way. Even the rectus abdominis is less injured by a transverse incision than by a longitudinal one made laterally, because the motor nerves remain intact and merely an artificial inscriptio tendinea is superadded so that the muscle contracts as before. Still in transverse incisions the superior and inferior epigastric artery must be cut and ligated.

Hypochondrium.

76. *Cholecystotomy* (Fig. 36).—The following is the procedure for opening and eventually removing the gall bladder. Oblique transverse incision 4 to 6 cm. below the free border of the ribs, 10 to 15 cm. in length. It begins three fingers' breadth from the median line on the prominence of the rectus abdominis, divides the skin, superficial fascia, and the fascia of the internal oblique; in front of the rectus the two fascias are united. Underneath appears the rectus, whose lateral half is divided; the superior epigastric artery under its lateral margin being ligated. In the lateral portion the external abdominal oblique muscle is cut, and still farther away the internal oblique and the transversus. Beneath these the terminal branches of the intercostal nerves pass obliquely inward toward the rectus. Smaller perforating twigs of these nerves are met with in the first fascia.

Beneath the muscles appears the transverse fascia, quite thick at this point, with its transverse fibres, and after it is divided the peritoneum is reached. When the latter is opened the gall bladder can be seen and removed if it is lengthened and enlarged.

For cholecystectomy the visceral peritoneum must be divided

parallel to the border of the liver, at the apex of the fundus of the bladder, and the gall bladder detached subperitoneally, without cutting, as far as the cystic duct; the artery vesicæ felleæ being ligated. The duct is doubly ligated and divided. Since micro-organisms may migrate from the intestine into the bile ducts, the peritoneum must be protected with sterilized pledgets, and after the duct is cut the stumps must be disinfected by means of sublimated cotton or the thermo-cautery.

Hypogastrium.

As a type of the operations in the region of the lateral hypogastria we may instance the ligation of the common and the external iliac artery. In the case of the former we enter the peritoneum by an incision two fingers' breadth above Poupart's liagment. In the case of the latter the peritoneum is avoided by keeping close to Poupart's ligament and dividing only the transverse fascia which is attached to it; while the peritoneum forms a reduplication on the internal iliac fascia, about 0.5 cm. above (for both these ligations see below).

In an analogous manner abscesses of the internal iliac fossa can be opened extra-peritoneally by proceeding upon or beneath the internal iliac fascia; or else we may proceed after opening the peritoneum if the vermiform appendix is to be resected, tumors of the cæcum are to be removed, or if on the left side the sigmoid flexure is to be drawn out for the formation of an artificial anus or for removal in the case of neoplasm. A transverse incision from one side to the other, from the right anterior inguinal ring to the one on the opposite side, is indicated when the bladder is to be opened (compare Fig. 7).

The inguinal canal is opened directly in its course when the spermatic cord is to be exposed in castration, or the round ligament is to be sought, or finally if the neck of a hernial sac situated in the canal is to be reached (herniotomy).

EXPOSURE OF THE INGUINAL CANAL (for herniotomy, castration, varicocele operation, and Alexander's prolapsus operation).

77. *Castration. Excision of the Tunica Vaginalis* (Fig. 7). —Transverse incision along the inguinal canal one finger's breadth above Poupart's ligament, running in a median direction downward parallel to the median third of the ligament. The incision corresponds exactly to the cleavage line of the skin and therefore adheres very readily. In the subcutaneous tissue and superficial fascia a thick vein descending from above is to be ligated without and within. The superficial epigastric artery, ascending from the femoral artery across the abdominal wall, is severed with the external vein if the incision is lengthened laterally. Then follows division of the thin external fascia of Cooper, which incloses the spermatic cord, and is a delicate continuation of the fascia of the external abdominal oblique muscle; of the muscular fibres of the cremaster (from the internal oblique) laterally from the last-named fascia; and of the thick infundibuliform fascia (a continuation of the transverse fascia). This contains the spermatic cord, or, respectively, the round ligament and possibly diverticula of the peritoneum in the shape of hernial sacs. In the case of castration it is easy to turn the testicle upward, unless it is adherent to the scrotum or greatly enlarged, and remove it, or to replace it if no more is intended than the division and excision of the tunica vaginalis in hydrocele vaginalis and funiculi.

When the testicle is adherent or the seat of larger tumors the castration is performed by means of a transverse incision in a frontal direction at the lower end of the scrotum. After the skin and dartos tunic (Fig. 7) are divided between the visible larger scrotal vessels, the testicle with its envelopes is turned out. As the incision is parallel to the scrotal vessels (external scrotal arteries), so it is also on the surface of the vaginal tunics parallel to the branches of the vessels of the spermatic cord passing to the lower pole.

78. *Inguinal Herniotomy.*—The incision for this operation is exactly like that for the exposure of the spermatic cord described above. After sufficient division of the cremaster and especially of the infundibuliform fascia, the neck of the hernial sac can generally be readily isolated, without cutting, from the structures belonging to the spermatic cord and lifted by traction from the scrotum as far as its rounded lower end. The limits of a thin hernial sac can also be rendered apparent by stretching the tissues of the spermatic cord and holding them to the light.

For the radical operation upward the hernial sac is carefully isolated and vigorously drawn down, until the portion lying in the posterior inguinal ring can be seized, stitched with silk thread, and strongly ligated in two directions. After being cut off below, the ligated portion is entirely withdrawn into the abdomen. Then a series of deep sutures are placed through the fascia of the external oblique and the muscular fibres underneath so as to narrow the entire length of the inguinal canal.

79. *Isolation of the Round Ligament* (Fig. 43).—The round ligament in the female sex is isolated in an analogous manner to the spermatic cord. But the operation is much easier because of the absence of the cremaster and of a distinct infundibuliform fascia. The placing of the incision depends upon the way the ligament is to be stitched, in retroversion, retroflexion, and prolapsus uteri. We have obtained very good results from the following modification of Alexander's operation:

The entire length of the incision is carried the breadth of the little finger above Poupart's ligament through the skin, the superficial fascia, and above the inner half, *i.e.*, above the inguinal canal, through the fascia of the external abdominal oblique. The superficial hypogastric artery in the superficial fascia together with the vein, and a vein ascending vertically at the inner angle of the wound, are ligated. The round ligament with the accompanying thin vessel can now at once be isolated out of the groove of Poupart's ligament without resort to the

knife. The round ligament is freed from its peripheral attachments toward the symphysis and vigorously drawn out in the direction toward the anterior superior iliac spine. We can readily convince ourselves on the cadaver that by this means the uterus is drawn up, bent forward, and, if the operation is

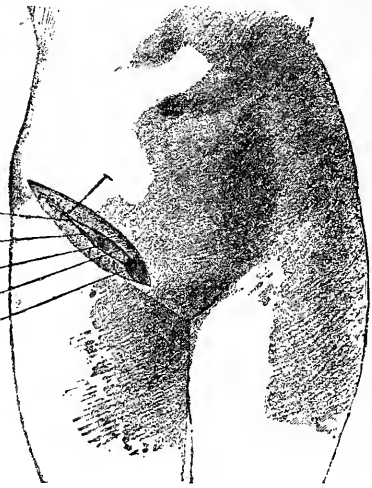

FIG. 43.

done bilaterally, held so tensely on both sides as to remain fixed in its new position.

But the round ligament carries with it a cone of parietal peritoneum about 3 cm. long. As soon as we have convinced ourselves that no intestines have come forward with this cone, the ligament is stitched with a continuous silk suture to the fascia of the external oblique. The suture includes also the peritoneal cone, begins at the anterior superior iliac spine, and extends to the posterior inguinal ring. Then the inguinal canal is again closed with deep sutures (compare No. 78).

80. *Resection of the Vermiform Appendix.*—The method of operation can here be only outlined for cases in which the appendix is resected in the intervals between relapsing inflammations, and in the absence of perityphlitic or paratyphlitic exudations and abscess.

The incision (see Fig. 7) is like that for the ligation of the common iliac artery but shorter, two fingers' breadth above the right anterior superior iliac spine, along the external half of Poupart's ligament and extending beyond its middle. The different layers are divided as in the ligation of the above-named artery, but the peritoneum is likewise opened in the line of the incision. If possible the cæcum is drawn out, otherwise the appendix, whose situation varies, is sought, freed from adhesions, and withdrawn. Its mesentery is cut between two ligatures. One centimetre from the attachment of the appendix to the cæcum the serous and muscular coats are cut around and dissected off; finally the mucosa is surrounded with silk thread as close as possible to the cæcum and severed, and the stump is touched with the thermo-cautery so as to disinfect it. Then it is turned in and stitched over it with a continuous silk suture.

81. *Formation of a Fecal Fistula* (Fig. 44).—In every case in which the intestinal gases cannot be expelled and thus give rise to respiratory and nutritive disturbances, the temporary formation of a fecal fistula may be indicated, especially in ileus in the more restricted sense and in peritonitis. By gaining time many a life can be saved. The operation, when correctly performed, is absolutely free from danger and therefore should not be postponed too long.

The abdominal wall is incised at various points, preferably, where choice is possible, two to three fingers' breadth above the middle of Poupart's ligament, and parallel to it, for a distance of 6 cm. After dividing the abdominal wall down to the peritoneum, the latter is nicked to a less extent, say 2 to 2.5 cm. As a rule a tense loop of intestine at once presents in the wound and is so arranged as to fill the whole width of the wound without being drawn out in any way. Then a button suture is inserted in each of the four directions, to include the intestinal and the parietal serosa with the fascia, but away from the peritoneal wound (Fig. 44), so as to fasten the intestine to the

abdominal wall. After this follows, corresponding to the edge of the peritoneal opening, an uninterrupted fine silk suture which hermetically presses the parietal and the intestinal serosa together. In the centre of the opening thus made a quick short incision is made with a small knife and a sound is introduced to

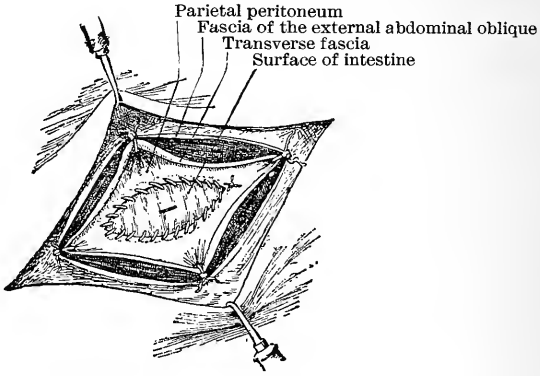

FIG. 44.—Formation of a Fecal Fistula.

make sure that the lumen of the intestine has been reached. The wound is powdered with iodoform or aristol, and warm 0.1% salicylated water compresses are applied and frequently changed.

82. *Formation of an Artificial Anus* (Fig. 45).—A small fecal fistula always suffices for the temporary evacuation of the intestine in tympanites. An artificial anus, therefore, is formed only in cases where a permanent-discharge and protection of the inferior intestine from the contents are intended. The operation is performed in the following manner: Incision two fingers' breadth above Poupart's ligament, extending laterally from its middle. After opening the abdominal wall as for fecal fistula by dividing the three muscular layers and fascia, and the peritoneum to a less extent, the intestine—for instance, the sigmoid flexure in impassable rectal cancer—is drawn into the wound until a complete loop is present. This is stitched to the parietal peritoneum with a continuous silk suture so that the afferent portion of the intestine has ample room, while the efferent portion is compressed by the former. Then a triangular piece is

resected from the convexity of the loop as far as the attachment of the mesentery. Unless opening is urgent it should be postponed until good adhesions have formed (two days).

83. *Resection and Suture of the Intestine* (Figs. 46 and 47). —If gangrenous herniæ, constrictions, or new-formations call

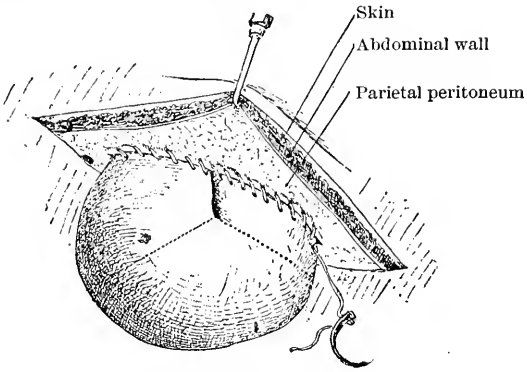

FIG. 45.—Formation of an Artificial Anus.[1]

for the removal of a portion of the intestine, the first care should be, not only that the resection be made in healthy tissue, but also at the points where a free mesenteric blood supply is assured. The intestine is not divided quite transversely, but in a somewhat oblique line, so that a little more is removed from the convexity so as to make sure of the circulation on that side of the intestinal wall which is farthest from the mesentery. The latter is never unnecessarily extirpated, even where it lies in thick folds, but always divided as close to the gut as possible, along its attachment.

For the suture the extremities of the gut must be placed in a handy position outside the abdominal cavity if at all possible, then the mesenteric portions of the two intestinal lumina are first brought in contact by a silk button suture, whose ends are left long. Next a second button suture is placed at the convexity through both intestinal lumina. The intestinal wall being now

[1] The figure represents the operation on the right instead of the left side and therefore should be reversed for the flexure.

turned in toward the lumen until broad surfaces of the serous covering are in contact (Lembert), a continuous and reliable silk suture is placed, which must include the muscular and serous tissues and be drawn very tight. Over this first suture is placed a second (after Czerny and Kocher) uninterrupted fine silk suture through the serosa only, the first end of the thread being tied to the last. A thorough cleansing with 0.7% table-salt solution at 98.6° F. is followed by another with 0.1% sublimate solution, and every trace of this fluid is again removed with warm salt water.

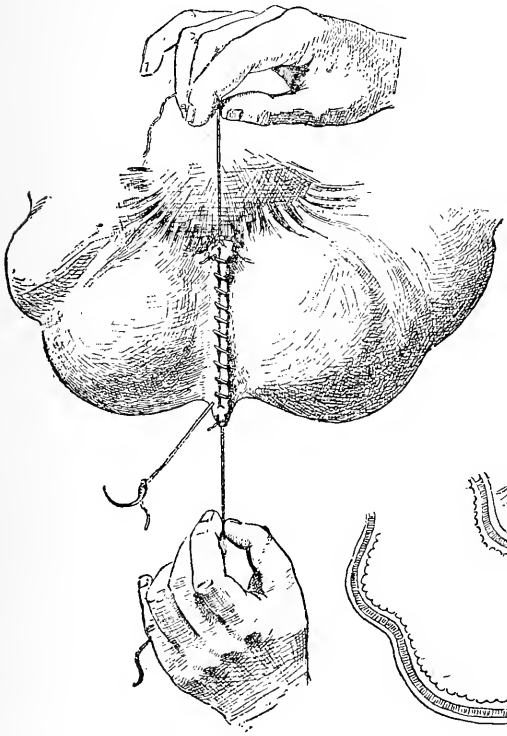

FIG. 46.

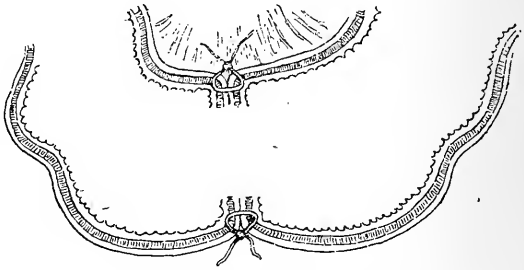

FIG. 47.—Intestinal Resection and Circular Intestinal Suture. Longitudinal section.

84. *High Supra-Pubic Cystotomy* (Fig. 7).—The bladder incision above the symphysis is at present the normal procedure for opening the bladder for very different indications, as, contrary to the perineal operation, it enables us to secure healing by first intention. The normal incision runs transversely in the fold above the symphysis through the fat, skin, and fascia so as to expose the recti. In the Trendelenburg position with its high elevation of the pelvis this permits a very good view upon

and into the bladder. Some vertical veins are to be severed and ligated. In order to gain sufficient room without exposing the peritoneum to danger, the soft parts above the symphysis are freely divided, and the incision is carried in a curve from the region above one inguinal canal to the same point on the opposite side. The attachments of the recti muscles to the symphysis are partly severed with the pyramidal muscles. In the depth a longitudinal division of the median line through the linea alba (united fascia of the abdominal recti) is added. The finger is introduced behind the symphysis and draws up the thin fascia, the subserous fat, and with it the reduplication of the peritoneum which can be seen or felt as a transverse fold or prominence.

This manipulation in conjunction with the high position of the pelvis renders unnecessary the elevation of the bladder by filling it or the rectum. The latter measures are not without danger from rupture or injury of these organs when diseased. It is desirable to draw a firm loop of thread through the entire thickness of the muscular layer at the lowest point of the bladder which can be readily reached. In the same way a second loop is passed through the muscular tissue of the vertex of the bladder at the peritoneal fold. The introduction of such loops materially facilitates the subsequent suture after the bladder has been evacuated.

Between the two loops the muscular tissue is divided in a vertical direction until the mucosa projects as a bluish vesicle. Hemorrhages are at once arrested. On puncturing this protrusion the urine (or the aseptic solution introduced into the bladder) spurts out and the incision can be extended according to requirements for the extraction of a stone, excision of a neoplasm, or mere inspection and digital exploration of the bladder. The mucosa does not need as large an opening as the muscular coat, being very elastic. The bladder is closed with a two-tiered suture, the first extending to the mucosa, the superficial one

(uninterrupted) including the covering cellular tissue with the muscular coat. Then follows the closure of the external wound.

Before the operation the bladder has been thoroughly irrigated and filled with 150 to 200 c.cm. of boiled 4% boric acid solution at 98.6° F.

For the after-treatment a Nélaton catheter is introduced through the urethra to which it is fastened by a silk thread carried through the frenulum, and the urine is permanently conducted through a rubber tube into a bottle filled with 5% carbolic acid (or 0.1% sublimate) solution, placed close to the bed. The catheter remains in place from one to two weeks until the healing of the bladder wound is assured. A drainage tube is inserted as far as the bladder through the skin, as usual through a separate small opening, and exceptionally allowed to remain for eight to ten days.

85. *Opening of the Bladder with Resection of the Symphysis.* —Where a large transverse incision does not afford sufficient room for operations in and upon the bladder, it is best to follow Helferich's procedure: after separating the attachments of the muscles (above, the abdominal recti and pyramidales; below externally, the obturatores externi) a triangular wedge with broad upper base and the point above the pubic arch is resected subperiosteally from the symphysis and the periosteum on the posterior surface properly detached. This manipulation does no further injury to the firmness of the pelvis. Dr. Niehans makes the symphyseal resection on one side only, but does it thoroughly.

P. Perineum.

The perineal region appears rather complicated anatomically, especially as regards the fasciæ.

Operations on the perineum are intended to expose the lowest part of the rectum, the urethra, the prostate and seminal vesicles, the vagina, the uterus, and the base of the bladder.

The operation which formerly occupied the foreground and furnished the most frequent indication was lithotomy.

86. Perineal lithotomy was looked upon as the normal procedure until quite recently, the only question having been the selection of the most appropriate method among its different varieties—lateral incision, bilateral incision, median incision. That the incision from below has been practised so long is to be explained by the fact that the infection of the wound in the high operation could not be prevented, while in the perineal operation at least the escape of the urine and the wound secretions could be provided for, so that their infiltration into the tissues would not increase the danger of infection.

At present the only definite indication for perineal lithotomy is in those rare cases in which small stones cannot be removed by lithotripsy, though they are too large to pass through the intact urethra.

In such cases the urethral incision is made in the membranous portion and the perineal incision coincides with external urethrotomy. The latter is performed, moreover, in lacerations, strictures, fistulæ, for digital exploration of the bladder, and finally for the removal of foreign bodies from the bladder and urethra. Other indications for the perineal incision are abscesses and neoplasms of the prostate and seminal vesicles.

Excepting the middle lobe which often projects into the bladder, the prostate is best made accessible from the perineum, and Dittel and Zuckerkandl have given minute directions for the operation. Diseases of the uterus are treated through the vagina, diseases of the rectum preferably through a posterior incision (see Surgery of the posterior pelvic region). Still, the prostate with the seminal vesicles can also be very well reached through this posterior incision beside and beyond the rectum.

87. *Opening of the Cavernous and Bulbous Portion of the Urethra. Median Incision.*—A median incision is made down to the fibrous albuginea of the corpus cavernosum. Unless the

latter requires opening or removal for disease, the urethra is reached beside the lateral circumference of the corpus cavernosum, especially beside the bulb, one of the wound margins being drawn aside.

88. *Opening of the Membranous and Prostatic Portion of the Urethra. Normal Incision for Giving Free Access* (Figs.

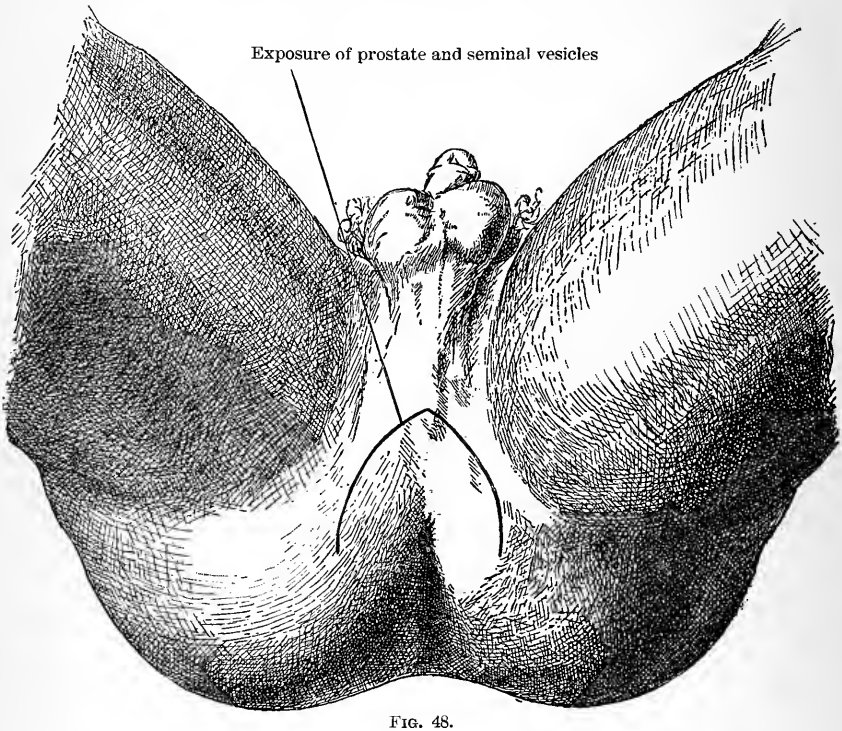

FIG. 48.

48 and 49).—This operation also gives access to the prostate, seminal vesicles, and the urethral extremity of the vasa deferentia. It requires a large external opening, hence the median incision is at once out of the question. A purely lateral incision, such as was formerly made by preference, divides the vessels and nerve twigs passing from the internal pudendal artery and nerve toward the median line (posteriorly the external hemorrhoidal arteries and nerves, anteriorly the perineal and bulbosa artery, with the nerves running parallel to them). Al-

though sacral resections have shown that the unilateral division of these nerves does not necessarily lead to permanent motor disturbances, still injury of these structures is to be avoided on principle, and the transverse curved incision is to be considered the normal procedure for giving free access.

The incision begins on the right between the tuber ischii and

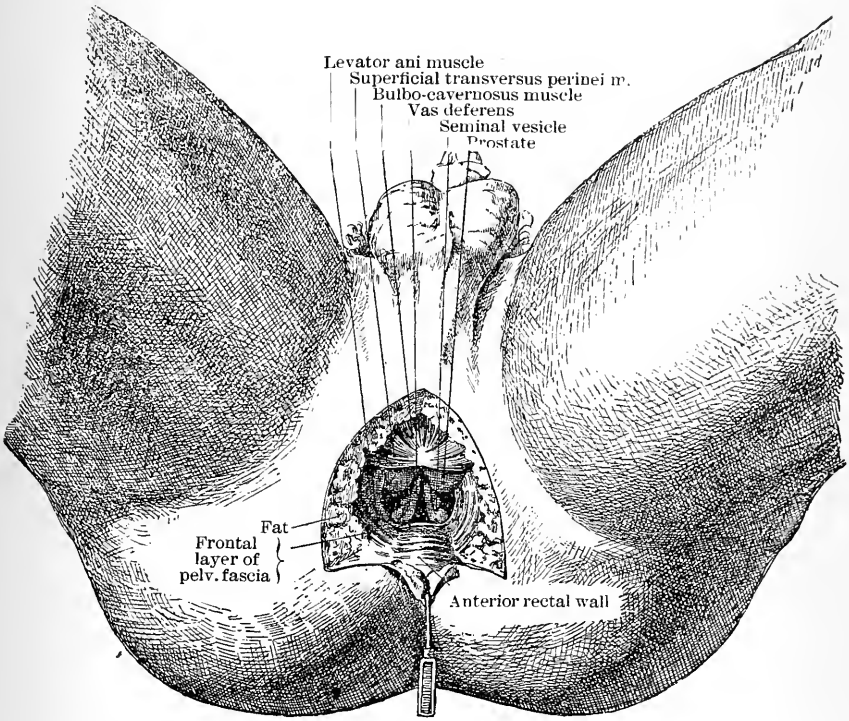

Fig. 49.

rectum, passes forward to the posterior end of the palpable bulbus urethræ, and symmetrically backward on the opposite side.

After dividing the skin and the superficial thin fascia, we reach the ischio-rectal excavation laterally in the adipose tissue between the pelvis and rectum. This is separated without cutting as far as the lower surface of the levator ani muscle. During this step the external hemorrhoidal nerve and artery are pushed or drawn backward, the perineal nerve and artery

(transversus perinei) and the bulbosa forward. Close to the bulb the connecting fibres between the external sphincter ani and the bulbo-cavernosus muscle are divided transversely and the bulbus urethræ is drawn forward. The superficial transversus perinei muscle remains in front. At the anterior surface of the rectum an organic muscle-fibre layer connects the bundles of the levator ani muscle transversely. This is covered by a fascia in front which rises to Douglas' pouch. At the point where this fascia joins the deep layer of the pelvic fascia over the bulb it is severed and drawn backward, together with the above-named muscular layer and the lower end of the rectum. In this way the posterior circumference of the urogenital diaphragm is exposed, namely, below the triangular urethral ligament, above the posterior broad margin of the deep transversus perinei muscle which covers the membranous portion of the urethra as far as the prostate.

Within the deep transversus perinei muscle Cowper's glands are situated, and may there be rendered accessible.

Working upward along the diaphragm without cutting, the fibres of the levator ani muscle, which run in the sagittal plane postero-inferiorly, are displaced to both sides, and thus we reach the smooth posterior surface of the prostate and higher up the seminal vesicles which can be made clearly visible. The latter are loosely united with the peritoneum and may be easily detached up to their upper end. Should the incision fail to give sufficient room, it can be lengthened backward on both sides, the sacro-tuberous ligament being severed at its attachment to the tuber ischii.

89. *Internal Pudendal Artery at the Perineum, and Internal Pudendal Nerve at the Perineum.*—Incision close to the easily palpable tuber ischii, passing along the medial border of the pubic arch forward through the skin. The fascia is divided, sparing the cutaneous branch of the pudendal nerve which passes to the scrotum. In the anterior portion the belly of the

ischio-cavernosus muscle is exposed. Close to its attachment the superficial transversus perinei muscle is severed at the ascending ramus of the ischium, and at the same time the deep layer of the fascia is divided which forms the inferior covering of the uro-genital diaphragm, and is reflected on the inner surface of the internal obturator muscle. The artery lies on the inner surface of the last-named muscle, passing forward above the attachment of the sacro-tuberous ligament; the internal pudendal nerve lies beside it and more superficially.

Q. Sacral Region.

Since the conviction has gained ground that, in those cases in which intra-peritoneal exposure of the pelvic organs is impossible or contra-indicated, access from behind is for various reasons preferable to that from the perineum, the surgery of the sacro-coccygeal region has acquired a greater interest.

90. The rectum in particular is often exposed from behind for the extirpation of neoplasms, but this way is also employed for reaching the upper part of the vagina, the uterus, the prostate, the base of the bladder, and the seminal vesicles.

The cutaneous incision (normal incision) begins at the side of the gluteal fold, usually the left, in the groove between the depressed sacrum and the prominence of the glutæus maximus, two fingers' breadth below the superior posterior iliac spine. It passes downward to the median line and along this to the tip of the coccyx at the posterior margin of the anus, eventually circling around the latter into the raphe of the perineum.

Along the sacrum the attachment of the glutæus maximus is severed and the edge of the bone laid bare. At the margin of the sacrum the ligaments and muscles are divided and we enter the depth by the side of the bone (Zuckerkandl, Wölfler). A better view is gained by the extirpation of the coccyx, accord-

ing to the method used by Verneuil for imperforate anus and employed by Kocher for the excision of the rectum. Where necessary a portion of the sacrum is likewise resected, either

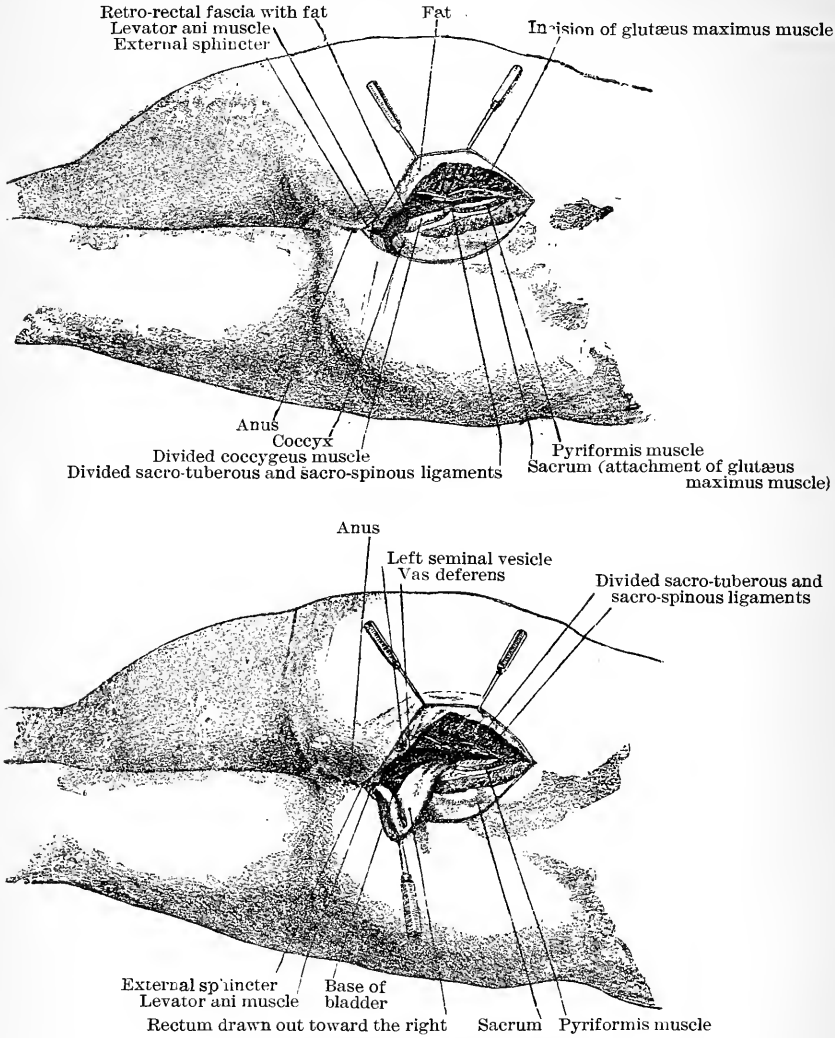

FIG. 50.—Parasacral Posterior Pelvic Incision.

the left margin only or a large piece as far as the fourth, third, or even the second sacral foramen according to Kraske's method. We may go, at least on one side, as far as the second sacral

foramen without causing permanent injury, although the nerves for the bladder and rectum are derived from the fourth and fifth sacral nerves and the internal pudendal from the third sacral.

If the bone is not resected, we sever at the left margin of the sacrum and on both sides of the coccyx the attachment of the tuberoso-sacral and spinoso-sacral ligaments; of the attachments of the muscles, from above downward, the pyriformis, the coccygeal, and ischio-coccygeal; below the tip of the coccyx the levator ani and sphincter ani. If the coccyx is removed, it is exarticulated with the resection knife; if a portion of the sacrum is resected, it is divided with a few powerful blows of the chisel and its lower end dissected out in its entire width in connection with the coccyx. This occasions often rather free hemorrhage, both from the divided bone and especially from the sacral arteries (sacralis media and lateralis), the former derived from the aorta, the latter from the hypogastric. As these vessels closely adjoin the sacrum they are at times hard to seize and to ligate, and a temporary tamponade must be resorted to. At the lowest part of the rectum the thick prominence (several centimetres high) of the external and internal sphincter ani with the median levator is to be divided if the anal portion is to be enucleated. Alongside of the rectum the levator ani muscle is divided to the raphe of the perineum; during this step some branches of the external hemorrhoidal artery (from the internal pudendal) will spirt.

For exposing the rectum higher up the main conditions are, first, the proper detachment of the connections with the anterior surface of the sacrum, of the sacro-coccygeal muscle and ligaments; second, the thorough division of the peritoneum in the region of Douglas' pouch, which in the male reaches down to the palpable upper margin of the prostate, in the female to the fornix vaginæ. After the peritoneum is divided the rectum can be so far withdrawn that a portion 20 to 25 cm. distant

from the anus may be stitched into the anal ring without using force. In freeing the rectum higher up, branches of the median hemorrhoidal artery (from the hypogastric) and of the internal hemorrhoidal artery (from the inferior mesenteric) must be ligated; the thickest branches lie laterally. After the fascia is severed and the vessels coming from the side and behind are

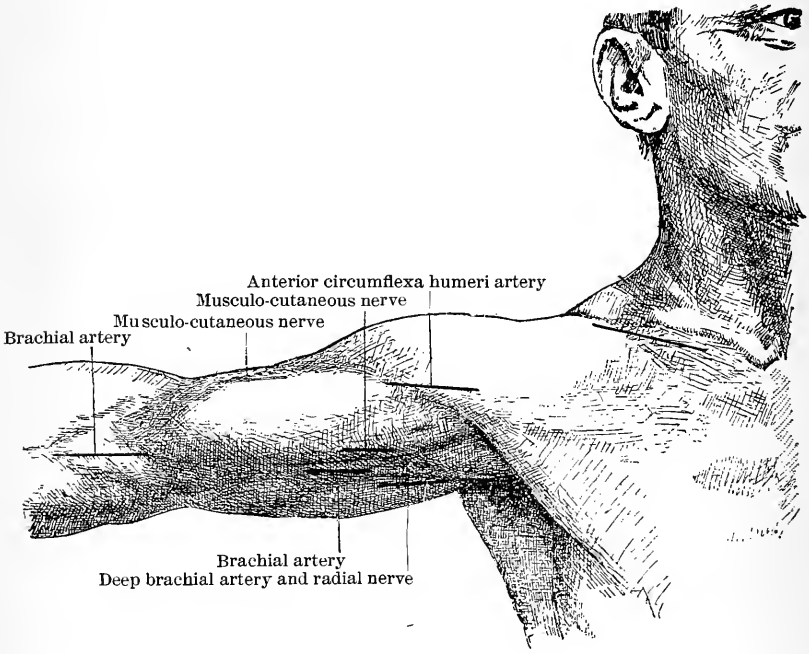

FIG. 51.

ligated, the rectum can be withdrawn from the wound with a large blunt hook, so that after dividing the frontal prerectal layer of the fascia the upper circumference of the prostate and the seminal vesicles with the inferior end of the vas deferens can be distinctly seen along with the base of the bladder. Near the upper end of the seminal vesicles in an outward direction the inferior extremity of the ureter can also be exposed.

R. Upper Extremity.

a. Shoulder Region.

91. *Subclavian Artery by Transverse Incision* (Figs. 51 and 52).—Incision 1 cm. below the middle third of the clavicle, dividing the fibres of the platysma with the sensory supra-

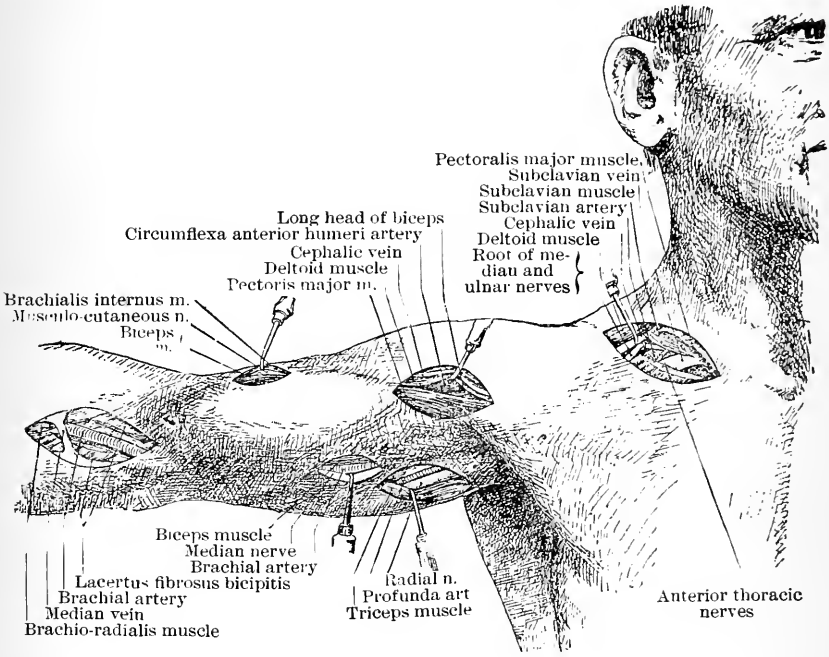

FIG. 52.

clavicular nerves. The cephalic vein at the anterior margin of the deltoid is to be preserved when the fascia is divided. The clavicular portion of the pectoralis major is severed to the margin of the deltoid. Beneath the clavicle the tense fascia of the subclavian muscle is divided and drawn down together with the cephalic vein which passes to the subclavian. The axillary plexus lies deeper and outward. Between the most medial nerve trunk (ulnar with cutaneus medius) and the vein lies the artery on the serratus anticus muscle.

92. Under the subclavian muscle the superior thoracic artery (Figs. 51 and 52) branches from the main trunk and at the same point the latter is surrounded by the motor branches to the pectoralis major and minor, namely, the anterior thoracic nerves.

Subclavian Artery by Longitudinal Incision (Fig. 36).—Incision upon the clavicle, beginning at the limit between the middle and outer third, extending in the palpable furrow be-

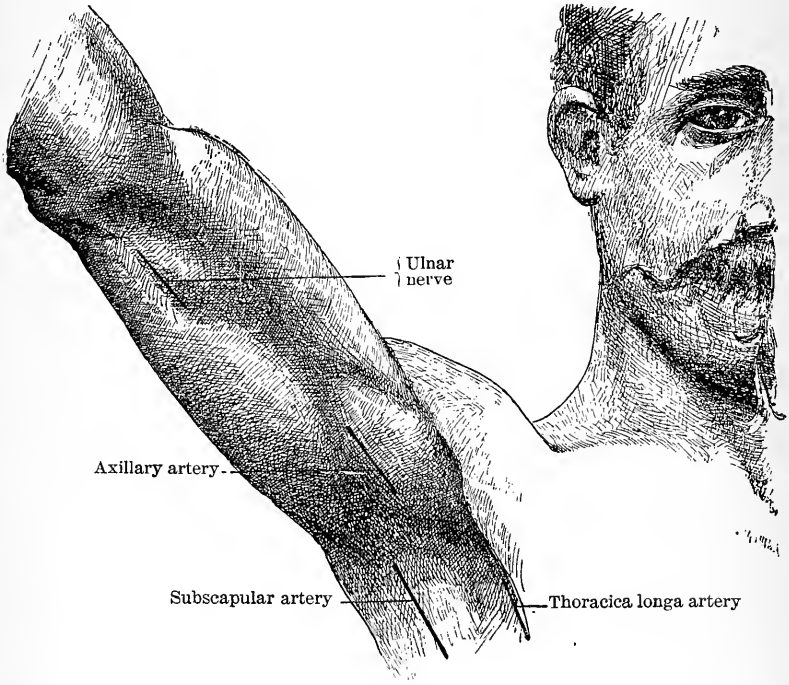

FIG. 53.

tween the deltoid muscle and the clavicular portion of the pectoralis major muscle toward the axillary fold. After the skin is divided the cephalic vein appears in the fascia and is drawn to the medial side if the artery is to be ligated close under the clavicle. But this has the drawback that a point is exposed where the important anterior thoracic nerves pass from without and above over the artery in their course to the pectoral muscles.

Where the choice is free, therefore, the cephalic vein is drawn laterally upward. Under its terminal portion, *i.e.*, before it empties into the subclavian vein, lies the artery and laterally from it the nerve trunks of the axillary plexus.

93. Under the upper margin of the pectoralis minor muscle below which the artery passes we strike the point where the thoracico-acromial artery is given off (Fig. 36), whose branches lie in front of the main artery.

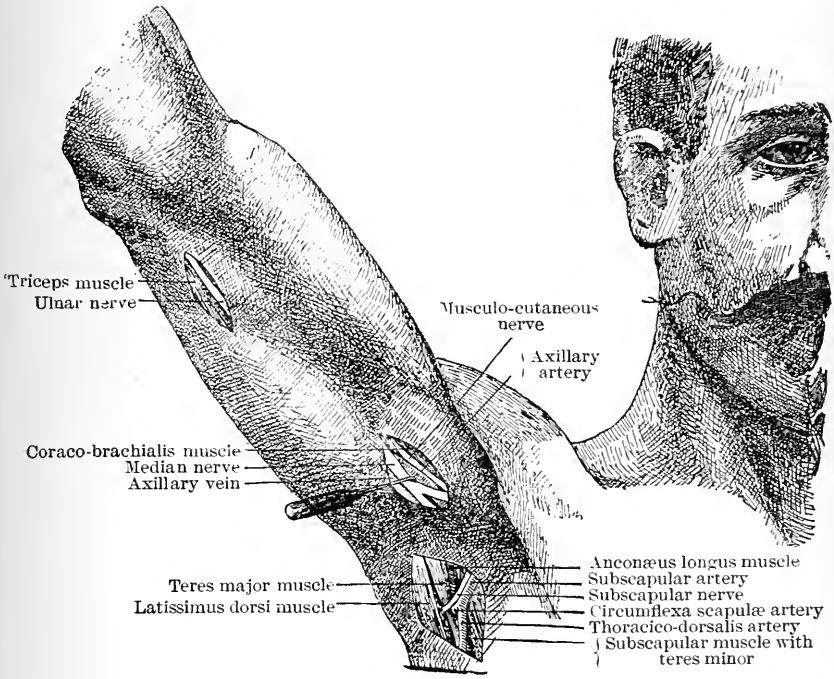

FIG. 54.

Detachment of the pectoralis major for a short distance along the clavicle facilitates the operation.

94. *Long Thoracic Artery* (Fig. 53).—Incision along the anterior axillary fold, the arm being abducted, beginning at the lateral surface of the thorax. After the fascia is divided the artery is found directly behind the margin of the pectoralis major, passing down the thorax or the serratus an-

ticus major in the axillary line. Behind it lies the long thoracic nerve.

b. Axilla.

95. *Axillary Artery* (Figs. 53 and 54).—Direction from the middle of the clavicle to the middle of the anterior axillary fold. It lies on the lateral wall of the triangular prismatic space between the thoracic wall interiorly (serratus anticus major), pectoralis major and minor anteriorly, and scapula (subscapular muscle) posteriorly. Incision through skin and fascia in the prolongation of the internal bicipital sulcus, extending upward at the inner margin of the muscular prominence of the coraco-brachialis which appears under the pectoralis major toward the arm. The belly of the coraco-brachialis is exposed. The axillary plexus, which is palpable even through the skin on the rounded eminence of the head of the humerus, is in sight. We pass between the two most lateral nerve trunks. The thinner external one of these is the musculo-cutaneous, the thick medial one is the median; sometimes only the latter is visible. Higher up the median consists of two parts, the lateral one of which unites with the musculo-cutaneous nerve. The artery lies in the fork between the two roots of the median. The ulnar nerve lies in a median direction from the vessel; the radial nerve posteriorly; the chief vein quite anteriorly; a smaller collateral vein exteriorly from the artery.

96. *Anterior Circumflex Artery* (Figs. 51 and 52).—Incision at the anterior margin of the deltoid at the point where the finger can be pressed in upon the surgical neck of the humerus. On the fascia lies the cephalic vein. It is important for determining the furrow between the deltoid and pectoralis major. After dividing the fascia the muscles are separated from each other without cutting, the former being drawn outward, the latter inward. The short head of the biceps with the coraco-brachialis, which, coming from above, passes under the

pectoralis, is freed on its lateral side and drawn in a median direction. We enter between it and the long biceps tendon. The artery runs transversely, adjoining the bone close under the rounded head, above the attachment of the pectoralis.

97. *Posterior Circumflex Artery and Axillary Nerve* (Figs. 55 and 56).—Palpation at the posterior margin of the deltoid muscle toward the surgical neck of the humerus will distinctly feel the angle, open below, formed by that muscle with the posterior scapular muscles or the teres minor.

After dividing the skin and the fascia which adheres rather firmly to the deltoid, the margin of the latter is freed and drawn upward, then upward and backward the lower margin of the teres minor is exposed above the teres major and latissimus muscles lying in the posterior axillary fold. In the angle formed by the margins of the teres minor and deltoid the tissues are separated without cutting toward the bone, the long head of the anconæus which projects under the teres minor being left in the rear. First appears the thick axillary nerve which gives off a cutaneous branch downward along the margin of the deltoid. Below we strike the posterior circumflex artery which passes from the space between the teres major and minor, and whose branches pass up and down.

98. *Subscapular Artery and Nerves* (Figs. 53 and 54).—Incision on the arm, beginning along and above the posterior axillary fold, the arm being strongly abducted. On the fascia, intercostal roots of the internal cutaneous nerve may appear. After the fascia is divided, the artery becomes visible at the upper margin of the latissimus dorsi muscle (which forms the posterior axillary fold with the teres minor), in the loose adipose tissue. The trunk is short.

99. The continuation of the trunk toward the thorax is the thoracico-dorsalis artery, accompanied by the thick subscapular nerves which come from above.

100. The other main branch is the circumflexa scapulæ

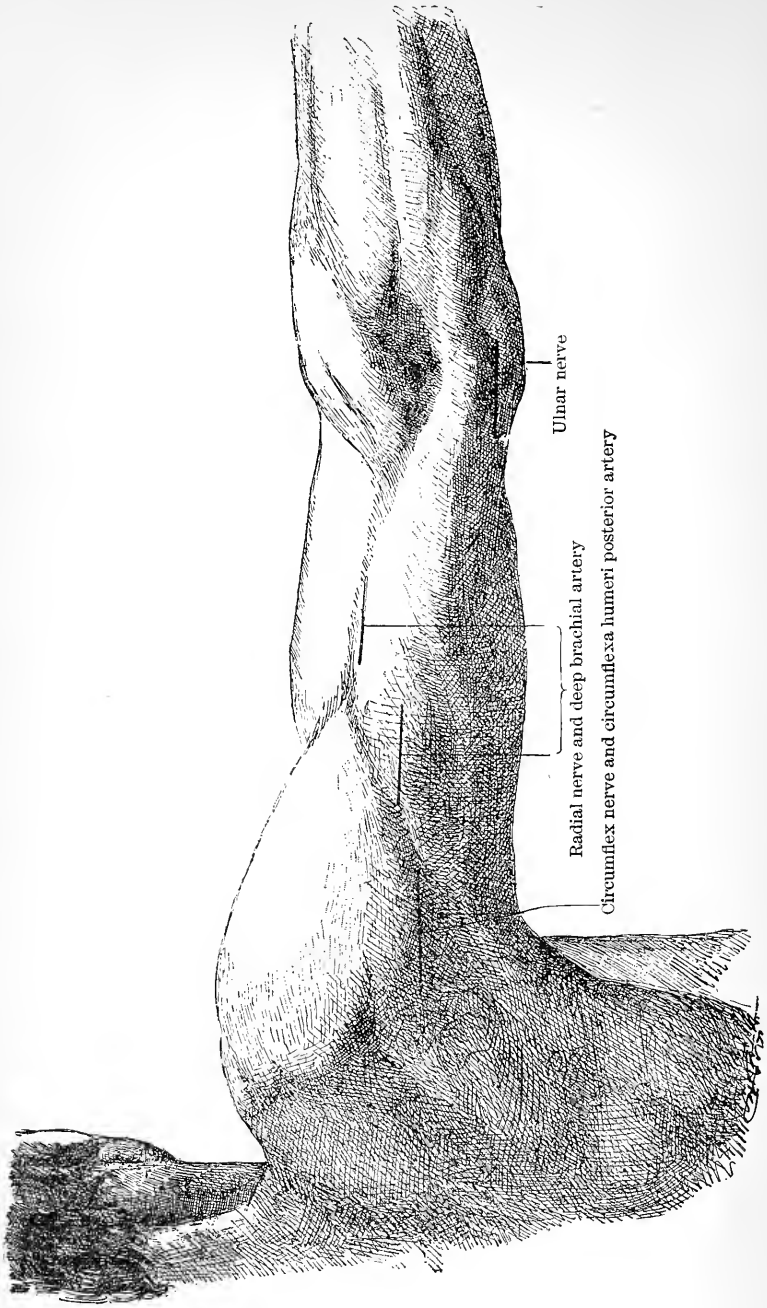
Ulnar nerve
Radial nerve and deep brachial artery
Circumflex nerve and circumflexa humeri posterior artery

Fig. 55.

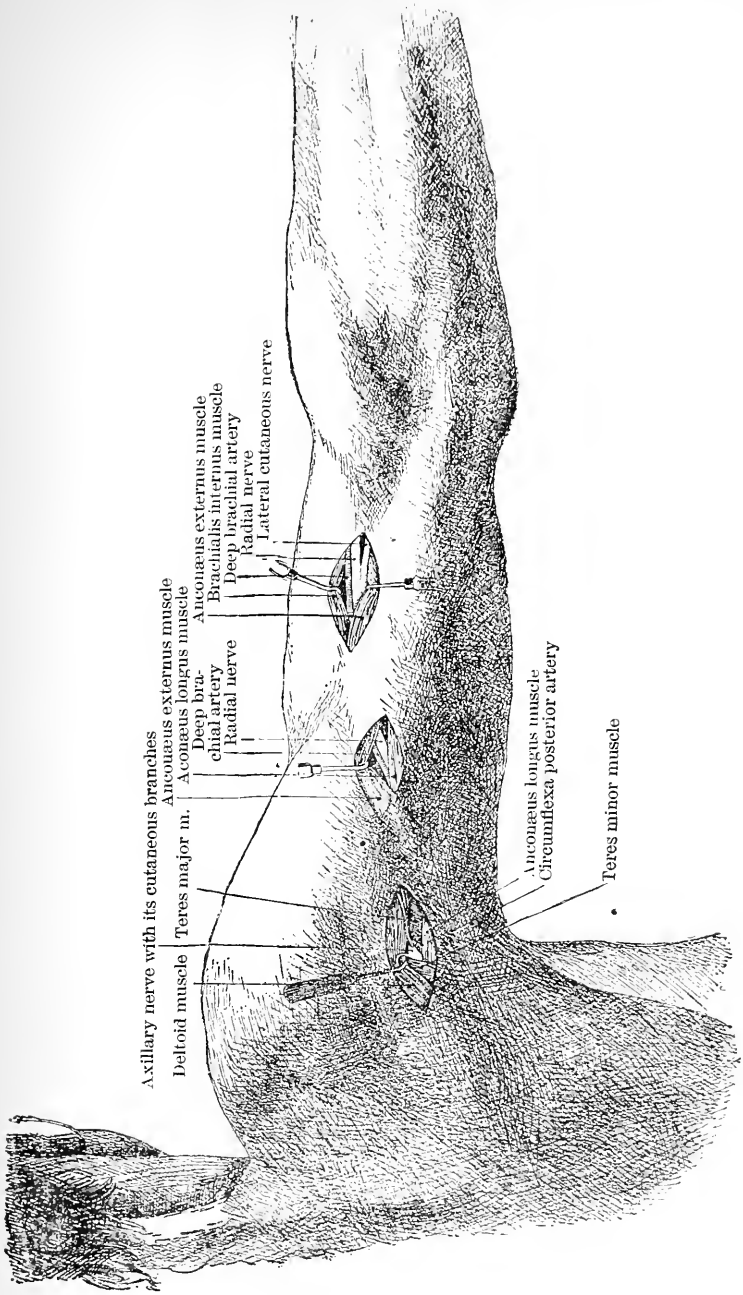
Axillary nerve with its cutaneous branches
Deltoid muscle
Teres major m.
Anconæus externus muscle
Anconæus longus muscle
Deep brachial artery
Radial nerve
Anconæus externus muscle
Brachialis internus muscle
Deep brachial artery
Radial nerve
Lateral cutaneous nerve
Anconæus longus muscle
Circumflexa posterior artery
Teres minor muscle

FIG. 56.

artery which passes backward between the latissimus (with teres major) and subscapular muscles on the medial side of the anconæus longus muscle.

c. *Arm.*

The brachial artery may be felt in the internal bicipital sulcus through the entire length of the arm, below the equally palpable median nerve which crosses the artery in the middle from without inward, passing over it. The artery can be compressed in its entire length against the biceps.

101. *Brachial Artery at its Middle* (Figs. 51 and 52).—Incision upon the cord of the median nerve which can be distinctly felt in the internal bicipital sulcus when the arm is abducted. On the fascia is the thin internal cutaneous nerve. The fascia is divided to expose the belly of the biceps muscle which is drawn laterally. The median nerve is completely exposed and *separately* drawn in a median direction. Immediately beneath is the brachial artery in front of the intermuscular ligament at the bone, with the two concomitant veins. Near its median side is the middle cutaneous nerve.

Below the middle of the arm the basilical vein enters the brachial and the middle cutaneous nerve passes through the fascia. These structures can be exposed by the same incision as for the ligation of the brachial artery.

102. *Deep Brachial Artery on the Outer Side of the Arm below the Middle* (Figs. 55 and 56).—Incision at the outer margin of the prominence of the aconæus externus muscle which can be readily located by being grasped from behind, passing downward at the humerus from the attachment of the deltoid. The body of the anconæus muscle is exposed by an incision behind the strip of fascia which indicates the external intermuscular ligament and the muscle is detached from the latter ligament as far as the bone. The artery comes forward obliquely from behind; beside it close to the bone is the radial nerve.

On the Dorsal Surface of the Arm above the Middle. See Exposure of the radial nerve at the same point (Figs. 55 and 56).

On the Inner Side of the Arm in the Upper Third (Figs. 51 and 52).—Incision in the internal bicipital sulcus from the height of the posterior axillary fold downward through skin and fascia. The latter is divided on the prominence of the anconæus longus muscle behind the white streak of the internal intermuscular ligament. Along the anterior surface of the last-named muscle we proceed toward the bone behind the attachment of the anconæus internus to the humerus. The first to appear is the profunda artery which gives off a downward branch to the internal head of the triceps (collateralis media artery).

Somewhat deeper lies the radial nerve which, descending from above over the tendon of the latissimus, passes between the anconæus internus and longus muscles toward the dorsal surface of the humerus.

The superior collateral ulnar artery comes within the same incision. It arises some distance below the profunda and runs in the internal bicipital sulcus behind the large vascular and nerve trunks.

The terminal branch of the deep brachial (the collateral radial artery) may be felt on the base of the external condyle of the humerus in the furrow between the brachialis internus and brachio-radialis and is to be there ligated behind the radial nerve.

103. *Superior Collateral Ulnar Artery.*—For its ligation in the upper third of the upper arm see Ligation of the deep brachial.

At the lower end the artery can be felt on the dorsal surface of the internal condyle and should be looked for beside the ulnar nerve behind the internal intermuscular ligament.

104. *Inferior Collateral Ulnar Artery.*—The artery lies on the base of the internal condyle above the projection marking

the attachment of the pronator teres, and can there be felt. It is found after dividing the tense fascia which carries a main branch of the median cutaneous nerve and the junction of the basilical vein with the median.

105. *Median Nerve* (Figs. 51 and 52).—See Ligation of the brachial artery. The nerve in the upper half lies on the external, in the lower half on the internal side of the artery and more superficially.

106. *Ulnar Nerve* (Figs. 53 and 54).—Incision in a line ascending vertically from the internal condyle at the anterior margin of the belly of the triceps. Division of the fascia behind the white streak marking the attachment of the intermuscular ligament exposes the body of the triceps and at the same time the rather superficial nerve, behind the above-named ligament.

107. *Radial Nerve. In the Lower Third of the Arm* (Fig. 57).—Incision at the anterior margin of the brachio-radialis muscle. The fascia of the latter is divided and we penetrate without cutting along the margin of the muscle to the bone. On the outer side of the brachialis internus muscle lies the nerve which toward the elbow joint is already divided into the superficial and the deep branch, the latter resting on the bone, and both are in front of the external intermuscular ligament.

Below the Middle of the Arm on the Lateral Surface (Figs. 55 and 56).—Incision in a line ascending vertically from the external condyle at the lateral margin of the belly of the triceps below the attachment of the deltoid to the humerus; the triceps is exposed (external head) and we penetrate at its margin toward the outer surface of the humerus, laterally from the brachialis internus muscle. The nerve adjoins the bone; on its external radial side the deep brachial artery runs parallel to the main trunk; behind it is the inferior cutaneous radial nerve.

Above the Middle on the Dorsal Surface (Figs. 55 and 56).—Incision in a line ascending vertically from the tip of the olec-

ranon on the dorsal surface of the arm between the posterior margin of the deltoid and the easily detached prominence of the long head of the triceps. At the lateral margin, after division of the fascia, we penetrate toward the bone, the fingers separating the two above-mentioned heads of the triceps. The nerve lies between them.

In the Upper Third on the Medial Side (Figs. 51 and 52).—See Ligation of the deep brachial artery in the internal bicipital sulcus.

108. *Musculo-cutaneous Nerve. Below the Middle of the Arm* (Figs. 51 and 52).—Incision at the outer margin of the belly of the biceps, the cephalic vein being preserved; the fascia is divided as far as the body of the biceps, and the finger is insinuated behind the inner surface of the latter. The nerve lies under the thin fascia of the brachialis internus. Care should be taken lest the outer margin of the brachialis internus be exposed instead of that of the biceps.

Above the Middle of the Arm (Fig. 51).—Incision in the internal bicipital sulcus. The body of the biceps is laid bare and the muscle drawn laterally. The nerve lies at the lateral margin of the coraco-brachialis muscle through which it has passed so as to reach the anterior surface of the brachialis internus muscle.

d. Elbow Region.

109. *Brachial Artery in the Bend of the Elbow* (Figs. 51, 52, and 57).—Incision midway between the two condyles, somewhat nearer to the ulnar side, at the medial edge of the biceps tendon. On the fascia are the oblique median vein and the cutaneous branches of the median cutaneous nerve.

Under the thin fascia the characteristic fibres of the aponeurotic bicipital fascia, passing obliquely downward toward the ulna, become visible and are divided in the direction of the cutaneous incision. Immediately beneath, the artery lies im-

bedded in the fat accompanied by two veins. The biceps tendon lies laterally.

110. *Median Nerve* (Fig. 57), 0.5 cm. in a median direction at the lateral margin of the pronator teres muscle. The brachialis internus muscle supports the bundle of vessels and nerves. In performing this ligation we must remember that

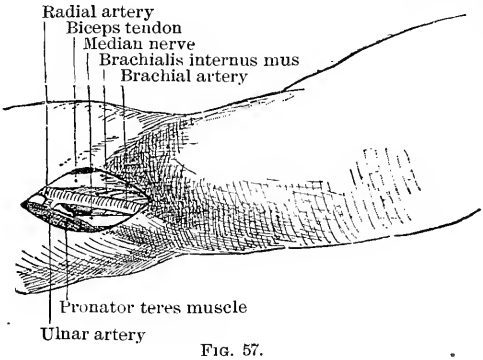

FIG. 57.

the artery descends from the internal bicipital sulcus, hence not to penetrate into the depth on the lateral side of the biceps tendon. The brachial artery divides into the radial and ulnar a finger's breadth below the line of the joint.

111. *Ulnar Nerve* (Fig. 55).—Incision from behind upon the base of the internal condyle; closely adjoining this subfascially lies the thick nerve, descending between both attachments of the internal ulnar muscle to the condyle, and passing at the olecranon to the flexor profundus.

112. *Radial Nerve* (Figs. 58 and 59).—At the elbow joint the radial nerve, together with its deep branch, lies in the furrow between the brachio-radialis and brachialis internus muscles. Incision in the prolongation of the external bicipital sulcus at the anterior margin of the belly of the brachio-radialis in the bend of the elbow. The cephalic vein is drawn down. After the fascia is divided we strike beside the biceps tendon the musculo-cutaneous nerve which pierces the fascia so as to furnish the sensory supply to the radial anterior side of the

forearm. If we penetrate at the external margin of the brachialis internus muscle we reach on the bone the superficial and deep branch of the radial nerve, one behind the other, and beneath them the terminal branch of the collateral radial artery.

e. Forearm—Volar Surface.

113. *The Radial Artery* (Figs. 58 and 59) forms the straight continuation of the brachial artery; for two-thirds of its length it can be readily felt, is nowhere covered by muscles, and only in the upper third is the brachio-radialis drawn over it by the fascia. The direction of the artery is determined by a line from the middle of the bend of the elbow to the point where the pulse is felt, or below this to the prominence of the trapezium. This line at the same time marks the limit of the muscular branches of the median and radial nerves at the forearm.

In the Lower Third.—The hand being hyperextended, the incision is made between the prominent tendon of the internal radial muscle and the margin of the radius or the tendon of the brachio-radialis. Skin and fascia are divided; the artery lies immediately under the fascia between two veins upon the pronator quadratus muscle. The superficial branch of the radial nerve is no longer visible, as it passes dorsad under the tendon of the brachio-radialis muscle at the lower third of the forearm.

In the Middle.—Incision between the muscular prominences of the radialis internus and brachio-radialis muscles which rise on both sides. In the furrow lies the artery on the radial attachment of the flexor pollicis longus muscle. On its radial side is the superficial branch of the radial nerve.

In the Upper Half.—The artery lies more deeply on the radius because the muscular prominences of the brachio-radialis and the radialis internus are no longer present. Incision in the distinctly palpable furrow between these muscles. On the fascia appear the cephalic vein and a thick branch of the mus-

culo-cutaneous nerve. The fascia is divided. The brachio-radialis muscle is to be well drawn aside in a radial direction, and the artery lies deep upon the radial attachment of the pronator teres. To the radial side of the artery lies the superficial (sensory) twig of the radial nerve.

114. *Ulnar Artery* (Figs. 58 and 59).—It can be felt in the lower half because the greater portion is not covered by muscles; above, after being given off at an angle from the brachial artery, it lies between the deep muscles, namely, the flexor digitorum sublimis and profundus. The line indicating the cutaneous incisions for its ligation passes from the internal condyle of the humerus to the prominence of the pisiform bone. The line does not correspond to the position of the artery which lies more toward the median line, especially above.

In the Lower Half.—Incision in the furrow between the internal ulnar muscle and the flexors; this furrow is well marked in the vertical prolongation from the medial margin of the pisiform bone upward. Skin and fascia are divided; we penetrate toward the bundle of flexors, not under the internal ulnar muscle. The artery lies between two veins. The ulnar nerve is close to its ulnar side.

In the Upper Half.—Incision in the above-mentioned line at the margin of the internal ulnar muscle which is limited by a palpable furrow. Occasionally the ulnar nerve can be felt through the skin. After the skin is divided, we strike the basilical vein with a branch of the cutaneus medius nerve on the fascia. In the latter the interstice between the internal ulnar and the palmaris longus muscles above, and the flexor sublimis below, is marked by a distinct white streak. When the fascia is severed along this streak the finger penetrates without cutting alongside the internal ulnar muscle to the flexor digitorum profundus, the flexor sublimis being pushed aside. If we are in the true interstice between the two last-named muscles we come first upon the thick ulnar nerve. We pass

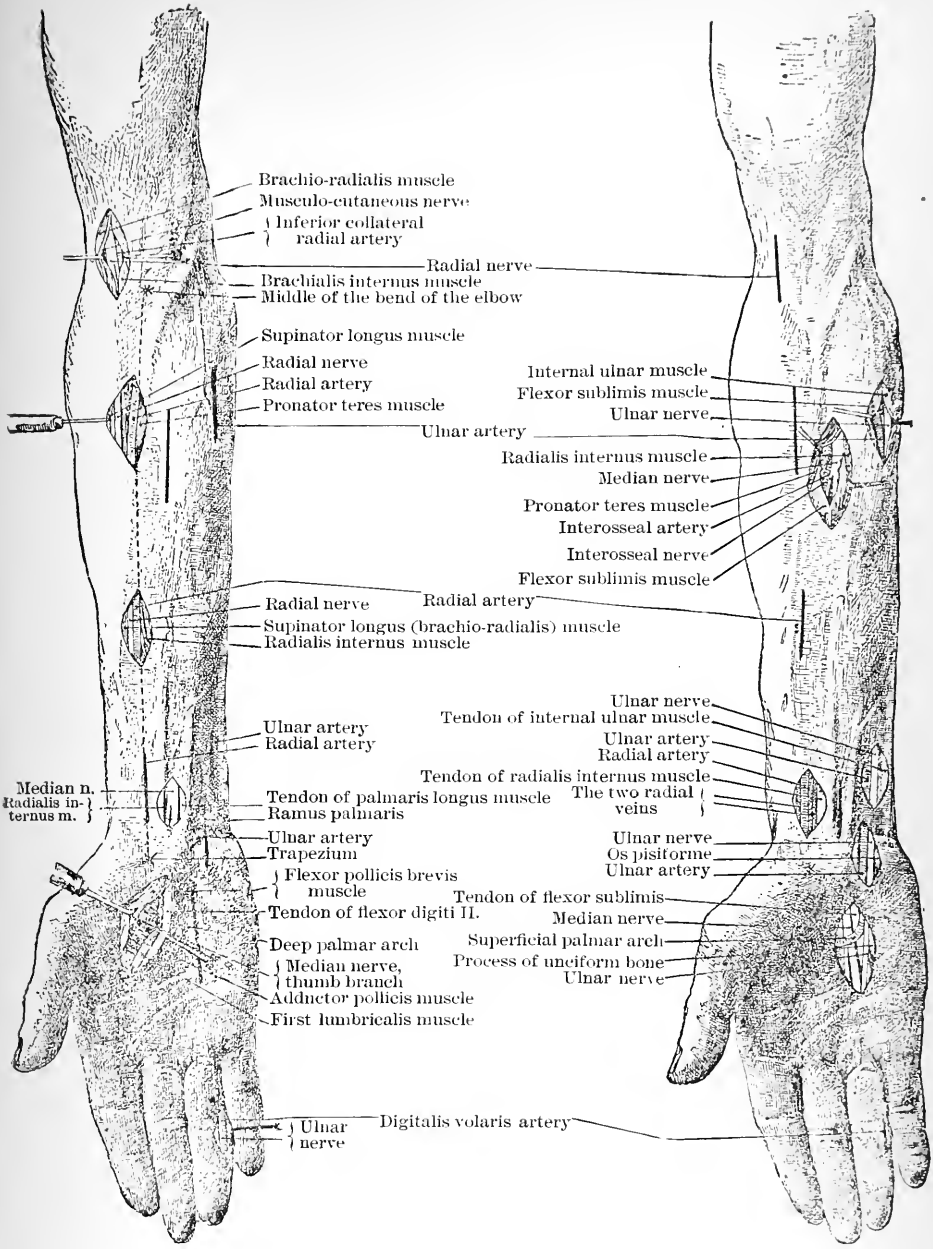

Fig. 59. Fig. 58.

Figs. 58 and 59.—Arteries and Nerves of the Forearm and Hand.

laterally in front of the nerve because it supplies branches to the muscles beneath (internal ulnar and flexor profundus). Toward the upper end the artery lies more medially from the nerve.

115. *Interosseal Artery* (Figs. 58 and 59).—This branch of the ulnar artery can be exposed through the same incision as that for the ulnar artery in the upper third, by passing in a median direction from the flexor profundus muscle until the median nerve with its branches is found. Below the latter the interosseal artery passes toward the interosseous ligament between flexor profundus and flexor pollicis longus. Upon it lies the interosseous branch of the median nerve. The interosseal artery can also be exposed by the incision for the interosseus nerve just named (see Fig. 58).

116. *Median Nerve* (Figs. 58 and 59). *Above the Wrist Joint.*—Incision through the skin between the tendon of the internal radial muscle and the palmaris longus; close above the wrist joint we expose the point of perforation of the

117. *Cutaneus palmaris nerve* (from the median); the upper part of the latter, together with the trunk of the nerve, lies under the fascia of the deeper muscular layer.

In the Middle.—Incision in the middle of the forearm at the radial end of the internal radial muscle, in the interstice toward the brachio-radialis muscle. The internal radial muscle is drawn toward the ulna. In the furrow appears first the radial artery and at its ulnar side we strike the flexor digitorum sublimis muscle, whose radial margin is laid bare and drawn vigorously to the ulnar side. The thick nerve becomes visible on the digitorum profundus muscle, accompanied by an artery.

In the Upper Third.—Incision at the radial margin of the internal radial muscle in the deep furrow toward the brachio-radialis. Toward the ulna, beside the radial artery there exposed, we strike the pronator teres muscle which is drawn upward or divided.

The nerve is now laid bare, above the point where it passes under the tendon of the flexor digitorum sublimis muscle; below, the radial attachment of this muscle must be severed from its main body so that the latter can be drawn toward the ulna. The median nerve rests on the flexor profundus. The same incision exposes:

118. *The Interosseus Nerve* (from the Median). It lies more deeply on the interosseous ligament, in the furrow between the flexor digitorum profundus and flexor pollicis longus muscles. The interosseus nerve supplies the last-named muscle and farther down the pronator quadratus. Beneath the interosseus nerve lies the interosseal artery (branch of the ulnar artery).

Deep Incisions on the Volar Side of the Forearm.—Bearing in mind the course of the radial artery and nerve on the one side, and the interosseal artery and nerve on the other side, we can penetrate on the radial side of the median throughout the entire length to the interosseal ligament and the radius without danger of causing any serious incidental injury, since this is the border line between the two nerve distributions. On the interosseal ligament we not rarely find deep abscesses due to extension of inflammations of the tendinous sheaths of the hand, requiring free and deep incisions.

f. Forearm—Dorsal Surface.

119. *Deep Branch of the Radial Nerve* (Figs. 60 and 61). —Incision on the dorsal surface at the margin of the eminence of the brachio-radialis and the radiales externi, extending between these muscles and the extensor digitorum communis in a line vertically downward on the radial side from the head of the radius which can always be distinctly felt. The fascia is divided and the oblique attachment of the extensor digitorum communis is drawn backward and that of the radialis externus longus muscle forward. The characteristic oblique fibres of the

supinator brevis muscle are thus laid bare. When these are divided, the nerve is exposed a thumb's breadth below the joint, descending from the volar to the radial and dorsal side. Some of its longer branches pass between the extensor communis and radiales externi on the dorsal surface of the radius to the tendons of the abductor and the flexors of the thumb.

Incisions on the dorsal surface of the forearm, whose muscles are supplied by the radius, may be made over the whole limb along the ulna; also along the radial margin of the external ulnar muscle which adjoins the ulna and receives its nerve supply high up. On the radial side incisions are admissible in a line from the head of the radius to the styloid process of this bone, *i.e.*, from the point where the radial nerve pierces the supinator brevis, downward between the external radial muscles and the extensor digitorum communis. In the lower half, where the external radial muscles pass under the oblique thumb muscles, the incisions must be made upon the radius, between the thumb muscles and the tendon of the brachio-radialis muscle. In an ulnar direction from the thumb muscles, in the lower half of the forearm, incisions can be made between all the tendons of the dorsal surface, as no larger vessels and nerves need be feared there.

g. Wrist Joint—Volar Side.

120. *Ulnar Artery at the Pisiform Bone* (Figs. 58 and 59). —Its pulsation can always be distinctly felt here. Furnishing the main supply of the superficial volar arch, the artery requires ligation in hemorrhages at this point which resist other measures.

Incision 5 mm. in a radial direction from the distinctly palpable prominence of the pisiform bone, extending through the skin and the common volar ligament of the wrist. The artery lies in a cushion of fat on the ligamentum carpi volare pro-

prium. The thick ulnar nerve adjoins it toward the pisiform bone.

121. *Median Nerve* (Figs. 58 and 59).—Incision in the palm where the thenar and hypothenar eminences join, extending through the skin and the fascia of the thick ligamentum carpi volare proprium. The nerve lies flat on the common mucous sheath of the flexors and divides into two terminal branches: the first going to the muscles of the thenar excepting the adductor, and to three finger margins at the thumb and index finger; the second, to two lumbricales and four more finger margins.

h. The Hand—Dorsal Side.

On the dorsum of the hand a line from above the centre of the middle finger upward to the wrist divides the distribution of the radial and ulnar nerves. The arterial dorsal arch and its intermetacarpal twigs are relatively unimportant vessels. In incisions, therefore, the tendons require the most attention. The extensor tendons at the wrist joint have to a great extent separate mucous sheaths down to the middle of the metacarpus.

122. *Radial Artery on the Dorsum of the Hand* (Figs. 60 and 61).—Main supply of the deep volar arch. Incision at the most posterior palpable end of the intermetacarpal space between thumb and index finger, along the ulnar side of the tendon of the extensor pollicis longus. On the fascia, twigs of the dorsal branch of the radial nerve and the cephalic vein must be preserved. Passing between the bases of the above-named metacarpal bones we strike the artery on the transverse ligament uniting them. Peripherally from the artery is the first interosseus muscle. A common digital branch for the index finger and thumb, given off by the artery, is very apt to be mistaken for it.

123. *Radial Artery on the Trapezium* (Figs. 60 and 61).—Longitudinal incision from the lower end of the radius to

the base of the first metacarpal bone, between the tendons of the extensor pollicis longus and brevis muscles. In the subcutaneous tissue we must preserve the cephalic vein running parallel to the tendons and the dorsal radial nerve which can be felt upward on the radial side of the radius. In an oblique direction from the course of these structures and the tendons the artery lies under the fascia upon the joint capsule and bone.

Dorsal Branch of the Ulnar Nerve (Figs. 60 and 62).—This can be distinctly felt on the ulnar side of the unciform. It is exposed by a longitudinal incision extending from the lowest point of the ulna downward on the ulnar side, and lies upon or in the fascia, passing dorsad under the internal ulnar muscle.

Dorsal Branch of the Radial Nerve (Figs. 60 and 61).—This is exposed by the same incision as that for the radial artery on the trapezium (which see). It can be felt through the skin on the radial side of the lower end of the radius, after it has taken a dorsal direction at the lower third of the forearm under the tendon of the brachio-radialis muscle.

i. The Palm of the Hand.

In the palm the vessels and nerves run in the direction of the interstices of the fingers, the tendons in the direction of the fingers, all under the tense superficial palmar fascia.

The latter with its processes (ligamenta vaginalia) accompanies the tendons to the fingers, but between them ends in curves, concave below, which are attached by septa to the ligamenta capitulorum metacarpi, so as to separate the tendons with the muscles from the vessels and nerves.

Above the muscles of the thumb and the hypothenar eminence the superficial layer of the palmar fascia coalesces with the deep layer.

Under the palmar fascia the bundle of flexor tendons with the lumbrical muscles lies in a mucous sheath which extends

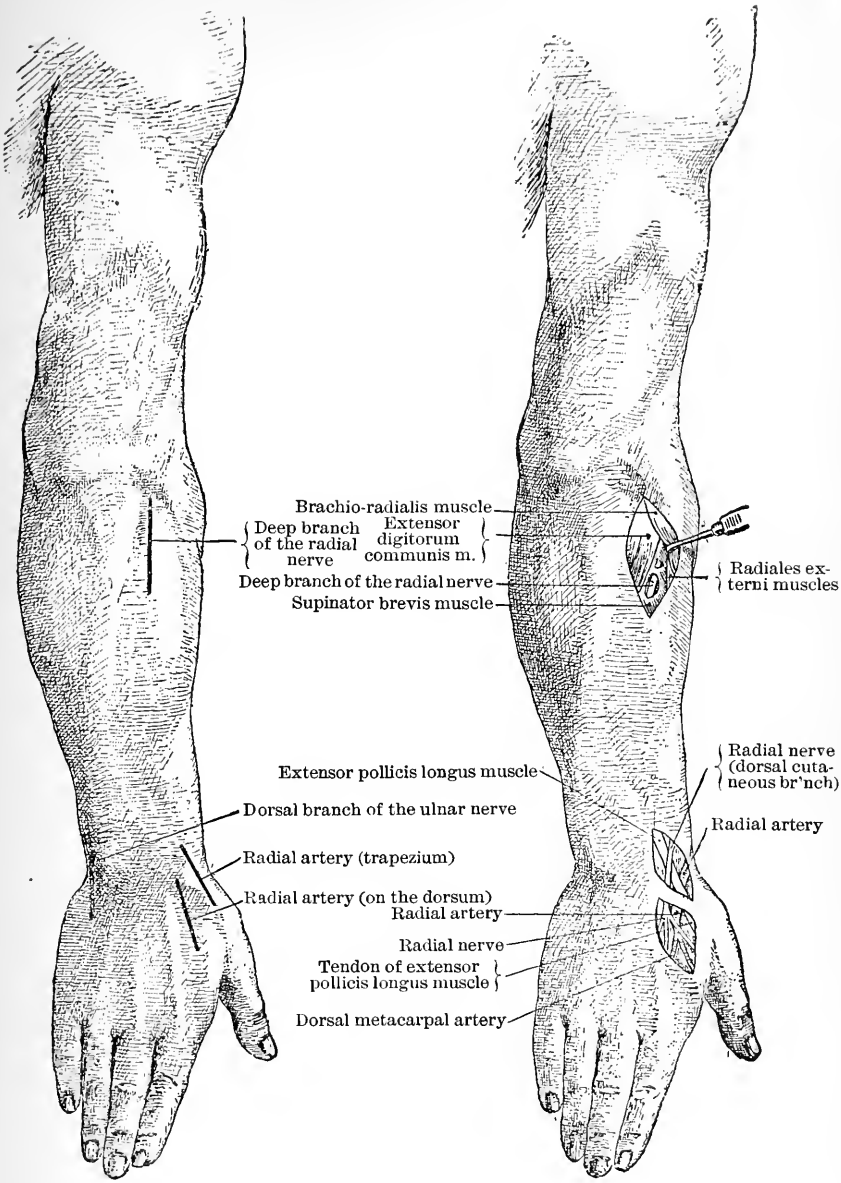

FIG. 60. FIG. 61.

FIGS. 60 AND 61.—Dorsal Radial Artery, Radial Nerve with Branches. Dorsal Ulnar Nerve.

from the ends of the forearm bones to the base of the metacarpus. The flexor pollicis longus has a separate sheath. Under the bundle of tendons is the thinner deep fascia, covering the interosseus muscles and the bones.

The guiding-points around the wrist are the following: The os pisiforme with the attachment of the internal ulnar nerve, the proximity of the palpable ulnar vessels and nerve on its

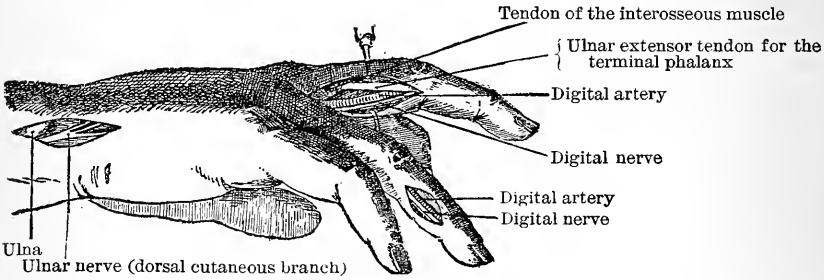

FIG. 62.

radial side; on the ulnar side of the wrist under the os pisiforme the projecting body of the unciform; a thumb's breadth downward and somewhat radially from the os pisiforme in the palm the process of the unciform, under which are the deep palmar arch and the deep branch of the ulnar nerve; immediately above the thenar the prominence of the trapezium across which passes the branch of the radial artery to the superficial volar arch. The wrist joint has for its fascia a transverse thickening of the common fascia (ligamentum carpi commune dorsale and volare) and a deep fascia on the joint capsule; besides, on the palm, the stout ligamentum carpi volare proprium which keeps the tendons in the groove of the carpal bones and from which springs a portion of the thumb muscles.

126. *Superficial Volar Arch* (Figs. 58 and 59).—Longitudinal incision from the junction of the thenar and hypothenar eminences, extending toward the fourth finger; its middle should be in the transverse line of the fold between the hand and the abducted thumb. At the intersecting point of the two lines the

arch can be felt pulsating. After dividing the skin and the stout tendinous palmar fascia, the arch (imbedded in fat) becomes at once visible under the smooth inferior surface of the latter. The arch forms the continuation of the ulnar artery and here begins to curve toward the side of the thumb. The thick common digital arteries spring from its distal portion. The arch rests upon the longitudinal digital branches of the ulnar (these become visible) and median nerves. If the artery cannot be found, the ulnar artery must be ligated at the os pisiforme.

The ulnar nerve is to be exposed by the same incision; the superficial branch passes downward over the palpable process of the unciform; the deep branch passes into the depth between the abductor and flexor brevis at the ulnar side of the process and supplies the flexor brevis and opponens digiti minimi, two lumbricals, and all the interossei with the adductor pollicis.

127. *Deep Volar Arch* (Figs. 58 and 59).—This arch, contrary to the superficial, springing mainly from the radial artery, gives off large vessels to the lateral margins of the hand, while its intermetacarpal branches are small. Incision in the fold of the thenar eminence, passing from its upper junction with the hypothenar eminence toward the index finger. The centre of the incision corresponds to the middle of the thenar eminence. After dividing the skin and palmar fascia (and eventual ligation of the superficial arch) we enter at the radial margin of the lumbrical muscle beside the flexor tendons of the index finger. Then appears:

128. The radial branch of the median nerve which is drawn toward the radius together with the superficial muscles of the thenar (flexor brevis and opponens). In the depth we see the transverse fibres of the broad adductor pollicis muscle. Directly beneath the muscle, which is divided, the transverse artery appears on the deep fascia, somewhat nearer to the wrist than the superficial arch.

129. The common digital arteries are to be exposed under

the fascia between the interdigital fold and the superficial arch, by corresponding longitudinal incisions. Beside them, rising toward the surface, are the large digital branches of the ulnar and median nerves.

j. Fingers.

130. The main portion of the subcutaneous soft parts on the fingers consists of the tendons which leave only the narrow lateral surfaces free. The flexor tendons lie upon the periosteum. On the middle phalanx the tendon of the deep flexor passes through that of the superficial. The latter is semilunar in section (convex toward the bone), the former cylindrical.

The two crura of the flexor sublimis pass around the tendon of the flexor profundus and are attached to the lateral surfaces of the middle phalanx. The flexor profundus muscle, after passing through the fissure of the flexor sublimis, likewise becomes flatter and is attached to the base of the terminal phalanx. As far as the base of the terminal phalanx the tendons are surrounded by a tubular prolongation of the superficial palmar fascia, the ligamenta vaginalia, and from the condyles of the metacarpal bones downward they are invested with closed mucous sheaths which at the thumb and little finger approach the mucous sheath of the palm and often communicate with it. From the bones and joint capsules vincula tendinum pass to the under surface of the tendons.

The extensor tendon of the fingers is attached to the base of the first phalanx by isolated fibres and divides into three crura; the central one is joined under the two lateral ones by the fibres of the lumbrical and interossei muscles (the flexor of the first and extensors of the terminal phalanges), and they are attached together at the base of the middle phalanx. The lateral crura descend laterally at the upper interphalangeal joint, pass again to the dorsum, and are attached at the base of the terminal phalanx; all the extensor tendons are flat, like fasciæ. On the

thumb the extensor brevis muscle ends on the base of the first phalanx; the extensor longus, situated somewhat to the dorso-ulnar side, ends with its three crura at the base of the terminal phalanx.

As the ungual phalanx has tendons attached only at the base, the choice for incisions there is free; they may be made median or lateral according to indications.

The digital arteries and nerves (Fig. 62) pass in part at the middle phalanx from the volar to the dorsal side; in the incisions on the middle phalanx regard is to be had mainly for the larger vessels and nerves beside the volar tendon, hence lateral incisions should be placed nearer the dorsum.

On the first phalanx the two volar and two dorsal digital arteries and nerves are well developed, but here, too, the main vessels pass beside the volar tendons (the nerves on the volar side of the arteries and veins), so that incisions here may be purely lateral. Only at the base of the first phalanx should the deeper incisions deviate toward the palm after division of the skin, owing to the broad tendinous attachment of the lumbrical and interossei muscles. Where choice is free it is better to make incisions on the ulnar than the radial side, because of the short flexors of the first phalanx the lumbricals approach from the radial side.

S. Lower Extremity.

Gluteal Region.

Branches of the Hypogastric Artery.

131. *Superior Gluteal Artery* (Fig. 63).—The point for its ligation can be marked through the skin, by feeling at the level of the upper end of the intergluteal furrow and at the upper margin of the belly of the glutæus maximus the upper circumference of the great sciatic foramen.

Incision in the direction from the posterior superior iliac

spine to the tip of the great trochanter, corresponding to the upper two-thirds of this line. Division of the skin, fascia, and the thick glutæus maximus, parallel to its fibres. After severing the fascia of the glutæus medius, this muscle is laid bare, without cutting, at its lower margin and drawn up. Under it the finger feels the upper circumference of the great sciatic foramen. Here, above the upper margin of the pyriformis muscle, the thick artery passes directly backward from the pelvis and at once gives off large branches (the main branch going laterally). Beside it the superior gluteal nerve (Fig. 63) leaves the pelvis, passing between and supplying the glutæus medius and minimus, and following the main branch of the artery laterally to the tensor fasciæ latæ muscle.

132. *Inferior Gluteal (Sciatic) Artery* (Fig. 63).—Incision in the direction from the inferior posterior iliac spine to the base of the great trochanter, parallel to the incision for the ligation of the superior gluteal artery; the medial two-thirds of the line given are used. Division of the skin with the fatty subcutaneous tissue, the fascia, and the fibres of the thick glutæus maximus muscle. Under the latter the posterior margin of the pyriformis muscle becomes visible and is laid bare with the fingers; under its medial end the artery emerges accompanied by the nerve of the same name which, like the artery, gives off thick branches to the glutæus maximus. The point where the artery passes out of the pelvis is found by the spine of the ischium and the spinoso-sacral ligament, extending in a median direction from its point. Above the spine we feel the lower margin of the great sciatic foramen over which the artery emerges.

133. The posterior femoral cutaneous nerve passes in the direction of the continuation of the arterial trunk (Fig. 72). Deeper and more laterally, directly upon the bone, lies the easily palpable main trunk of the

134. Sciatic nerve which descends over the base of the spine of the ischium and the obturator internus muscle.

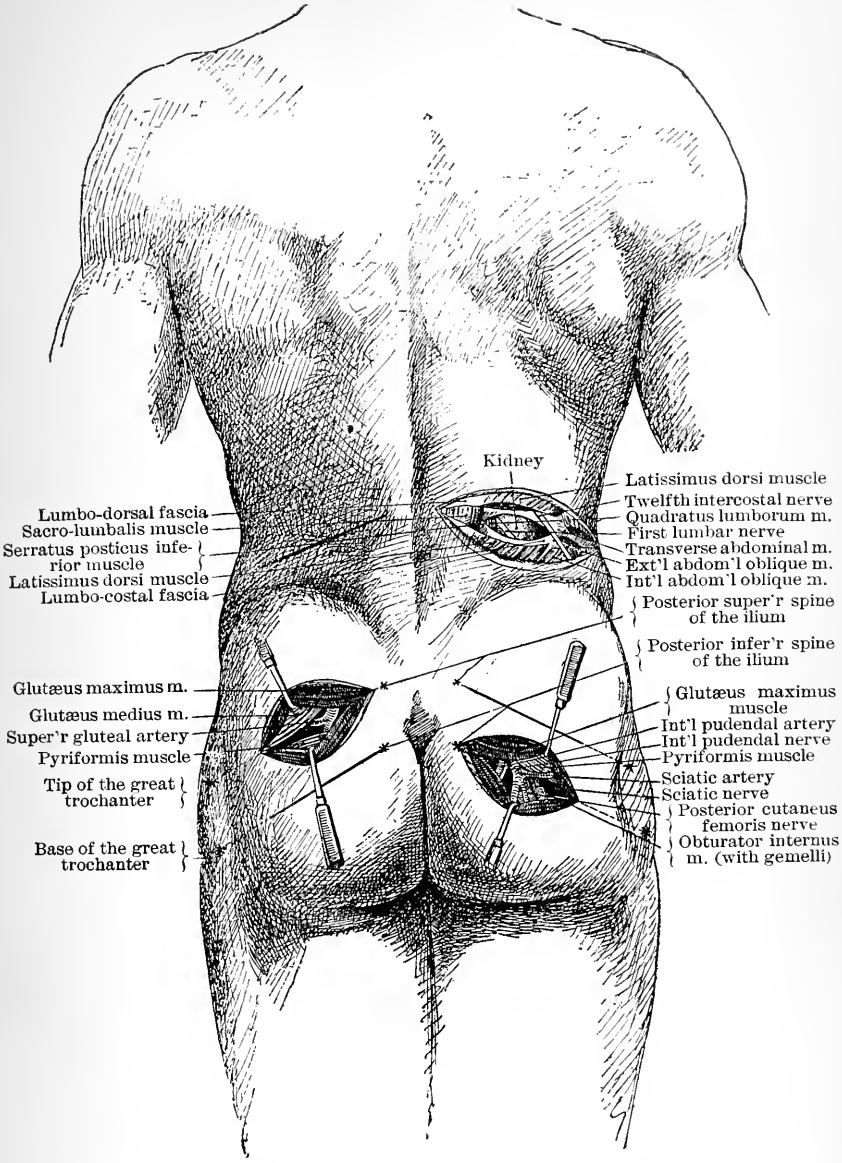

FIG. 63.—Nephrotomy. Gluteal and sciatic arteries.

135. *Internal Pudendal Artery* (Fig. 63).—Incision as for the ligation of the inferior gluteal artery. The vessel lies medially of and under the inferior gluteal artery on the posterior surface of the spine of the ischium, accompanied by the internal pudendal nerve which rests upon it. It may be recognized by its re-entering the pelvis below the spine.

Inguinal Region.

136. *External Iliac Artery* (Figs. 64 and 65).—Incision parallel to and immediately above the middle third of Poupart's ligament. Division of the skin and the well-developed superficial fascia. The superficial epigastric artery which ascends vertically in the latter must be severed. Division of the aponeurosis of the external abdominal oblique. The internal oblique and the transversus are lifted with the handle of the scalpel from the ascending groove of Poupart's ligament, then the thick transverse fascia is cut. The artery lies under the middle of Poupart's ligament, imbedded in adipose tissue with glands; inward from it is the vein, outward the fascia of the psoas muscle. Between the latter and the margin of the internal iliac muscle, which lies about 2 cm. laterally from the artery in the depth, is the crural nerve. Upon the artery are the thin crural branches of the genito-crural nerve which supply the medial anterior side of the skin of the thigh in the upper third.

The branches of the external iliac artery, namely, 137. Inferior epigastric and 138. Circumflexa ilii artery, can be exposed by the same incision as the external iliac, at their point of origin above Poupart's ligament, under the abdominal muscles and under the transverse fascia.

139. *Inferior Epigastric Artery at the Anterior Abdominal Wall* (Fig. 36).—Incision two or three fingers' breadth above Poupart's ligament, parallel to its medial third, through skin,

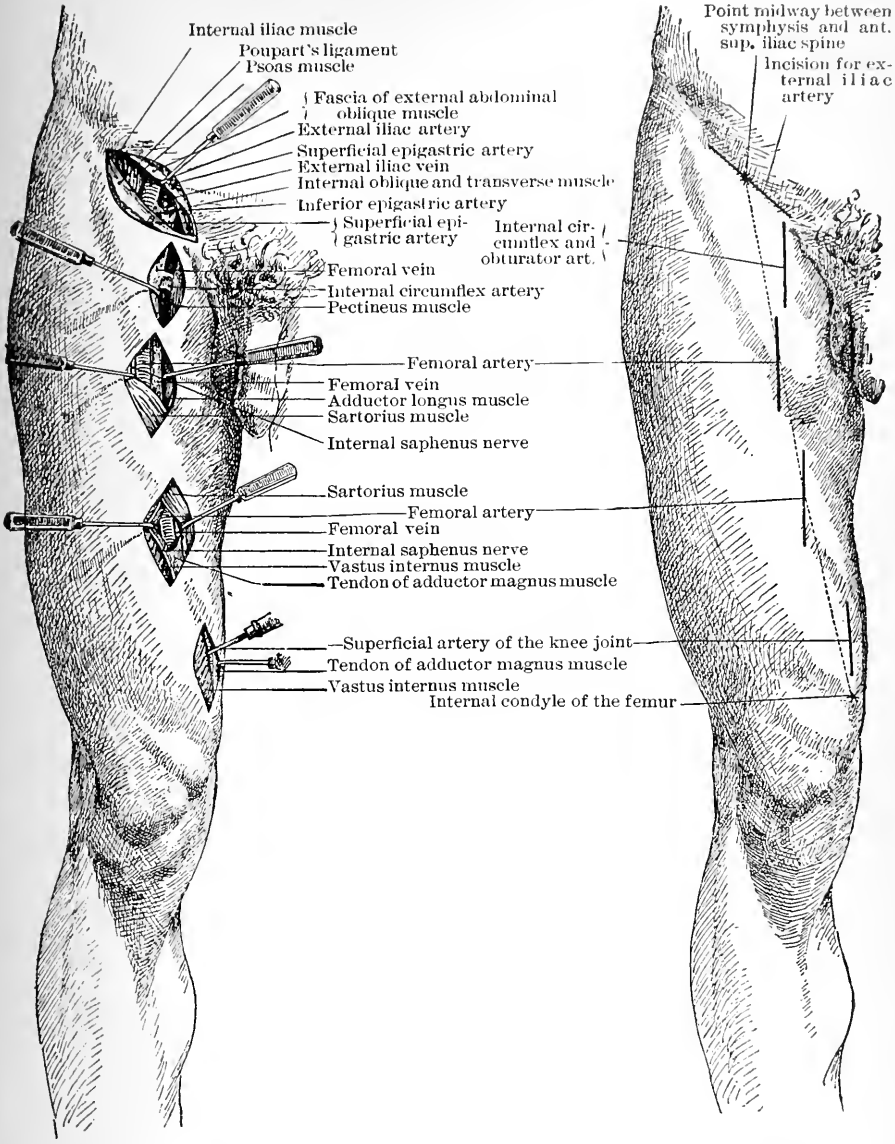

FIG. 65. FIG. 64.

FIGS. 64 AND 65.—External Iliac Artery and Femoral Artery with its Branches.

superficial fascia, the thick fascia of the external oblique and that of the internal oblique which can at least be partly separated from it. The margin of the rectus abdominis is laid bare. Beneath this, covered by a very thin layer of connective tissue (transverse fascia), we recognize the subserous fat, and upon it the artery ascending obliquely from without and below to the wall of the rectus. The transverse fascia, which below lies upon and above under the artery, here exhibits what is known as the plica semilunaris.

140. *Circumflexa Ilii Artery* (Fig. 70).—Incision at the outer third of Poupart's ligament. Division of skin, superficial fascia, the muscular layers in which the branches of the ilio-inguinal nerve are exposed, and the thick transverse fascia. The peritoneum being slightly pushed up with the fingers, the artery is found parallel to Poupart's ligament on the internal iliac fascia; obliquely outward and downward it is crossed by the lateral cutaneous femoral nerve.

141. *Aorta and Common Iliac Artery* (Figs. 66 and 67).—At the level of the umbilicus or the line connecting the anterior superior iliac spines the aorta divides into the two common iliac arteries which run vertically to the middle of a line connecting the anterior superior iliac spine with the symphysis pubis, downward along the medial psoas margin. The upper third of the line corresponds to the common iliac, the lower two-thirds to the external iliac.

Incision beginning in front of the tip of the eleventh left rib, passing obliquely downward and forward within two fingers' breadth above the middle of Poupart's ligament. Division of skin, superficial fascia, and the thick muscular layers of the abdominal wall with the characteristic course of the fibres of the obliquus externus, internus, and transversus. Between the last two the thick branches of the lumbar vesels and nerves are exposed. Division of the well-developed transverse fascia and the subserous fat. Detachment of the peritoneum first down-

ward and then backward of the internal iliac fascia (which covers the internal iliac muscle with shining transverse fibres) as far as the inner margin of the psoas muscle and thence upward to the anterior surface of the spinal column. The lateral cutaneous femoral nerve passes obliquely outward and downward on the iliac fascia; above it are the vasa circumflexa post. ilii. With the peritoneum,

142. The internal spermatic vessels which pass to the posterior inguinal ring are detached. In a median direction, above the bifurcation of the common iliac artery,

143. The ureter descends nearly vertically into the pelvis and is likewise detached. Alongside of the common iliac artery the genito-crural nerve descends and bends over the anterior surface of the external iliac artery. On the anterior surface of the spinal column the aorta divides. Above it a very large vessel,

144. The inferior mesenteric artery, descends vertically and is to be detached likewise with the peritoneum. About 3 cm. above the bifurcation of the aorta a lumbar artery branches off laterally.

145. *Hypogastric Artery* (Figs. 66 and 67).—Incision as for the common iliac artery. The vessel originates at the inner margin of the psoas muscle, in front of the sacro-iliac synchondrosis, from the division of the common iliac artery. It turns inward and downward into the lesser pelvis at the point where the ureter crosses the anterior surface of the common iliac artery.

For the branches of the hypogastric artery see the Gluteal region.

146. *Obturator Artery and Nerve* (Fig. 61).—The artery is a branch of the hypogastric. Incision as for the ligation of the internal circumflexa femoris, beginning a finger's breadth in a median direction from the middle of Poupart's ligament and extending vertically downward. Division of skin, superficial fascia, and tense fascia lata. The great saphenous vein resting

upon the latter is drawn laterally downward, at the inner margin of the femoral vein the fascia pectinea is severed, and the outer margin of the pectineal muscle is laid bare and drawn down in a median direction and eventually nicked transversely above.

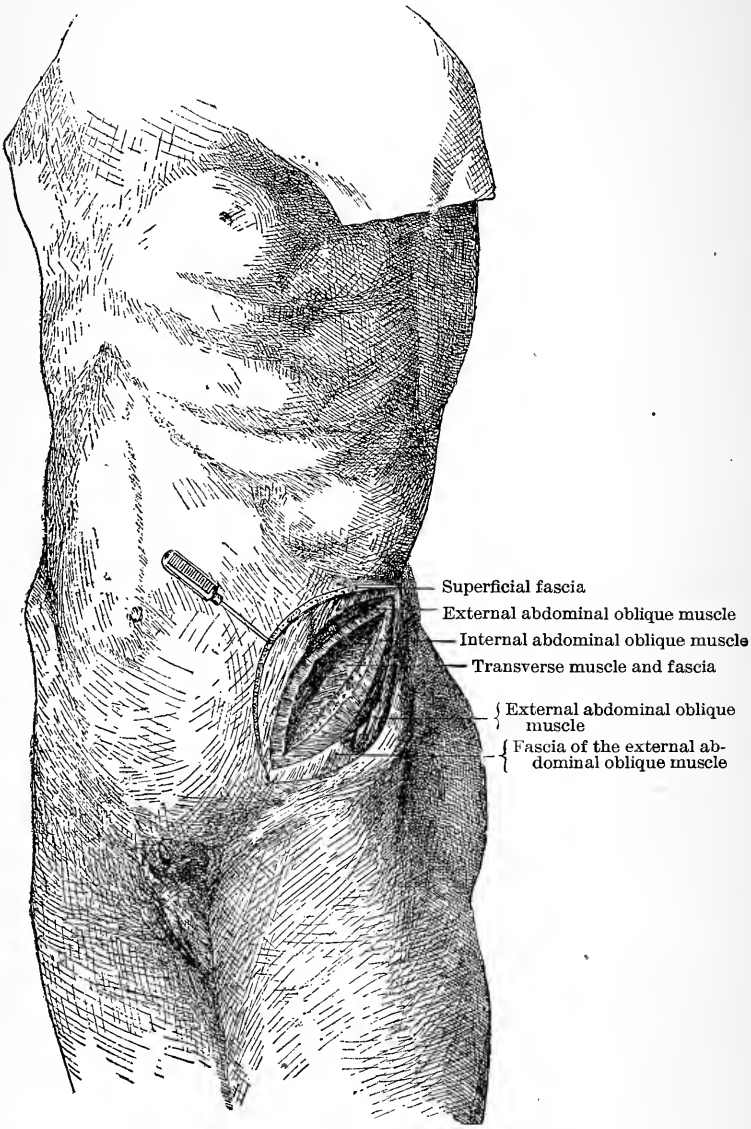

Fig. 66.

Under the upper attachment of the muscle and below the horizontal ramus of the pubic bone the finger feels the obturator foramen from which emerges the artery with the

147. Obturator nerve, over the upper margin of the external obturator muscle, whose fascia must be divided.

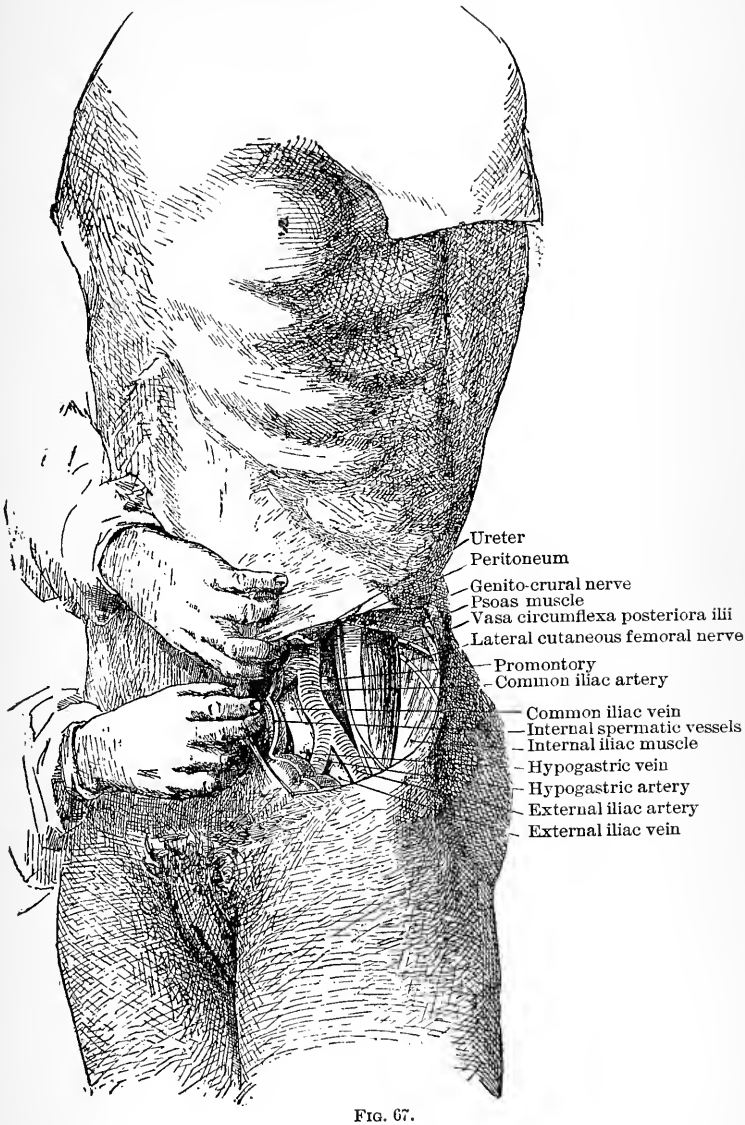

FIG. 67.

The Thigh (Figs. 68, 69, 70, 71).

148. *Femoral Artery.*—It descends vertically in a line from the middle of Poupart's ligament to the centre of the popliteal space, passing backward to the inner surface of the bone at the limit of the middle and lower thirds. The direction of the incisions for its ligation on the anterior and lateral surfaces can be determined by a line from the middle of Poupart's ligament to the internal condyle of the femur (linea inguino-condylica). On the lower third of the thigh the artery lies on the dorsal surface.

Femoral Artery at its Entrance into the Popliteal Space (Figs. 78 and 79).—Incision behind the cord-like projecting tendon of the adductor magnus which ends at the internal condyle of the femur. Posteriorly are the belly of the sartorius, the tendon of the gracilis, and the semi-tendinosus (under the latter the semi-membranosus). In the subcutaneous tissue we find the great saphena vein. After dividing the fascia the sartorius muscle presents; between it and the tendon of the great adductor we penetrate into the depth and find the artery imbedded in fat behind the tendon at the bone; dorsad toward the skin the femoral vein and the tibialis posticus nerve. After the sartorius muscle is drawn backward we expose beneath it the internal saphenus nerve with a branch of the arteria articularis genu suprema.

Above the Adductor Fissure (Figs. 68 and 69).—Longitudinal incision at the limit of the inferior and middle thirds of the femur, measured from the anterior superior spine, at the point where the finger can be pressed against the bone between the adductors and extensors (quadriceps). Incision through the skin, preserving the great saphena vein, division of the fascia, when the sartorius muscle, characterized by its longitudinal fibres, is drawn inward and backward. We penetrate at the inner surface of the fascia of the vastus internus, whose fibres

run obliquely forward. This fascia is severed at the anterior margin of the glistening white tendon of the great adductor. The artery is rather close to the bone. Postero-internally is the vein, above the vascular sheath of the internal saphenus nerve. Care is needed not to go too far backward, *i.e.*, behind the adductor tendon.

In the Upper Third (Figs. 68 and 69).—Skin and fascia lata are divided in the inguino-condylic line. The sartorius is drawn outward. Under this muscle lies the vascular sheath with the branches of the crural nerve, the thickest of which is the saphenus, laterally from the artery. The femoral vein is postero-internally. Above the fascia, in a median direction from the incision, is the great saphena vein.

Common Femoral Artery (Figs. 70 and 71).—Transverse incision below the palpable Poupart's ligament, parallel to its middle third. The superficial epigastric artery in the subcutaneous tissue is ligated. The superficial layer of the fascia lata is severed under Poupart's ligament which is distinctly palpable. The artery with two branches (inferior epigastric inward and circumflexa ilii outward) appears under the middle of Poupart's ligament, resting on the pubic bone and distinctly palpable. On the vascular sheath is the genito-crural nerve; inward from the artery the femoral vein, outward the fascia of the ilio-psoas muscle under which the trunk of the crural nerve descends at the inner margin of the muscle.

Branches of the Femoral Artery.

149. *Superficial Artery of the Knee Joint* (Figs. 68 and 69).—Incision in a line upward from the internal condyle of the femur. The skin and tense fascia are divided. The sartorius muscle is drawn backward. Underneath, imbedded in fat, the internal saphenus nerve becomes visible, accompanied by the superficial branch of the artery. To reach the deeper main branch we proceed toward the bone above the prominent glisten-

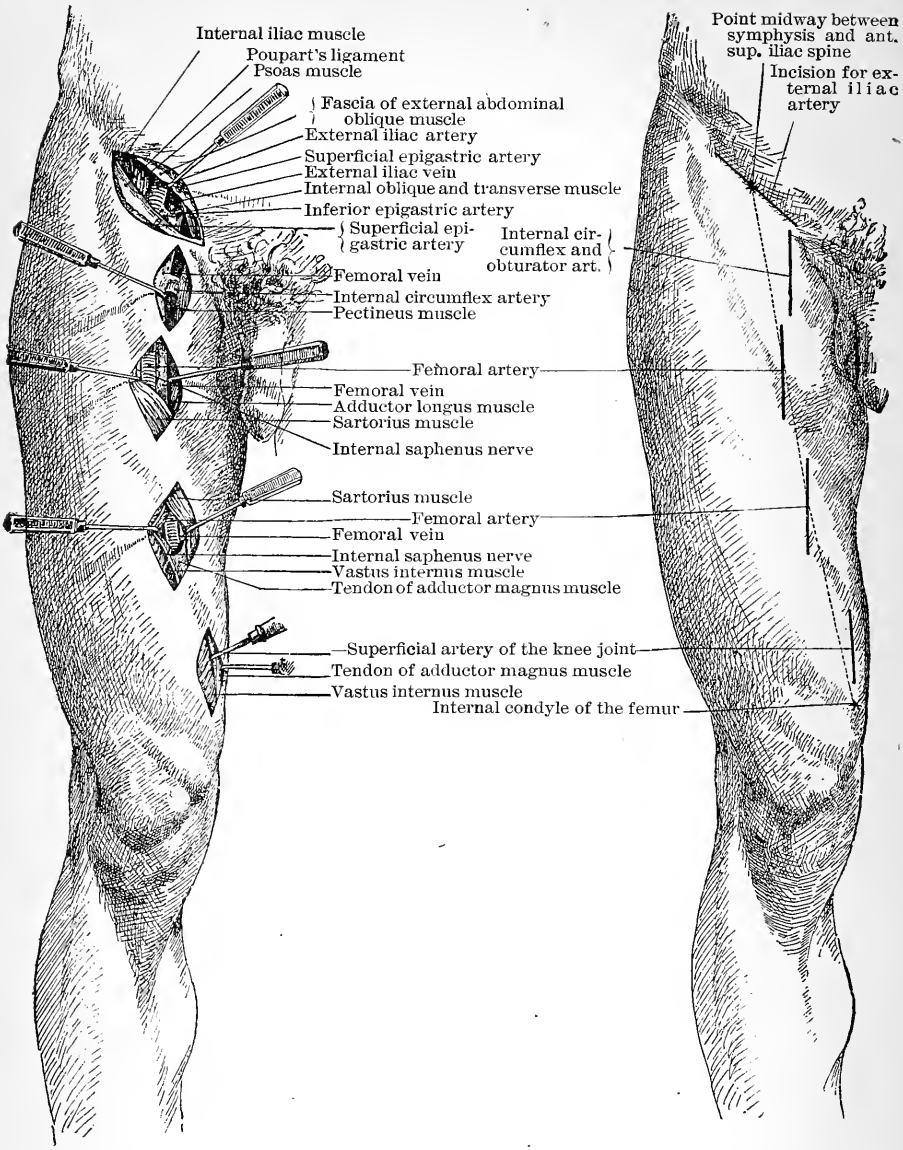

FIG. 69. FIG. 68.

FIGS. 68 AND 69.—External Iliac Artery and Femoral Artery with its Branches.

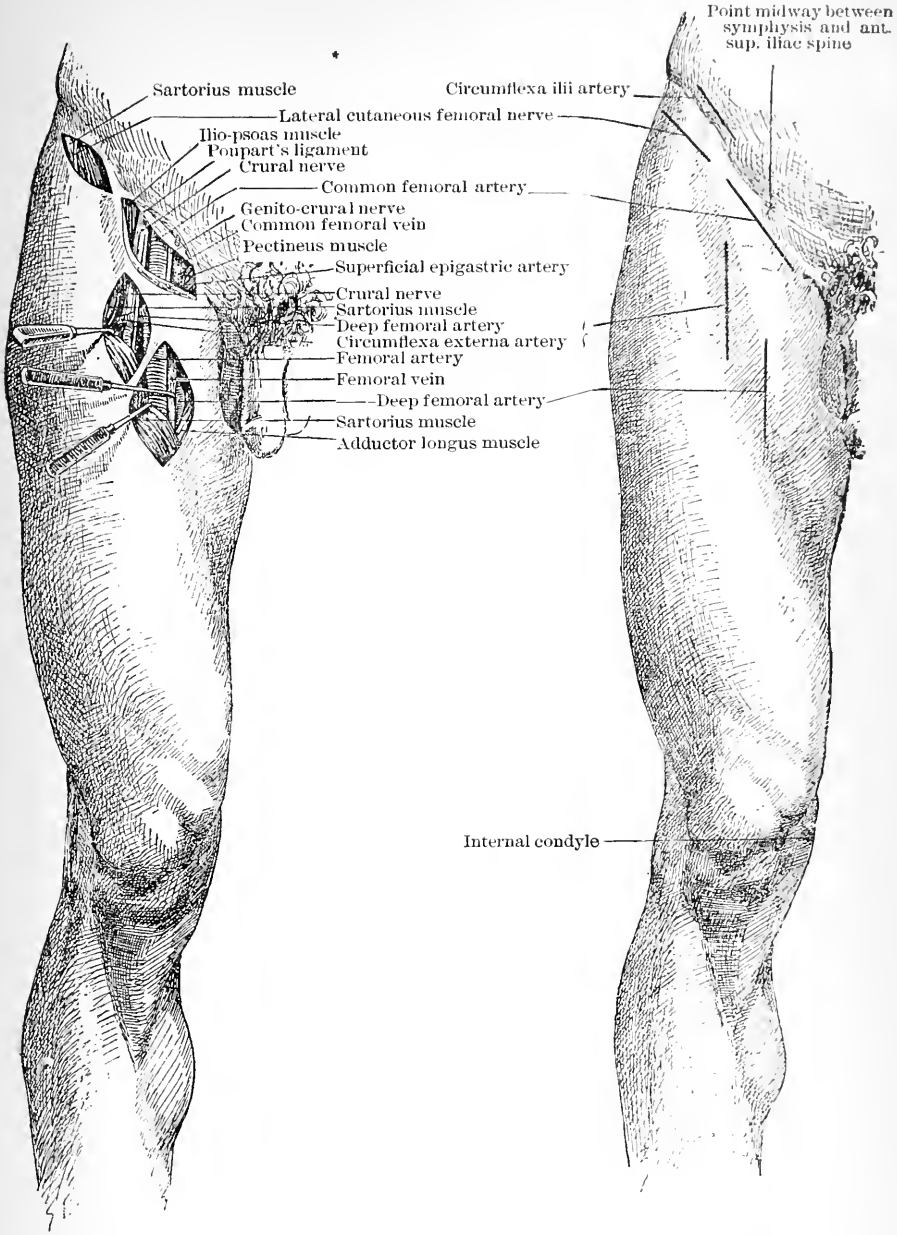

FIG. 71. FIG. 70.

FIGS. 70 AND 71.—Femoral Artery with its Branches and Lateral Cutaneous Femoral Nerve.

ing tendon of the great adductor, under the vastus internus muscle. As the artery springs from the femoral in front of the adductor fissure, it can be ligated there in the same way as the latter artery.

a. Deep Artery at its Origin and External Circumflex Femoral Artery (Figs. 70 and 71).—Incision 1 cm. laterally from the middle of Poupart's ligament, beginning two fingers' breadth below it, and extending straight downward (the centre of the incision corresponds to the level of the base of the great trochanter). The skin and the tense fascia lata are divided. The inner margin of the sartorius is exposed and the muscle drawn outward. Underneath, imbedded in the fat, are the branches of the crural nerve. These are drawn laterally downward. The lateral margin of the femoral artery now becomes visible; laterally and downward it gives off the profunda artery and the external circumflex which sinks transversely under the rectus femoris muscle. The point of origin corresponds to the lower circumference of the belly of the ilio-psoas.

b. The terminal branch of the external circumflex artery is found upon the bone, one finger's breadth under the highest lateral prominence of the great trochanter, by dividing the skin, the thick fascia lata, and the body of the vastus externus muscle transversely.

150. *Deep Artery at the Adductor Longus* (Figs. 70 and 71).—The incision is made as for the ligation of the femoral, vertically through skin and fascia, at the limit of the upper and middle thirds of the femur, a hand's breadth under the inguinal fold. The exposed sartorius is drawn laterally, but instead of opening the deep fascia on the vessels (vascular sheath) as for the femoral, we divide medially from it the fascia of the long adductor and enter the depth toward the bone on the outer side along the body of this muscle, behind the femoral vein. At the posterior margin of the vastus internus and at the lateral upper margin of the adductor longus we strike the large

artery, its chief prolongation passing under the last-named muscle.

151. *Internal Circumflex Artery* (Figs. 68 and 69).—The artery, as a rule, branches from the common femoral; in other cases from the profunda femoris. Incision one finger's breadth inward from the middle of Poupart's ligament, passing vertically through the skin; on the fascia lata we find the great saphena vein which is drawn laterally. The fascia is severed so as to freely expose the body of the pectineus muscle.

At the lateral margin of this muscle, below the obturator externus, the artery passes directly backward on the inner side of the femur, sending a large branch in a median direction.

The artery is dissected from the adipose tissue at the inner margin of the femoral vein. When derived from the profunda artery it passes under the vein; when from the common femoral, occasionally over it, though in most cases likewise under the vein.

152. *Crural Nerve* (Figs. 70 and 71).—It is exposed at the point for the ligation of the external circumflex artery (which see) or that of the common femoral. Transverse incision as for ligating the latter, along and below the middle third of Poupart's ligament. The incision is continued laterally through the sheath of the ilio-psoas muscle, and immediately under it, on the medial side of the muscle, is the thick nerve, dividing into several branches.

153. *The internal saphenus nerve* (Figs. 78 and 79) accompanies the femoral artery to the fissure of the adductor and lies on the vascular sheath, at first outward, then forward. For its exposure at the knee see below.

Above the line of the joint (Figs. 78 and 79) it is to be looked for in front of the prominence of the sartorius, under which it passes backward and downward. It lies at the margin of the adductor tendon. Incision the same as for the ligation of the superficial artery of the knee-joint.

154. *Lateral Cutaneous Femoral Nerve* (Figs. 70 and 71).—

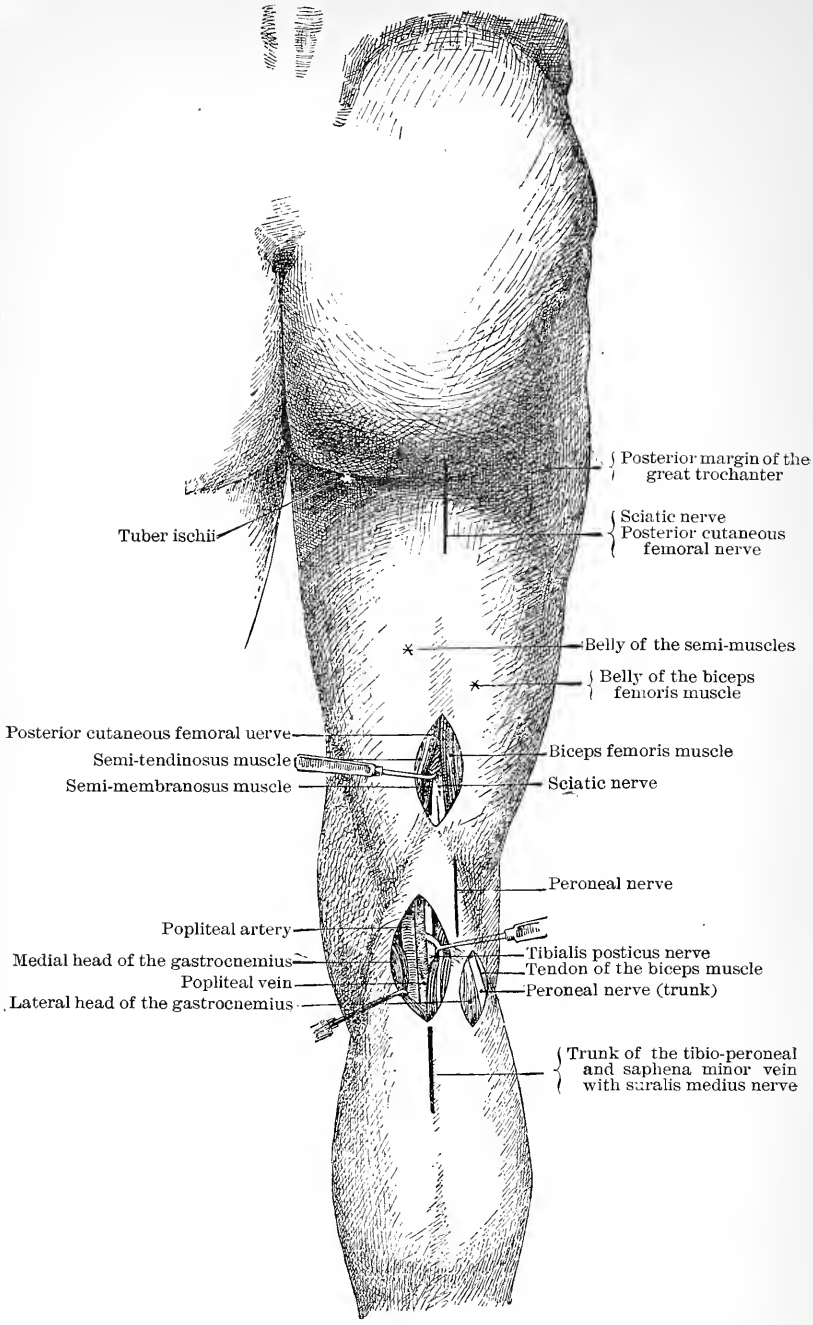
Posterior margin of the great trochanter
Sciatic nerve
Posterior cutaneous femoral nerve
Tuber ischii
Belly of the semi-muscles
Belly of the biceps femoris muscle
Posterior cutaneous femoral nerve
Semi-tendinosus muscle
Semi-membranosus muscle
Biceps femoris muscle
Sciatic nerve
Peroneal nerve
Popliteal artery
Medial head of the gastrocnemius
Popliteal vein
Lateral head of the gastrocnemius
Tibialis posticus nerve
Tendon of the biceps muscle
Peroneal nerve (trunk)
Trunk of the tibio-peroneal and saphena minor vein with suralis medius nerve

FIG. 72.

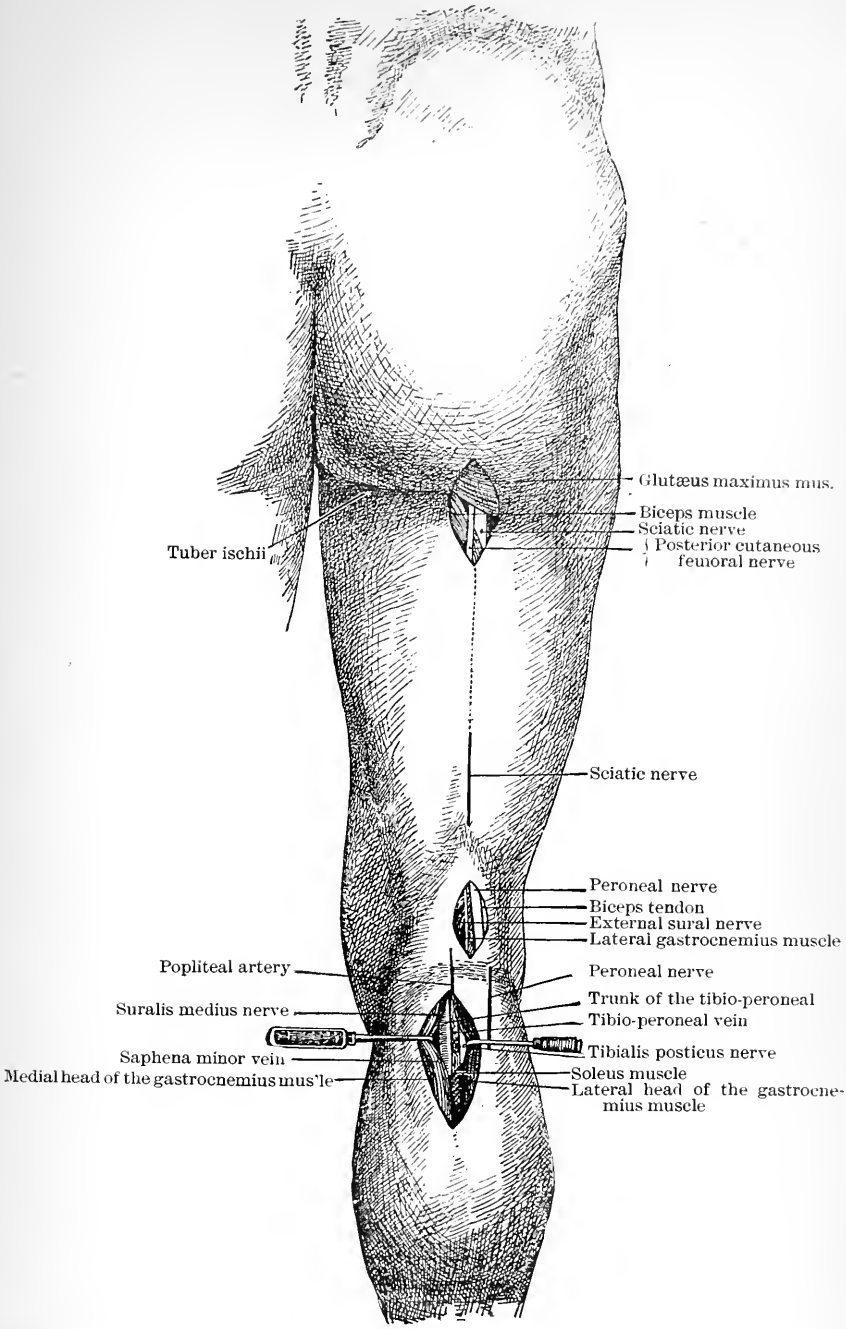
Glutæus maximus mus.
Biceps muscle
Sciatic nerve
Posterior cutaneous femoral nerve
Tuber ischii
Sciatic nerve
Peroneal nerve
Biceps tendon
External sural nerve
Lateral gastrocnemius muscle
Popliteal artery
Peroneal nerve
Suralis medius nerve
Trunk of the tibio-peroneal
Tibio-peroneal vein
Saphena minor vein
Tibialis posticus nerve
Medial head of the gastrocnemius muscle
Soleus muscle
Lateral head of the gastrocnemius muscle

FIG. 73.

Incision one finger's breadth below the anterior superior iliac spine parallel to Poupart's ligament, through skin and fascia. The nerve is under the latter, 2 cm. below the spine, passing obliquely latero-inferiorly over the external margin of the attachment of the sartorius.

The Thigh—Dorsal Surface.

155. *Sciatic Nerve* (Figs. 72 and 73). *In the Lower Half of the Thigh.*—Incision on the dorsal surface of the thigh, midway between the bellies of the semi-muscles and the biceps femoris. After dividing the skin the thick cutaneus posticus nerve appears on the fascia. The muscles are to be separated without cutting, and deeply between them on the dorsal surface of the bone lies the sciatic nerve, often divided into its two main trunks. In the upper part the above-mentioned depression is limited on the medial side by the body of the semi-tendinosus; below, where the muscle becomes tendinous, the semi-membranosus takes its place.

At the Upper End of the Thigh (Figs. 72 and 73.)—Incision downward from the gluteal fold, beginning at the centre of a line from the tuber ischii to the posterior margin of the great trochanter. The skin and fascia are divided. The lower margin of the glutæus maximus is laid bare and drawn up. The cutaneus femoris posticus nerve becomes visible. In the depth, at the outer margin of the biceps muscle which is drawn inward, is the thick nerve trunk. At the same point, but deeper and more medially, the terminal branch of the inferior gluteal artery can be ligated on the quadratus femoris muscle.

At its Exit from the Pelvis.—See Ligation of the sciatic artery, page 168.

Region of the Knee Joint.

156. *Popliteal Artery* (Figs. 72 and 73.)—Incision in the median line on the posterior surface of the knee in the line of the joint. In the lowest part of the incision the saphena minor

vein and the suralis medius nerve (communicans tibialis) must be spared above the fascia. We penetrate on the medial side of the saphena vein through the fat between the two heads of the gastrocnemius; the posterior tibial nerve appears first and is drawn outward. Then the vein becomes visible, being closely united to the underlying artery by a firm sheath. The artery rests in the upper portion on the fat of the dorsal surface of the femur; in the lower portion, on the popliteal muscle.

157. *Peroneal Nerve* (Figs. 72 and 73).—It is distinctly palpable and even visible behind the condyle of the fibula and still better on the posterior surface of the external condyle of the femur.

159. Beside it can be felt the communicating peroneal nerve, especially higher up, behind the external condyle of the femur. Incision along the posterior margin of the biceps tendon from the condyle of the fibula upward. The peroneal nerve lies directly under the fascia at the lateral margin of the gastrocnemius, and below the condyle of the fibula it passes into the peroneus longus muscle, having given off, a few centimetres above, the lateral sural nerve (communicans peroneus).

The Leg—Anterior Surface.

160. *Tibialis Antica Artery and Peroneal Nerves* (Figs. 74 and 75).—The course of the tibialis antica artery is marked by a line from the anterior projection of the external condyle of the tibia (*i.e.*, a point midway between the spine of the tibia and the capitulum fibulæ) to the centre between the two malleoli and thence to the first intermetatarsal interspace.

In the Lower Third.—Incision at the outer margin of the tendon of the tibialis anticus (the first thick tendon projecting laterally from the sharp anterior edge of the tibia), passing between this and the tendon of the extensor hallucis longus. The skin and the very thick fascia are divided, and the last-named

tendon is freely exposed and drawn outward. We penetrate, without cutting, with the fingers toward the outer surface of the tibia. Laterally from the body of the tibialis anticus muscle the deep peroneal nerve appears first and beneath it the artery.

In the Middle Third.—Incision 3 cm. outward from the edge of the tibia, in the palpable and often visible depression at the lateral margin of the tibialis anticus muscle. The skin is divided and then the fascia along a white line in the latter which indicates the above-named depression (a second white line, more laterally, marks the interspace between the extensor hallucis longus and the extensor digitorum communis longus). We penetrate with the fingers into the interosseal space upon which the artery lies with the deep peroneal nerve (to the outside), under the body of the tibialis anticus muscle, between it and the extensor hallucis longus.

At the Upper End.—Downward incision from the centre between the spine of the tibia and the capitulum fibulæ, beginning a thumb's breadth below the tuberosity of the external condyle of the tibia. On the latter, after dividing skin and fascia, the attachment of the tibialis anticus presents as a laterally tendinous margin which marks the depression toward the extensor digitorum communis. We penetrate with the fingers between the above-named muscles as far as the interosseal ligament, at whose upper end the artery perforates the ligament from behind, about one finger's breadth below the head of the fibula. The deep peroneal nerve comes forward a little farther down, from the lateral side under the extensor digitorum communis muscle against which it rests. The nerve gives off the branches to the tibialis anticus muscle quite high up.

161. *Deep Peroneal Nerve near its Origin* (Figs. 76 and 77).—Incision a finger's breadth in front of the capitulum fibulæ, extending downward from the most lateral point of the external condyle of the tibia, through skin and fascia. We penetrate between the extensor digitorum longus and peroneus

External condyle of the tibia
Tibialis anticus muscle
Extensor digitorum communis muscle
Tibialis antica artery
Deep peroneal nerve
Belly of extensor digitorum longus muscle
Belly of tibialis anticus muscle
Extensor hallucis longus muscle
Tibialis antica artery
Deep peroneal nerve
Tibialis anticus muscle
Prominence of the tendon of the tibialis anticus muscle
Tibialis anticus muscle
Deep peroneal nerve
Tibialis antica artery
Extensor hallucis longus muscle
Point midway between the malleoli
Extensor hallucis longus muscle
Ligamentum cruciatum
Superficial peroneal nerve
Deep peroneal nerve
Dorsalis pedis artery
Deep peroneal nerve
Dorsalis pedis artery
Tendon of ext. hall. longus muscle
Superficial peroneal nerve
Extensor hallucis brevis muscle
Tendon of ext. hall. longus muscle
Extensor hallucis brevis muscle
Interosseus muscle
Superficial peroneal nerve
Dorsalis pedis artery
Deep peroneal nerve
First intermetatarsal interspace

FIG. 74. FIG. 75.

FIGS. 74 AND 75.—Tibialis Antica Artery; Deep Peroneal Nerve.

longus muscles. In the depth, almost transversely in front of the head of the fibula, the nerve passes medially in the above-named furrow under the extensor longus muscle, while the superficial peroneal nerve passes downward below in the same furrow.

In its further course the deep peroneal nerve accompanies the tibialis antica antery for its entire length and can be exposed by the same incision. It lies on its lateral side, except far down where it is on the anterior and inner side.

162. *Superficial Peroneal Nerve* (Figs. 76 and 77). *In the Upper Third.*—See Exposure of the deep peroneal nerve under the head of the fibula.

At the Middle of the Leg.—Incision at the anterior surface of the belly of the peroneal muscles; division of skin and fascia. We penetrate between the muscles named (longus above, brevis below) and the extensor digitorum longus. The peroneal nerve is drawn laterally. The nerve lies deep in the furrow, becoming more superficial farther down.

At the Limit of the Middle and Lower Thirds.—Incision midway between the anterior edge of the tibia and the posterior edge of the fibula. At this point the nerve can occasionally be felt through the skin.

The Leg—Dorsal Surface.

163. *Tibialis Postica Artery and Tibialis Posticus Nerve* (Figs. 78 and 79).—The direction of the incisions for ligation is on the medial surface of the leg, from the lower margin of the internal condyle of the tibia to the centre between the internal malleolus and the Achilles tendon.

Behind the Internal Malleolus.—Incision midway between the Achilles tendon and the posterior edge of the tibia, through the skin and fascia which contain stout transverse fibres (ligamentum laciniatum) and under which the artery lies toward the malleo-

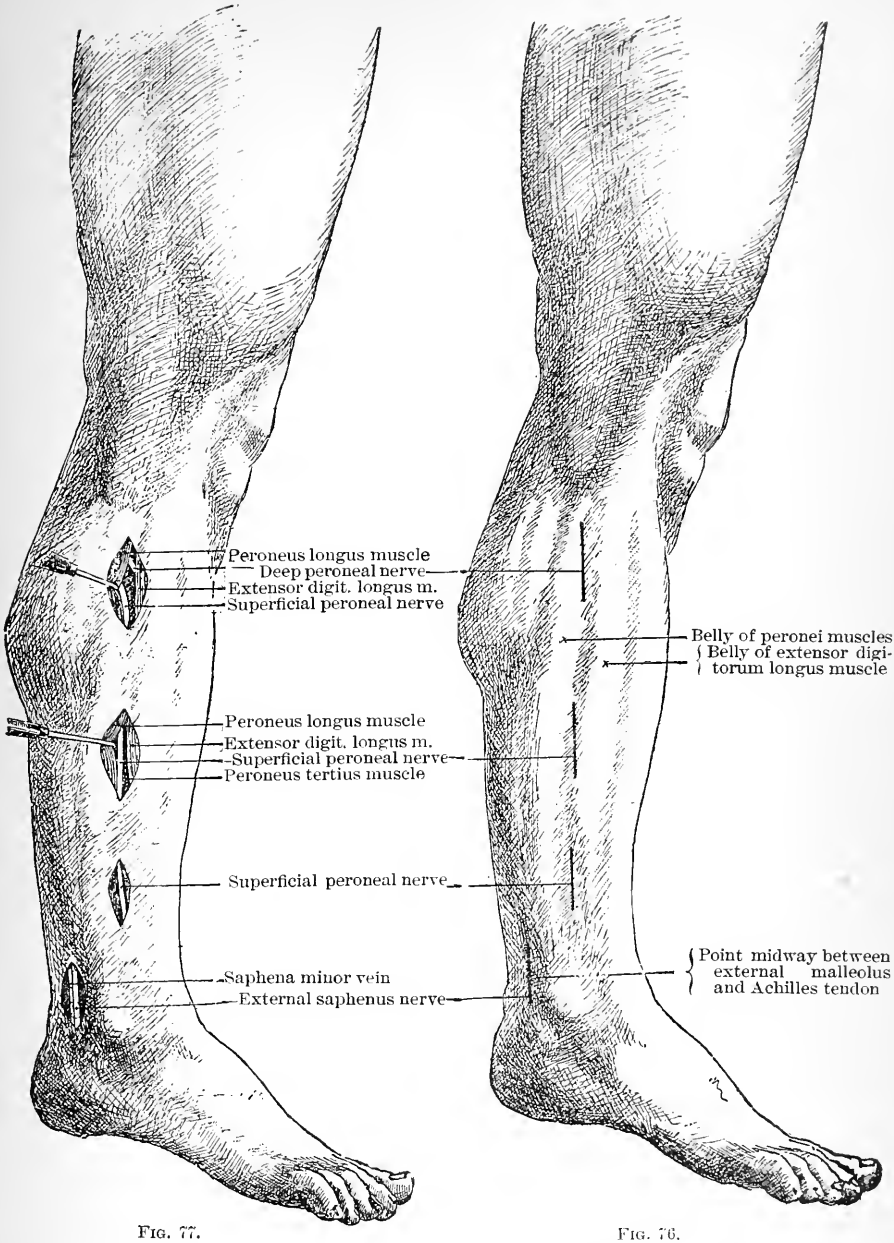

FIG. 77. FIG. 76.

FIGS. 76 AND 77.—Peroneal Nerve, External Saphenus Nerve, Saphena Minor Vein.

lus, immediately behind the flexor tendons (posteriorly flexor hallucis longus, then flexor digitorum communis, anteriorly tibialis posticus). The very thick tibialis posticus nerve lies dorsad. Care should be taken not to penetrate into the adipose tissue situated in front of the Achilles tendon.

In the Lower Third.—Downward incision from the upper angle of the visible and palpable furrow between the deep flexors (next to flexor digitorum longus) and the anterior margin of the soleus.

The skin and fascia are divided, preserving the great saphena vein and the internal saphenus nerve situated behind it. After the fascia of the soleus is divided, the latter is drawn backward. The artery lies at the depth of 1 to 2.5 cm. on the posterior surface of the flexor digitorum longus which adjoins the tibia, under the thin fascia of this muscle, and on its lateral side is the tibialis posticus nerve.

Above the Middle and in the Upper Third.—Incision at a distance of 1 cm. from the inner edge of the tibia. The great saphenus nerve which comes within the line of the incision, and the great saphena vein in front of it, must be preserved. After severing the fascia the attachment of the soleus to the tibia is divided until we come to the obliquely striated tense deep fascia (the inner belly of the gastrocnemius is merely drawn laterally downward). We open the deep fascia which is attached to the dorsal surface of the tibia, so that the body of the flexor digitorum longus is exposed. We penetrate deeply with the finger, laterally between this muscle and the deep fascia, and find the artery 3 cm. from the edge of the tibia, resting upon the tibialis posticus muscle. Laterally from it is the thick tibialis posticus nerve. We must particularly avoid penetrating between the tibia and the flexor longus muscle, or between the soleus and gastrocnemius, or above the deep fascia.

164. *Tibio-Peroneal Trunk* (Figs. 72 and 73).—Incision in the median line under the popliteal space, downward from the

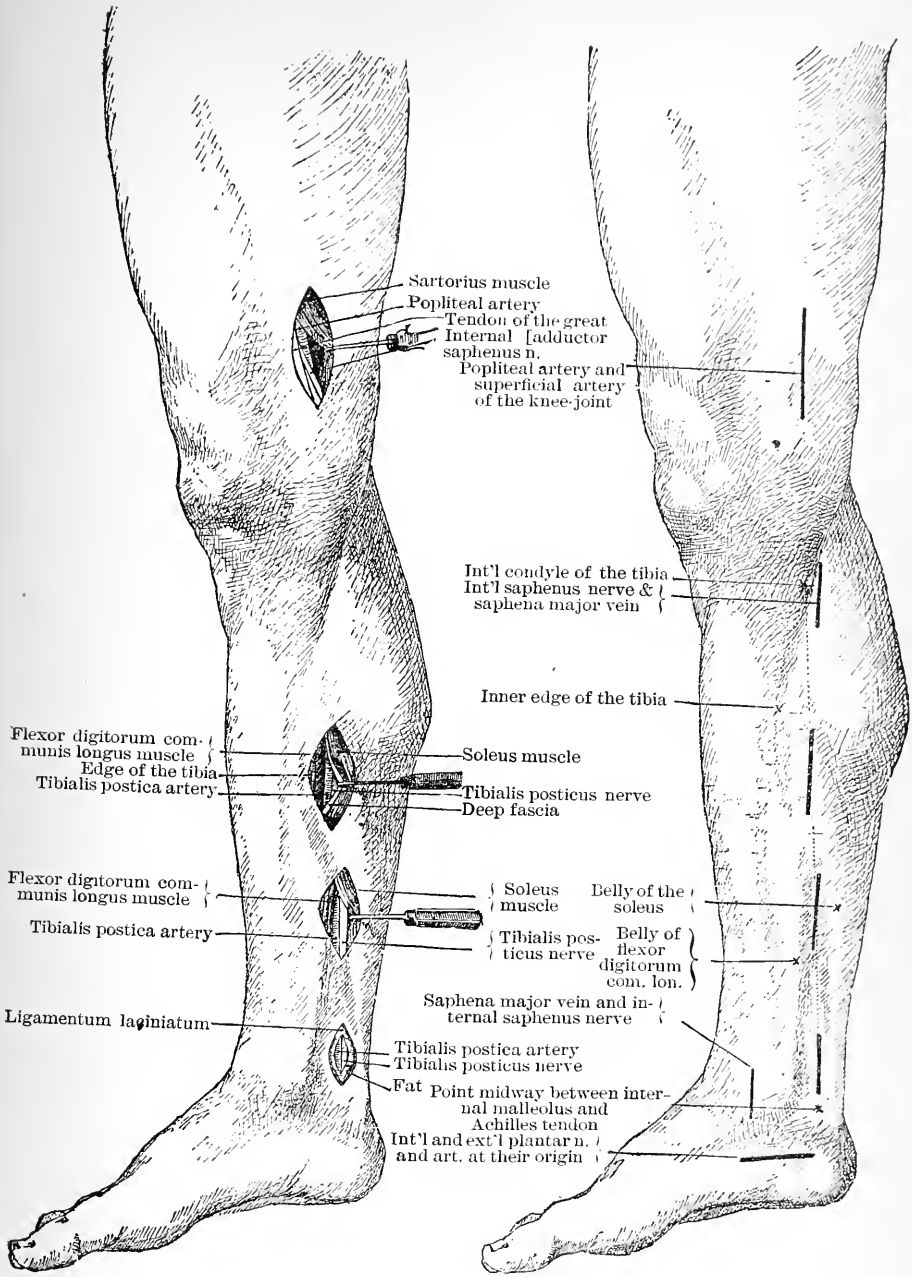

Fig. 79. Fig. 78.

Figs. 78 and 79.—Tibialis Postica Artery, Tibialis Posticus Nerve, Internal Saphenus Nerve, Saphena Major Vein.

horizontal level of the head of the fibula. We divide the fascia, but preserve the minor saphena vein and beside it the communicans tibialis nerve (suralis medius). These structures are drawn inward. They mark the contact of the two heads of the gastrocnemius between which we penetrate. The large vascular and nerve branches passing to the two heads of the gastrocnemeus are drawn aside. Under the lateral head we strike the margin of the attachment of the soleus which descends inward from above and without, and the thin tendon of the plantaris longus which passes inward and downward. At the upper margin of the soleus the trunk of the tibio-peroneal begins, after giving off the tibialis antica artery. Hence the margin of the soleus must be drawn downward or nicked so as to get under that large branch. As in the case of the popliteal artery the tibialis posticus nerve and the vein are drawn outward in order to reach the artery. The popliteal artery descends on the popliteal muscle, at whose inferior margin it gives off the tibialis antica artery forward through the interosseal ligament, about 6 cm. below the line of the knee joint.

The Leg—External Surface.

165. *Peroneal Artery* (Figs. 80 and 81). The direction of its course is in a straight continuation of the popliteal artery along the medial posterior surface of the fibula. The posterior surface of the fibula can be felt through the entire length of the leg. The incisions are made in a line passing from the posterior circumference of the head of the fibula to a point between the internal malleolus and the Achilles tendon. The artery arises in the upper third of the leg from the tibio-peroneal trunk.

Above the Middle.—Incision upon the posterior fibular surface behind the eminence of the peroneal muscles. The communicating peroneal nerve comes in view. The fascia lata is

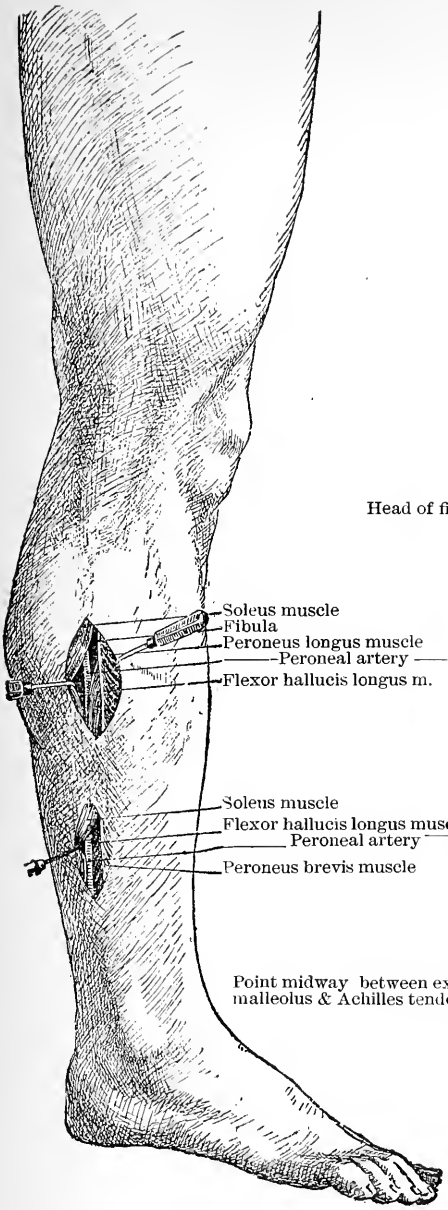
Soleus muscle
Fibula
Peroneus longus muscle
Peroneal artery
Flexor hallucis longus m.
Soleus muscle
Flexor hallucis longus muscle
Peroneal artery
Peroneus brevis muscle

Fig. 81.

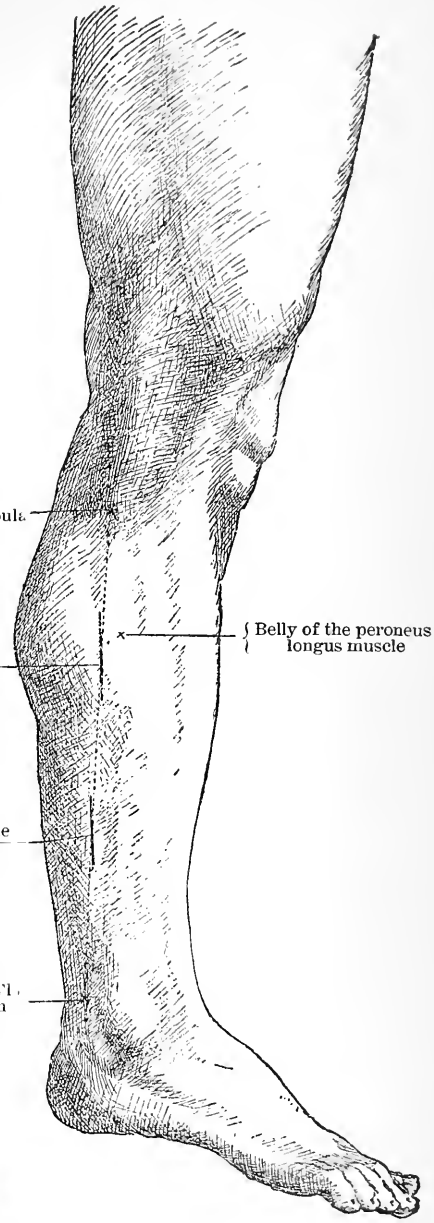
Head of fibula
Belly of the peroneus longus muscle
Point midway between ext'l malleolus & Achilles tendon

Fig. 80.

divided behind the peroneal muscles. The attachment of the soleus is separated from the fibula until the deep fascia presents which covers the flexor hallucis longus muscle on the dorsal surface of the fibula. After this fascia is severed, we penetrate into the depth between it and the muscle and at the medial margin of the latter find the artery before it enters the muscle or between the fascia and the posterior surface of the muscle.

Below the Middle.—Incision at the posterior surface of the fibula as above. After the fascia is divided, the soleus muscle is drawn medially. The artery lies superficially under the deep fascia which covers the flexor hallucis. The tibialis posticus nerve lies in a median and posterior direction from it.

166. *Internal Saphenus Nerve* (Fig. 78). *a. At the Knee.*—Incision in the line of the joint at the posterior inferior circumference of the internal condyle of the tibia, behind the tendon of the sartorius. The nerve is in the furrow between the sartorius in front and the stout tendon of the gracilis behind. The saphena major vein lies on the fascia.

b. On the leg the nerve is found throughout its entire length along the inner edge of the tibia beside the saphena major vein, in the line of the incisions made for the ligation of the tibialis postica artery.

c. At the ankle joint the nerve is palpable beside the saphena major vein at the anterior circumference of the internal malleolus.

167. *Suralis Externus Nerve* (*Communicans Peronei*). *At the upper end* (Figs. 72 and 73) the nerve is exposed by the same incision as the trunk of the peroneal nerve, close to the biceps tendon, directly under the fascia.

At the Lower End (Figs. 76 and 77).—Incision midway between the external malleolus and the Achilles tendon. Here the nerve is subfascial, having united with the communicans tibialis to form the external saphenus nerve. The saphena minor vein lies beside it.

168. *Tibialis Posticus Nerve* (Figs. 78 and 79).—To be exposed in the entire length along the tibialis postica artery; being laterally from it above, posteriorly below, and inferiorly in the sole of the foot (*i.e.*, nearer the skin).

169. *Suralis Medius Nerve* (*Communicans Tibialis;* Figs. 72 and 73).—See Ligation of the popliteal and tibio-peroneal arteries. In the upper two-thirds of the leg the nerve descends vertically on the fascia with the saphena minor vein, in the middle of the calf.

The Foot.

Plantar Arteries and Nerves.—In the median line of the sole of the foot the deeper structures are covered by the body of the flexor brevis muscle. Analogous to the palm of the hand, therefore, we enter alongside of this median bundle and the two lateral muscular eminences. The latter consist superficially of the abductors of the great and little toe.

170. *The Plantar Arch at the Intermetatarsal Interspace* (Fig. 82).—Incision in the depression laterally from the ball of the great toe, in the direction of a line from the second toe to the tuberosity of the os calcis, backward through the skin, the abundant adipose tissue, and the tense plantar aponeurosis. The internal plantar nerve is exposed with its thick branches. It is to be drawn toward the inner margin of the foot. The tendon of the flexor digitorum brevis to the second toe, and at its medial margin and more deeply that of the flexor digitorum longus with the first lumbrical, are exposed and drawn laterally. Under these is the thick adductor hallucis muscle. Rather deeply under the latter muscle we strike the point where the artery passes through the first metatarsal interspace.

171. *Internal Plantar Artery and Nerve* (Figs. 82 and 83).—Incision in the direction from the tip of the tuberosity of the os calcis to the first toe (Fig. 83), from the anterior circumfer-

ence of the eminence of the heel forward through the skin, the abundant fat, and the firm plantar aponeurosis with its longitudinal fibres.

The body of the abductor hallucis is exposed. The flexor brevis digitorum lies laterally. The vessel and

172. *The internal plantar nerve* are situated under this muscle. The artery is very small, the nerve thick and covered with abundant fat. The tendon of the flexor hallucis longus lies under these structures.

173. *External Plantar Artery and Nerve* (Figs. 82 and 83).—Incision in the course of a line from the tip of the tuberosity of the os calcis to the fourth toe, forward from the eminence of the heel through the skin, the abundant fat, and the thick plantar aponeurosis. The body of the flexor brevis digitorum is exposed, between which and the short head of the flexor longus the artery and

174. *The external plantar nerve* appear laterally, the former very thick, the latter narrow. The deeper tendons are not exposed.

175. *Plantar Arteries at their Origin from the Tibialis Postica Artery* (Figs. 78 and 82).—Incision beginning on the medial side of the foot, one finger's breadth under the palpable sustentaculum tali, extending horizontally backward. Division of the skin and the ligamentum laciniatum, under which the body of the abductor hallucis is exposed. This is lifted from the inner surface of the os calcis. The two arteries with the plantar nerve rest on the flexor tendons.

176. *Dorsalis Pedis Artery* (Figs. 74 and 75).—Course, from a point midway between the two malleoli to the first metatarsal interspace.

At its Entrance into the Metatarsal Interspace.—Incision between the bases of the first and second metatarsals. The skin and fascia are divided, sparing a branch of the superficial peroneal nerve which is drawn laterally, as is also the saphena

major vein. In a median direction appears the tendon of the extensor hallucis brevis, and still farther medially the thick tendon of the extensor hallucis longus. Under the lateral mar-

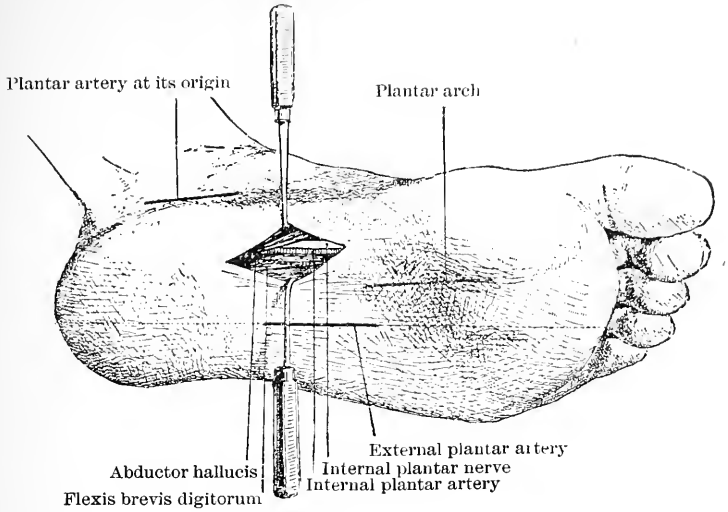

FIG. 82.—Internal Plantar Artery and Nerve.

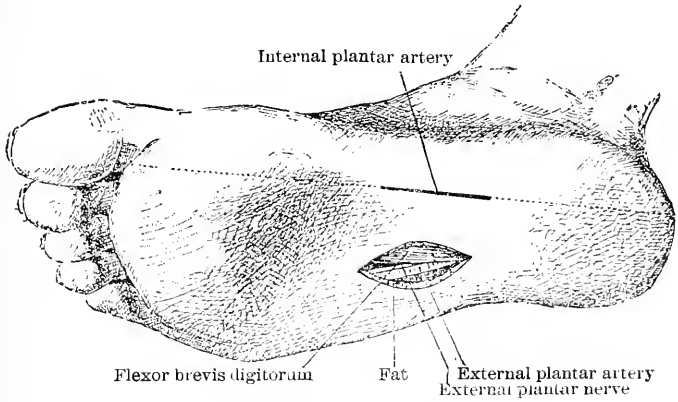

FIG. 83.—External Plantar Artery and Nerve.

gin of the former the deep peroneal nerve emerges and under it the artery, a thick interdigital branch of which passes forward.

Midway on the Dorsum of the Foot.—Incision in the above-named direction. On the fascia the superficial peroneal nerve is drawn outward. Under the fascia we expose the tendon of

the extensor hallucis longus, and laterally the tendon and body of the extensor hallucis brevis muscle. The latter is drawn laterally downward, and the artery is found beneath; the deep peroneal nerve, which is rather thick, being on its external side. The artery rests on the articular ligaments.

In the Line of the Ankle Joint.—The skin is divided midway between the two malleoli. The superficial peroneal nerve appears in the direction of the incision and is drawn outward. We open the fascia with the ligamentum cruciatum above the tendon of the extensor hallucis longus; this muscle, which still contains muscular fibres, is drawn in a median direction. Beneath it is the artery, outward and forward of it the deep peroneal nerve.

PART III.

EXCISIONS (RESECTIONS).

T. General Observations.

DEFINITE types of operation can be laid down for the excision of the bones and joints. As regards the soft parts it is not worth while to separate excisions from incisions, unless the pathological side of the subject, especially tumors, is to be considered at the same time. By excision is meant the removal of a portion of an organ or member from the continuity of an organ or part of the body. In the case of the joints it is customary to employ for the operation the special term "resection." Resections form the greater portion of this part of the book; as to the excision of bones we shall restrict ourselves in the main to the total removal of the small bones.

As regards the technique, excisions belong to the simplest operations. For as soon as the part in question is once laid bare, the task is to enucleate it as thoroughly as possible from its surroundings, the adjoining soft parts being immediately detached from the bone (when such is the one to be resected) with sharp or blunt instruments. The resection is correct in proportion to the thoroughness with which the bone is laid bare, *i.e.*, in inverse proportion to the number of soft parts adhering to it. This simple rule is largely violated by beginners in the practice of resection.

The point which will be again emphasized under amputations in connection with Ollier's subcapsular and subperiosteal method, is the most important requirement here for the incisions in the depth. In recent years surgeons have even gone beyond this

subcapsulo-periosteal method of resection (König, Bergmann, Riedel, Tiling) and have recommended instead of the detachment of the ligaments, particularly the lateral ones, the chiselling away of the bony processes (tubercles, trochanters, condyles, malleoli), a sort of osteoplastic resection. Ollier made use of this method even earlier in isolated cases; we employ it for the resection of the shoulder and partly of the elbow.

The only difficult and important portion of the operation is the correct location of the first incision. This must answer the requirement of giving perfectly free access to the depth. This access is to be direct, and moreover in the division of the overlying soft parts no unnecessary incidental injury should be caused. Therefore, not only should larger vessels and nerves be spared, but even muscles and tendons should be avoided, and in choosing interstices between muscles and tendons—a point upon which we lay particular stress—only those should be selected which correspond to the borders of nerve distribution. If the function of a muscle is to be preserved, its motor nerve must remain intact. This consideration is decisive for the method of resection.

U. Lower Extremity.

177. *Excision of the Phalanges of the Toes and the Metatarsal Bones* (Fig. 84).—According to the statements made in connection with incisions on the toes and fingers, it is evident that only lateral incisions closer to the dorsum are admissible in order to spare nerves and tendons. On the toes and their joints it is more conservative as regards the performance of the operation, and more suitable with reference to the cicatricial retraction, to make two smaller lateral incisions; for the metatarsal bones a dorsal incision along the extensor tendons and the digital branches of the peroneal nerves is sufficient. The incision must extend beyond the adjoining joints if it is to

afford ample room. The head of the bone is always first laid bare because its ligamental connections are more easily detached than those of the base.

178. *Metatarso-Tarsal and Anterior Tarsal Resection* (Figs. 84 and 85).—This is a very important operation in infectious diseases (especially tuberculosis) of the anterior tarsal



FIG. 84.—Resection of the Phalanges. Resection of the Metatarsal Bones.

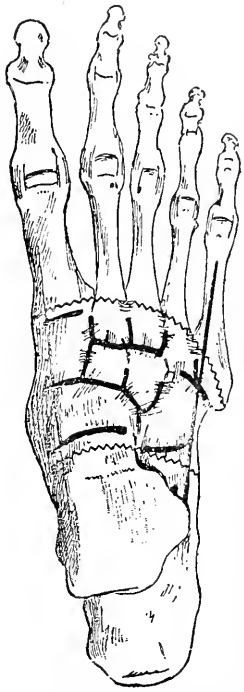

FIG. 85.—Anterior Tarsal Resection (Usual Arrangement of the Joint Capsules).

joints because, as a rule, all their capsules communicate with one another. Closed capsules are found most frequently at the joint between the first metatarsal and the first cuneiform, at the anterior and posterior surface of the cuboid, between the head of the talus and navicular bone, the talus and calcaneus. Tubercular ostitis frequently begins in the base of the metatarsal bones, and then occasionally a resection of the bases of the metatarsal bones and the articular surfaces of the adjoining cuneiform bones and

the cuboid may suffice (metatarso-tarsal resection). If the joints are involved, the simultaneous removal of the last-named bones together with the navicular will be more certain. In diffuse disease the articular surfaces of the talus and calcaneus are to be likewise removed.

The resection is made from two dorsally placed lateral incisions. The medial incision extends from the posterior third of the first metatarsal to the inner circumference of the head of the talus which becomes visible when the foot is abducted. At the latter point the incision is carried through the skin only, lest the ankle-joint capsule be opened, which reaches to the neck of the talus. The incision, beginning in a median direction from the extensor tendon of the great toe, divides the attachments of the tibialis anticus to the first metatarsal and the first cuneiform bone and frees the dorsal surface of the cuneiform and navicular bones. Downward, the lower surface of the latter bone is freed in the same way; the tendon of the tibialis posticus is left postero-inferiorly.

The lateral incision, passing from the posterior third of the fifth metatarsal to the upper surface of the body of the calcaneus in front of the external malleolus, remains lateral from the tendons, by separating the attachment of the peroneus tertius from the fifth metatarsal and freeing the upper surface of the metatarsal bases and the cuboid bone. In order to expose the lower surface of this bone the tendon of the peroneus brevis must be detached from the fifth metatarsal and that of the peroneus longus lifted from the groove at its outer and lower surface and drawn backward.

Then follows the removal of the bases of the metatarsal bones and the articular surface of the talus and calcaneus.

The shortened foot continues exceedingly useful both as regards support and locomotion.

179. *Intertarsal Resection* (Fig. 86).—This operation is relatively frequent for clubfoot. The incision follows the cutaneous

folds transversely over the line of the joint on the anterior outer side; the tendons of the anterior surface, exteriorly that of the peroneus tertius, being drawn in a median direction; on the outer side the tendon of the peroneus longus is lifted from the groove of the calcaneus and cuboid bones and drawn backward. The extensor digitorum brevis muscle is separated at its upper margin from the bone and drawn forward and downward. The joint capsule is then incised in Chopart's line and as a rule the entire navicular bone, a portion of the cuboid, the

FIG. 86. — Medio-tarsal Resection (Wedge-shaped Excision in Clubfoot).

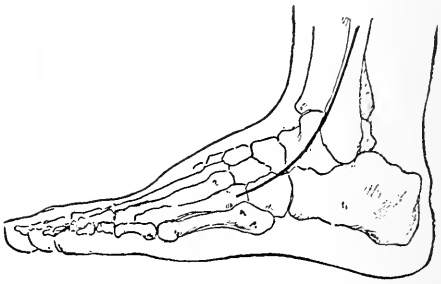

FIG. 87.—Excision of the Talus (Outer Side).

calcaneus, and the head and neck of the talus are cut through subcapsulo-periosteally (in children with the chisel) so that the foot can be straightened slightly beyond a right angle, the supination and adduction being corrected. Suture without drainage, immediate closed plaster dressing in good position.

180. *Excision of the Talus* (Fig. 87).—While it appears to be unnecessary to give definite directions for the excision of the small tarsal bones which is occasionally required, an exception must be made of the talus and calcaneus, whose removal is more frequently performed for tuberculosis, injuries, and club-foot. The latter two indications apply especially to the talus.

As a rule a free longitudinal incision on the anterior outer

side suffices, such as the one given by Vogt for the resection of the ankle joint.

Beginning a hand's breath above the ankle joint at the anterior surface of the fibula, it passes on the outer side of the extensor tendons (peroneus tertius), leaving the branches of the superficial peroneal nerve in a median direction, over the lateral margin of the pulley of the talus which is readily felt in adduction, as far as the tuberosity of the fifth metatarsal; it penetrates into the ankle joint and Chopart's articulation, exposing the pulley and head of the talus. On the neck of the talus the

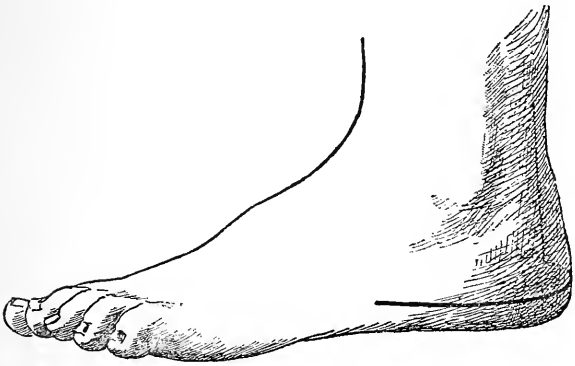

Fig. 88.—Excision of the Calcaneus.

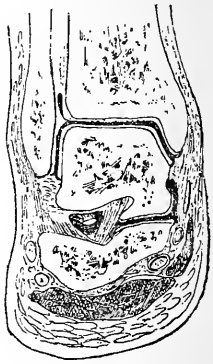

Fig. 89.—Frontal Section of the Ankle Joint, after Henle.

attachment of the anterior and posterior joint capsules is freely separated toward both sides and in the sinus of the tarsus laterally the tense interosseous ligament is divided. Along the anterior margin of the tibia and fibula the joint capsule is detached, and laterally at the anterior and posterior end of the talus pulley the ligamentum talo-fibulare anticum and posticum is divided. Externally and along the posterior margin of the talus the capsular connection with the calcaneus is separated. In a forced adduction position the talus can now be lifted far enough to permit the insertion of an elevator beneath it so that the attachments of the ligaments and capsules on the inner side can be separated.

181. *Excision of the Calcaneus* (Figs. 88 and 89).—Where the soft parts are flexible, sufficient room is furnished by a longitudinal incision on the medial side close to the Achilles tendon downward to the lowest posterior end of the tuber calcanei, and thence transversely across to the outer side as far as the tuberosity of the fifth metatarsal.

At the posterior root of the tuber the Achilles tendon is detached, the joint capsule at the postero-external circumference of the calcaneus is severed together with the calcaneo-fibular ligament; the peroneal tendons in the tarsal sinus being drawn up, the interosseus ligament is divided, and the joint capsule to the cuboid bone infero-externally detached together with the

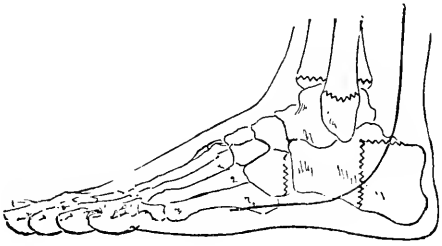

Fig. 90.—Posterior Tarsal Resection.

firm calcaneo-cuboid ligament. The heel-cap is vigorously drawn over to the medial side, the tendon of the tibialis posticus is freed below at the sustentaculum tali and lifted up, and finally the attachment of the joint capsule to the talus, with the covering deltoid ligament (ligamentum calcaneo-tibiale) and in front the stout ligamentum tibio-calcaneo-naviculare, is separated. The bone must be seized with strong forceps.

182. *Talo-Calcaneus and Posterior Tarsal Resection* (Fig. 90).—The resection of the articulation between the talus and calcaneus has been performed by Annandale, by means of two lateral curved incisions, and it can be done by the method described for the excision of the calcaneus or the modified method for the posterior tarsal resection.

The posterior tarsal resection, which is associated with re-

moval of the talus and calcaneus and possibly the adjoining articular surfaces, furnishes unexpectedly good results with the foot in normal position, the leg bones descending to fill the defect (Kocher, Kummer).

The procedure, according to the method to be described, is based on the possibility of preserving the tendons and muscles moving the foot (peronei, tibialis anticus and posticus).

Incision beginning a hand's breadth above the ankle joint on the outer side beside the Achilles tendon, extending downward behind the external malleolus and the peroneal tendons as far as the tuberosity of the fifth metatarsal. From this incision the tendon sheaths of the peronei are opened, these tendons lifted forward, and in a manner analogous to that described for the excision of the talus and calcaneus these two bones are exarticulated; then the articular surfaces of the leg bones and of the cuboid and navicular are ablated. It is desirable to preserve a small projection of the external malleolus for the purpose of hooking the peroneal tendons behind it.

If the tuber calcanei can be preserved, it may be utilized for osteoplastic purposes in an analogous manner to that of Pirogoff in amputation of the foot. It will be sufficient to illustrate this case by the lines of the saw in the adjoining figure.

183. *Resection of the Foot* (Figs. 91 and 92).—The resection in the talo-crural joint does not always give satisfactory results, owing to the complicated structure of the joint, the frequent involvement of the directly adjoining bones, and of the neighboring talo-tarsal articulation with its bones, especially the calcaneus. Hence the efforts directed to the continual improvement of the technique. Incisions have been made on all sides of the joint, in every direction.

Anterior longitudinal incisions are made by Vogt (lateral), König and Riedel (bilateral with chiselling away of the malleoli), Meinhardt Schmidt (conjoined with posterior); anterior transverse incisions by Hüter, formerly by Sabatier, Heyfelder,

Hancock; posterior transverse incision by Liebrecht, conjoined with posterior longitudinal incision by Wackley, Textor; inferior "stirrup-heel" incision by Busch, Hahn, Ssabanejew (with detachment of the tuber calcanei); lateral incisions, in part associated with transverse incisions, by Moreau, Langenbeck, Ollier, Chauvel, Girard.

We recommend the external lateral transverse incision (Reverdin, Kocher). The incision (see Fig. 91) begins at the height of the ankle joint, extending from the outer margin of the extensor tendons, or the still fleshy peroneus tertius, in a

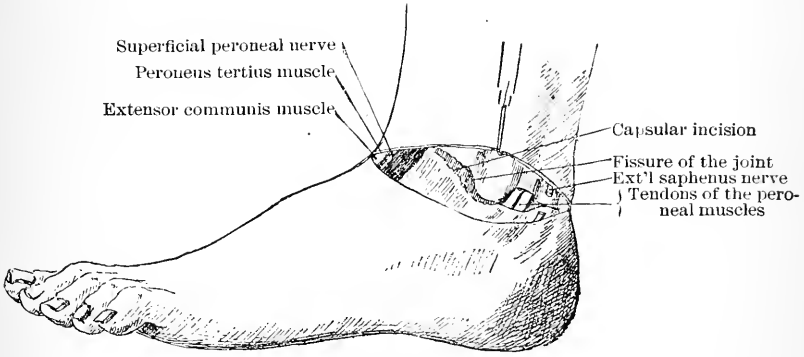

FIG. 91.—Resection of the Foot.

curve over the tip of the external malleolus as far as the Achilles tendon, leaving the latter intact. Skin and fascia are divided; in front the superficial peroneal nerve is preserved and drawn aside together with the extensor tendons; posteriorly we must preserve the external saphenus nerve, lying behind the peroneal tendons, which is formed by the union of the communicans peroneus and tibialis and supplies the outer side of the foot, also alongside of the Achilles tendon cutaneous branches passing to the heel, and the saphena minor vein. Where these structures cannot be preserved they may be divided without causing material injury.

In front the incision now extends between the extensors and the fibula into the joint, and, the extensors being forcibly ele-

vated, separates the capsular attachments along the anterior margin of the fibula and tibia to the internal malleolus and from the pulley of the talus at the neck of this bone as far medially as possible. The dorsal artery of the foot, lying on the joint capsule with the deep peroneal nerve, remains intact.

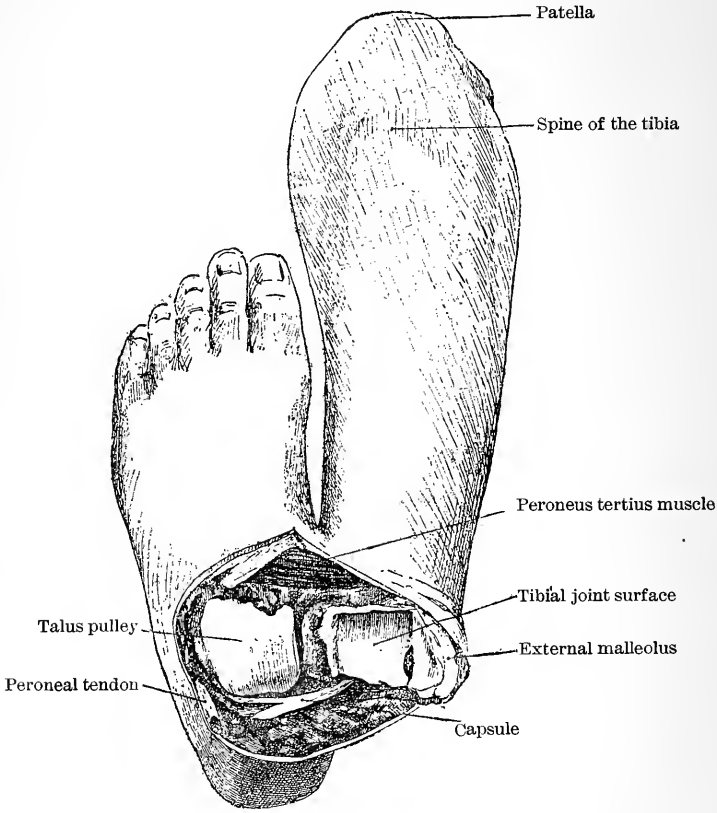

Fig. 92.—Resection of the Foot.

Close around the external malleolus the capsule and ligaments are detached throughout, the latter especially also from the inner surface of the malleolus where they knit the joint with great firmness. At the tip and the posterior margin of the external malleolus the separation of the ligaments is associated with the opening of the sheath of the peronei, posteriorly upward above the line of the joint, so that the tendons can be

drawn away with a strong hook. Should the latter be difficult, the tendons are severed and subsequently sutured in order to prevent the occurrence of pes calcaneus. Then the lower wall of the tendon sheath and, with it, the joint capsule are opened as far as the tibia, and at the posterior margin of the latter to the internal malleolus. Unless this is done thoroughly the succeeding step is made difficult.

The next step is as follows. The foot which has been freed on the entire external, anterior, and posterior circumference from its capsular connection with the fibula and tibia, is forcibly turned medially over the internal malleolus, *i.e.*, it is luxated totally inward in such a way that the sole points upward at the inner surface of the leg and the inner margin of the foot touches the inner margin of the tibia, as shown in Fig. 92.

In this manner we gain an absolutely unobstructed view into the joint; nothing remains to be done but to sever the ligaments at the projecting tip of the internal malleolus (carefully, lest we injure the tendons descending behind the malleolus) to permit inspection of all the recesses of the articulation. It will then be easy to clear the joint and resect the talus. If the latter is to be preserved, we must guard against unnecessary opening of the talo-calcaneal joint, sparing the capsular attachments at the posterior and lateral circumference of the talus.

The method described preserves the ligamental apparatus on the medial side and the support of the external malleolus on the outer side, and therefore guards as well as possible against lateral deviations of the foot.

184. *Total Tarsal Resection* (Figs. 93 and 94).—Wladimiroff and Mikulicz have added to our measures for the preservation of the foot, even in very extensive disease, a procedure used by them in affection of the posterior tarsal bones and joints. In such a case we believe the method to be superfluous, provided the soft parts of the sole and heel can be preserved. But aside from this the method is especially valuable in disease

of all the tarsal joints or bones. It enables us even in such a case to preserve a foot useful without prothesis by attaching, after excision of the entire tarsus, the sawed bases of the metatarsal bones to the sawed surface of the leg bones, the foot being in vertical position (in the prolonged axis of the leg). The patient walks on the anterior surface of the heads of the metatarsals, the toes being forcibly dorsoflected. If the navicular and cuboid bones can be sawed off, or the latter divided with the cuneiform bones, a broader and firmer sawed surface is obtained.

In the same way as Pirogoff turns the posterior segment of the foot 90° and attaches it as a prolongation to the leg, so does this method with the anterior segment.

Since Mikulicz's method starts with a presupposed defect of the skin of the heel—*i.e.*, with quite a special case in which the direction of the incision is a natural result—we prefer to describe the method for the typical case of disease of the entire tarsus with a useful integument.

Incision quite analogous to that for posterior tarsal resection, in the form of a lateral posterior curved incision, beginning as in Fig. 93 a hand's breadth above the ankle joint, extending downward behind the external malleolus and the peroneal tendons to the middle of the fifth metatarsus. In the above-described manner the bones and joints between the leg and metatarsus are exposed, the Achilles tendon being detached with the periosteum of the calcaneus, and the peroneal tendons lifted from their sheath and drawn forward. The vessels and nerves are preserved, the tendinous attachments of all the long foot muscles (peroneus tertius, brevis, and longus) are separated from the upper, outer, and lower surface of the metatarsal bones, and the attachments of the tibialis anticus and posticus from the upper, medial, and lower surface of the same bones.

185. *Resection of the Lower Third of the Leg* (Fig. 95).—In the case of extensive disease in the lower third of the leg bones, an attempt should be made, if possible, to expose the dorsal

surface of the tuber calcanei by a very long latero-posterior incision and to attach it to the correspondingly freshened sawed surface of the tibial diaphysis.

186. *Resection of the Tibia.*—In a case in which an exten-

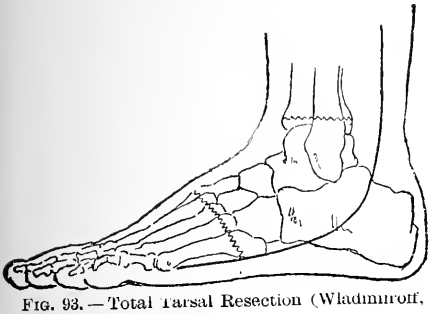

FIG. 93.—Total Tarsal Resection (Wladimiroff, Mikulicz).

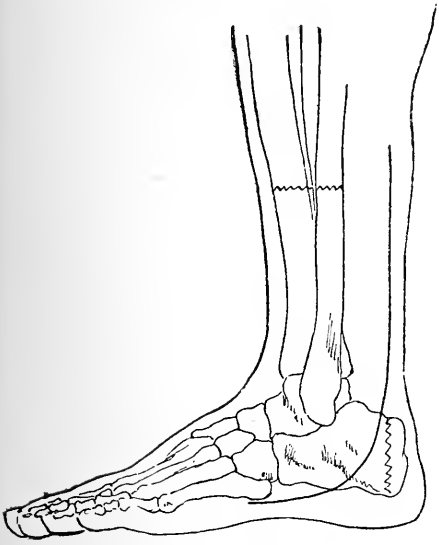

FIG. 95.—Resection of the Leg (Lower Third).

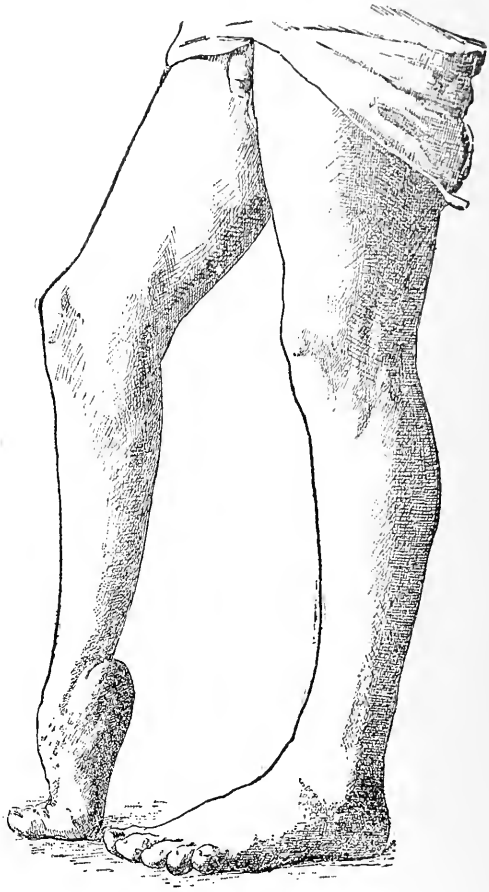

FIG. 94.—Case of Total Tarsal Resection; Personal Observation (after a Photograph).

sive portion (the middle third) of the tibial diaphysis had to be resected for necrosis, the diaphysis of the fibula on the other side was removed by us and inserted into the excavated remnant of the tibia.

187. *Resection of the Fibula.*—The diaphysis and even the

whole fibula can be removed by an incision behind the peroneal muscles in their entire length, without damaging the usefulness of the leg for support or locomotion or impairing the movements of the foot in any direction. At the upper end we must preserve the peroneal nerve which curves around the neck, in the lower half the peroneal artery which passes behind the fibula.

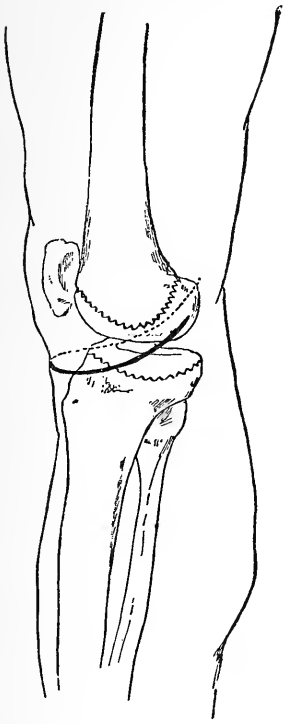

Fig. 96.—Resection of the Knee.

188. *Arthrotomy and Resection of the Knee* (Figs. 96, 97, 98).—Numerous methods for free opening of the knee joint have been devised, all of which we have tested. None of them however, gives absolutely sufficient access in so simple a manner as the transverse incision with lower convexity; to be sure, it must be carried laterally far enough backward to embrace at least two-thirds of the circumference of the knee. It is not quite clear to which surgeon belongs the merit of its introduction, as Park appears to have made the proposition and Textor is named as the father of the method. At all events Erichsen seems to have contributed to its general acceptance. It is certain, however, that after the skin has been divided by a transverse incision, the subsequent steps of the operation have been performed in widely varying ways. It is the latter which determine the final result.

Different procedures are required for arthrotomy and arthrectomy of the knee joint and for resection; for, contrary to all other joints, in resection we aim at ankylosis (in good position), while in arthrotomy the possibility of recovery with mobility is to be kept in view.

Resection of the Knee.—In a case of knee-joint disease doomed *ab initio* to resection, the skin and especially the tense

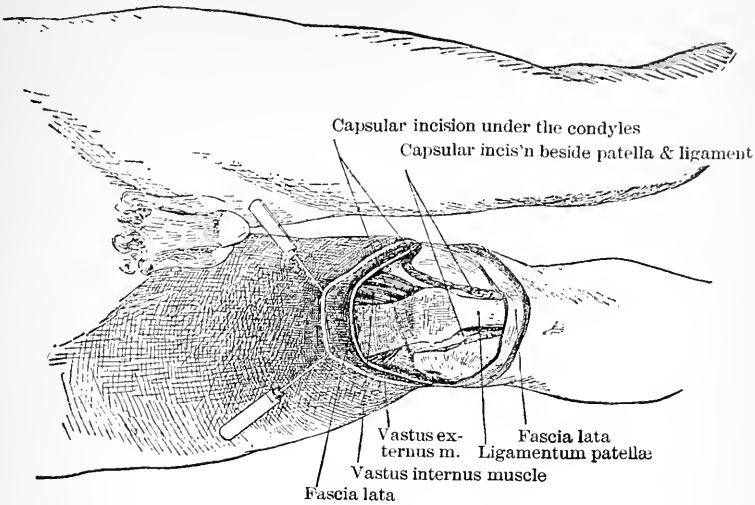

FIG 97.—Arthrectomy of the Knee.

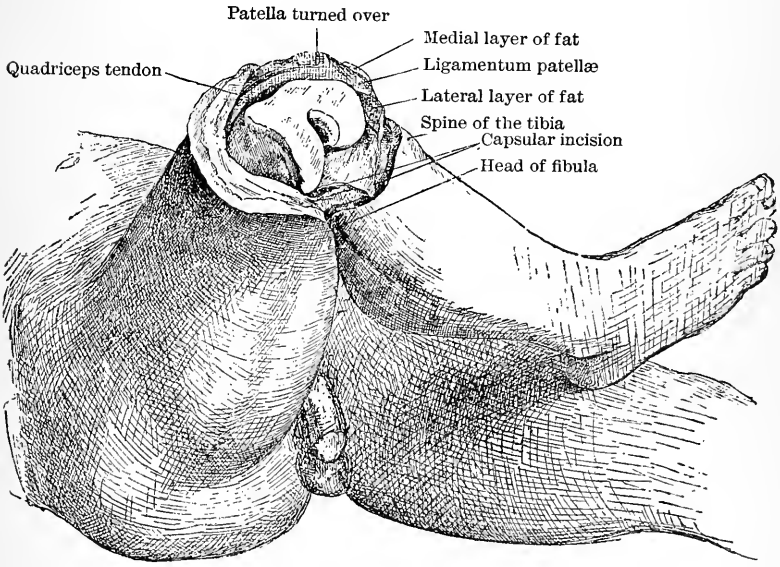

FIG. 98.—Arthrectomy of the Knee.

fascia lata are divided transversely and dissected up above the patella. The tendinous expanse of the vasti together with the

stout quadriceps tendon is divided by an incision curving around the upper circumference of the patella, but reaching only to the outer surface of the capsule. The latter is then traced upward, outward, and backward along its outer surface to its attachment and reduplication at the femur; with the visceral serosa it is dissected from the bone as far as the cartilaginous margins of the femur on the whole outer surface, also backward below the condyles, the attachment of the lateral ligaments being separated. In like manner the tendinous fascia is dissected downward until the attachment of the capsule to the tibia is completely exposed from without. During this step the ligamentum patellæ and the lower attachment of the lateral ligaments are severed. Then the capsule is here, too, separated all around from the margin of the tibia to the cartilaginous surfaces and the menisci divided at the same time. In this way the entire anterior and lateral surface of the capsule with the covering patella and the ligamentum patellæ are withdrawn in connection like a tumor, without the necessity of cutting into morbid tissue.

Most surgeons make it a rule to continue the transverse incision at once into the joint, the ligamentum patellæ being severed. It is obvious that this is no advantage in infectious and particularly tuberculous effusions into the joint; and as in this procedure the patella with the quadriceps retracts upward, the excision of the pouch under the quadriceps is rendered more difficult as compared with our method.

We always remove not only the patella, but we also divide the crucial ligaments and excise the menisci and ligaments. Ollier's subcapsulo-periosteal method is not justified here for any surgeon who aims at ankylosis of the knee. The patella and its ligament as well as accessory ligaments contribute comparatively little to the firmness of the joint, and everything depends upon securing a very firm union of the bones so as to obtain a perfectly useful extremity. If this is not effected, the

results, as a rule, will remain defective despite patella and ligaments. This is apparent even from the fact that when ankylosis results in young patients after pure arthrectomy with preservation of the entire extensor apparatus, strongly flexed positions are secured, fully equal to those after resection in which the entire joint with the patella has been extirpated. For this reason we do not use Volkmann's transverse incision through the patella, particularly because we agree with Böckel that the patella itself is but too often involved in the disease.

Therefore, contrary to Ollier, we here positively avoid the subperiosteal operation and make the simplest possible wound, covering the exposed and sawed bones merely with skin, fascia, and muscle; for, as we have stated, we have learned to rely absolutely on the bony ankylosis. Not that we have failed to observe that the contraction of the quadriceps is preserved; but in ankylosis of the knee the vasti no longer produce any result, and the rectus femoris inverts its effect and acts merely on the thigh as a flexor in the hip joint.

Room having been made by the excision of the entire anterior and lateral walls of the joint, it is easy to extirpate the posterior wall during strong flexion. To this end the crucial ligaments must be separated, best at their attachment in the intercondyloid fossa or close to the bone at the adjoining condyloid surfaces of the femur. Then we can reach the dorsal surface of the condyles of the femur and tibia and effect the exact removal of the macroscopically diseased tissue, possibly also excise *in toto* some mucous bursæ, especially the popliteal. A clean wound surface remains which is thoroughly disinfected before the bones are sawed off, or dusted with iodoform in tuberculosis so as to prevent the further development of infectious materials left behind.

In view of the expected firm ankylosis of exactly coapted bones, a very essential point is the manner in which the bones are sawed. In order to prevent the forward displacement of the femur on the tibia, all sorts of angular cuts have been made

on the one hand, and attempts at fixation between the sawed surfaces on the other hand. Nails have been used for fixation or sutures have been applied. But as these often tore out and failed to answer the purpose, Albert of Vienna and others have made angular cuts. We as well as Metzger and Fenwick have succeeded best by sawing the femur convex and the tibia correspondingly concave. The latter author attaches great value to the method, as shown in a paper published in 1871, and subsequently he reported twenty-eight cases with very good functional results. Of course the surgeon must be master in the handling of the saw, but then the two surfaces can be so fitted together that any further artificial fixation becomes quite unnecessary; provided, however, that the leg is fastened to a splint in complete extension. The curved sawing of the femur has another advantage in that its epiphyseal line, which determines the future growth, is most certainly preserved. After the bones are coapted, a simple deep cutaneous suture is inserted, drainage tubes having been passed through special openings. In numerous cases during the last few years we have obtained by this operation perfect adhesion by first intention as in simple wounds of the soft parts, so that in one or two weeks a permanent silicate-of-soda dressing could be applied as for simple subcutaneous fracture, and the patient could get up six weeks after the operation.

Arthrotomy of the Knee.—As resection of the knee differs from the type described for resections in general, special mention must be made of the method in which ankylosis is not desired. In cases of arthrotomy and arthrectomy in which there is any prospect of a movable joint we have come to the conclusion, after various experiments, that every breach in the continuity of the extensor apparatus of the knee joint is harmful. No matter how exact is the suture of the ligamentum patellæ, of the patella, or of the quadriceps tendon, or how good is the course of the wound, we can never expect or attain as

rapid and vigorous contractions of the quadriceps as when that muscle with its tendinous apparatus has been kept quite intact as far as the spine of the tibia. And this latter mode can be executed even in very extensive disease without greatly complicating the operation and especially without diminishing the certainty that all morbid parts of the joint will be removed. We proceed in the following manner:

Anterior curved incision, beginning latero-posteriorly over the line of the joint, extending through skin and fascia, which are detached as flaps from the anterior surface of the patella and its ligament, as in resection. But instead of severing the quadriceps tendon transversely above the patella, we expose obliquely upward the margin of the vastus internus and externus. Then we divide the capsule at the margin of the patella alongside of the latter and the ligamentum patellæ, separate its attachment to the femur externally and posteriorly (Fig. 97), together with the attachment of the internal and external ligaments to the femur to a point behind and above the condyles, and turn the capsule downward. Now the patella can be easily luxated first laterally, then medially, and the joint opened wide enough to permit inspection of its greater portion. If all the folds are to be inspected, we must separate the attachments of the crucial ligaments between the condyles of the femur as during resection. Then all the recesses of the joint are open to view. The last-named ligaments remain in connection with the tibia below, and above with the periosteum of the dorsal surface of the femur, and therefore adhere in good position. According to requirements we can now extirpate the entire synovial membrane or excise circumscribed patches. Finally the patella is turned over and freed from adhering fungous granulations, or diseased bone is thoroughly removed, and the posterior surface of the quadriceps tendon cleared of any remnants of the diseased bursa. If the popliteal and semimembranosa bursæ are degenerated, they can be cleaned in

the same manner. The cartilages are cut off whenever or wherever they are at all discolored or softened by penetrating granulations. Special care should be taken lest diseased patches in the bone be overlooked, for they must be thoroughly scraped out.

Where the capsule has been preserved it is carefully sutured, then the flaps of skin and fascia are brought in contact by some deep sutures, and after the insertion of drainage tubes the continuous cutaneous suture is applied. In order to insure permanent recovery in tuberculosis, iodoform is dusted in; or else, after temporary iodoform tamponade, we may follow the method recommended by us and recently somewhat modified by Bergmann, Sprengel, Helferich, and others; namely, cutting a few primary temporary deep sutures, and inserting an exact uninterrupted secondary suture after the lapse of twenty-four or even forty-eight hours. By that time all after-hemorrhages have ceased. The temporary sutures have the advantage of preventing the retraction of the skin and fascia.

Irregular resections and excisions of the knee joint, for instance, of one condyle of the tibia or femur, are permissible only when we are sure of an ankylotic union of the remaining condyle with the opposite bone.

189. *Resection of the Patella.*—In primary disease of the patella this is an important operation for the prevention of diffuse affection of the joint. Longitudinal incision, separation of the covering quadriceps fascia and periosteum, and enucleation from the anterior wall of the capsule are the several steps of this simple operation. Its results are very satisfactory, for perfect mobility of the joint may be preserved (see reports by Dr. Kummer).

190. *Osteotomy and Cuneiform Resection of the Tibia* (Fig. 99).—Transverse incision (*i.e.*, in the cleavage line of the skin) two fingers' breadth below the line of the joint, extending from the spine of the tibia to the eminence of the calf muscles; the

periosteum is detached and the chisel applied in the direction of the cutaneous incision. The attachments of the ligamentum patellæ must not be injured, for between it and the tibia is a bursa mucosa which may communicate with the joint.

In pronounced genu valgum it is preferable to excise a wedge from the tibia whose base should be directed medially; otherwise, during straightening, there may be too much dragging upon the head of the fibula with consequent paralysis of the peroneal nerve which surrounds it.

191. *Supracondylic Osteotomy of the Femur* (Fig. 99).—The incision which follows the cleavage line of the skin is oblique both externally and internally, passing forward inferiorly from above posteriorly, through the skin and fascia lata, which is very thick, especially on the outer side. The vastus (internus or externus) is freed at its posterior margin and drawn upward; the periosteum is divided from the condyle upward and separated in front and behind; the bone is cut with the chisel for three-fourths of its thickness and the rest broken.

The superior internal or external artery of the knee joint must be borne in mind, on the inside especially the deep branch of the arteria articularis genu suprema. Next to Macewen, who developed this method into the normal procedure for genu valgum, we were the first to perform osteotomy of the femur for this affection.

192. *Osteotomy and Subtrochanteric Cuneiform Resection of the Femur* (Figs. 100 and 101).—Transverse incision through the skin, the fascia of the glutæus maximus, and the tendinous attachment of the vastus externus muscles to the bone at the outer side, at the level of the base of the great trochanter, so that the trochanter minor remains above the line of division. The terminal branch of the external circumflex artery runs parallel to the incision (see Ligations). The bone is cut with the chisel obliquely from above postero-externally to below antero-internally in order to prevent dislocation of the lower

fragment medially or forward from above, during forced abduction.

The operation is performed for the correction of adduction, flexion, and shortening following coxitis that has healed in bad position, also for old and congenital luxations of the hip joint.

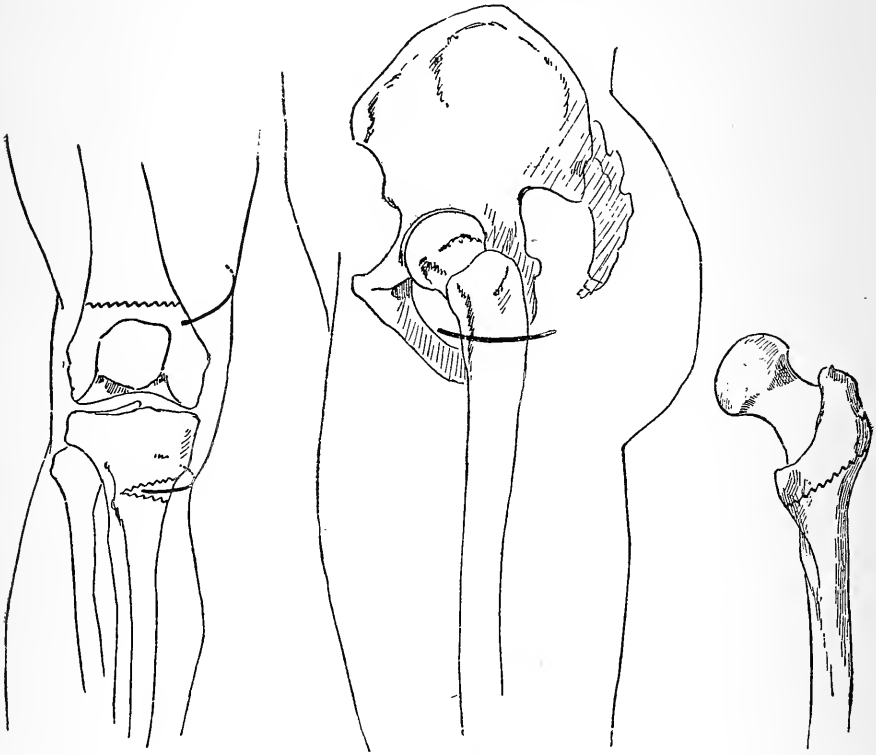

FIG. 99.—Osteotomy of the Femur. Cuneiform Osteotomy of the Tibia.

FIG. 100.

FIG. 101.

FIGS. 100 AND 101.—Subtrochanteric Osteotomy.

After-treatment in forced abduction with elevated pelvis and plaster dressing with double stocking.

193. *Resection of the Diaphysis of the Femur.*—Incisions can be made, without fear of incidental injury, on the outer side through the whole length of the bone, from the base of the great trochanter (where the terminal branch of the external circumflex artery passes under the vastus) to the external

condyle of the femur (where the external superior artery of the knee joint runs transversely around the bone, at the posterior margin of the vastus externus, between it and the biceps muscle).

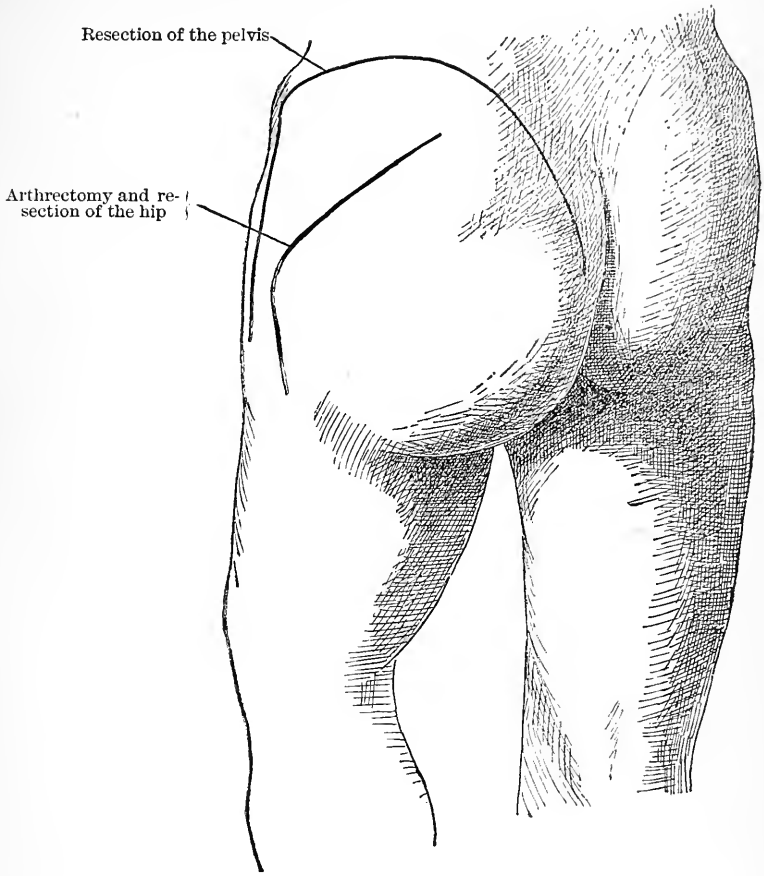

Fig. 102.

194. *Resection of the Hip* (Figs. 102, 103, and 104).—Angular incision, beginning at the base of the outer surface of the great trochanter, passing obliquely upward to the anterior point of the trochanter, thence bending at an angle in the direction of the fibres of the glutæus maximus, and extending obliquely upward and medially through the skin and the often abundant

adipose tissue. Usually at the base of the great trochanter larger branches of the external circumflex artery are cut and ligated. On the outer surface of the great trochanter the fascia of the glutæus maximus muscle is severed, thus exposing the

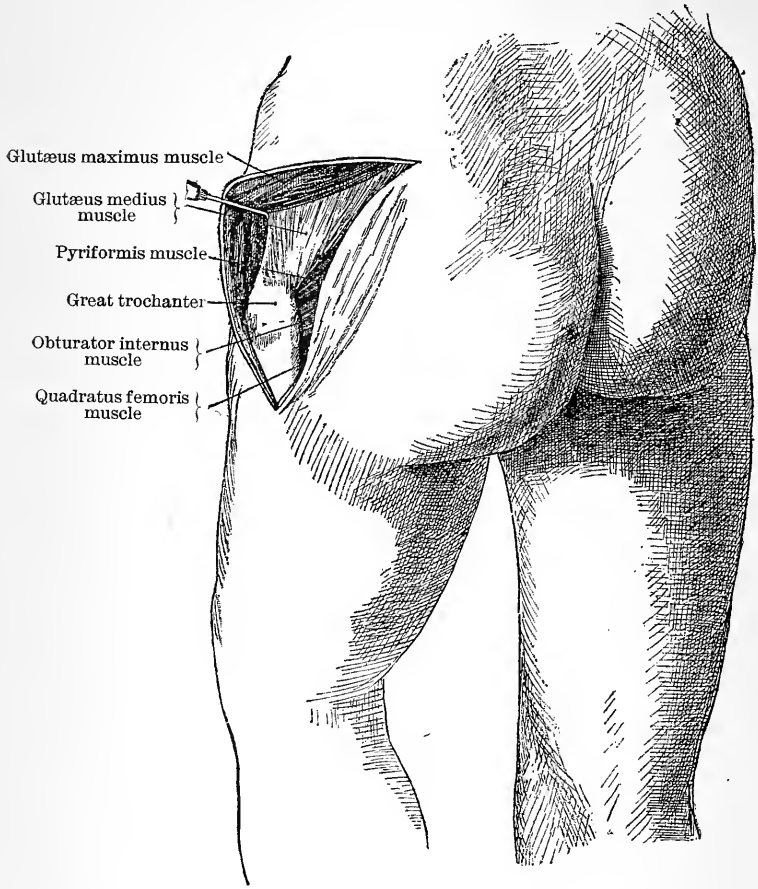

FIG. 103.—Resection of the Hip.

periosteum and the attachment of the glutæus medius muscle which covers the whole of the tip of the trochanter.

Upward and backward the incision divides the fibres of the glutæus maximus, and usually in the upper portion some larger vessels are cut and must be ligated.

The layer of fat thus laid bare is separated, and at the lower

margin of the glutæus medius we reach the interstice between this muscle and the glutæus minimus above and the pyriformis below. Entering here and drawing the pyriformis down, we immediately strike the posterior surface of the capsule of the

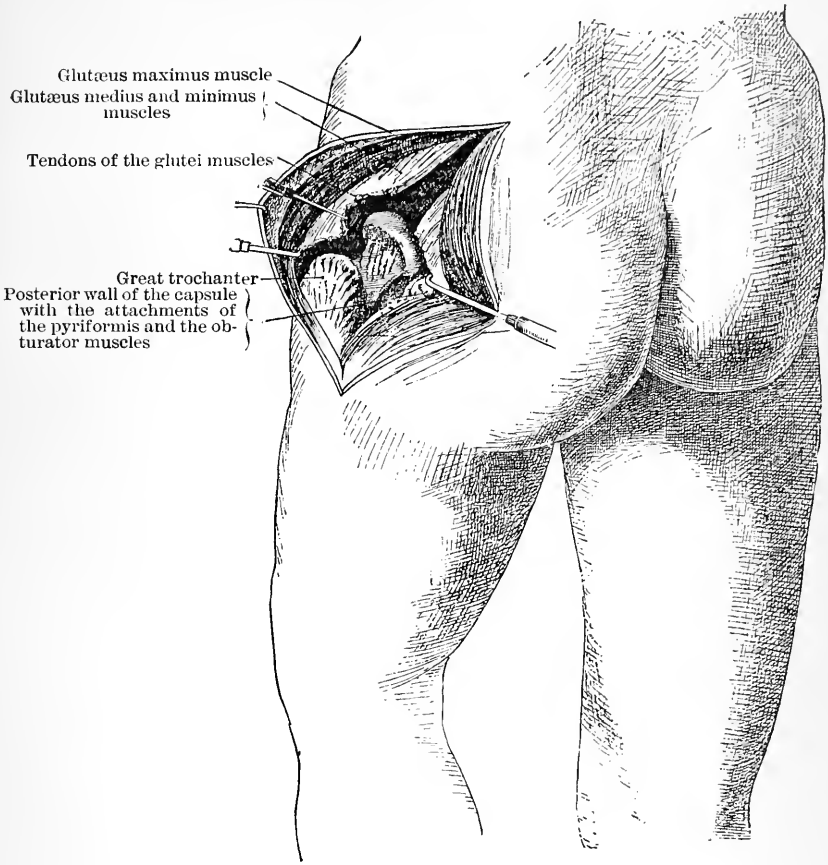

FIG. 104.—Resection of the Hip.

dorsal wall of the acetabulum. Anteriorly we follow the upper margin of the slender pyriformis tendon to the attachment of the glutæus medius to the great trochanter, and separate this forward in its whole extent close to the bone, *i.e.*, dissect it away from the upper point and the outer surface of the trochanter.

At the anterior margin of the great trochanter we separate the tendon of the glutæus minimus with the glutæus medius and draw these muscles forward with hooks. From the inner surface of the great trochanter and the trochanteric fossa we separate the tendons of the pyriformis, the obturator and gemelli, and finally the obturator externus, and lift these tendons with the periosteum from the inner and posterior surface of the trochanter, drawing them backward *en masse.*

In this way the muscles supplied by the superior gluteal nerve, viz., the glutæus medius and minimus, are crowded forward and upward toward the tensor fasciæ muscle, which is supplied by the same nerve and is of special importance for the subsequent abduction of the thigh; while the rest of the muscles, glutæus maximus, pyriformis, and obturators, which are mainly supplied by the inferior gluteal nerve, remain below. To be sure, the pyriformis muscle receives now and then a twig from the superior gluteal nerve, but in that case the branch is given off so high up that its injury is out of the question.

Thus the whole posterior surface of the head and neck of the femur is laid bare, with as much of the trochanter as is required, and we merely have to ligate some branches of the circumflex arteries which run transversely over the capsule of the neck and possibly the external circumflex at the base of the great trochanter, where it passes through the vastus externus and around the femur. If fungous granulations on the synovial membrane necessitate its excision, it will not be difficult to dissect it out for quite a distance from behind, before it is opened; to separate it from its attachment to the acetabulum and the neck of the femur, and to remove the posterior wall *in toto.* The thigh being strongly adducted, rotated inward, and flexed, the ligamentum teres is detached and the head luxated backward, and in this position the acetabulum is open to inspection. Fungosities are removed with forceps and scissors until the joint is thoroughly cleared.

Among the numerous methods for the resection of the hip joint we know of none which is equally conservative regarding muscles, nerves, and bone, and affords as thorough an inspection of the joint. It is a further development of Langenbeck's method, on whose oblique incision it is based, but which does not suffice, especially for the extirpation of the capsule alone with preservation of the bone. Hence we abstain from making comparisons with other modes of operation.

Fig. 105.

If arthrotomy alone is intended, the muscular attachments to the trochanter are not first separated, but the capsule is opened at once along the upper margin of the acetabulum as far as the neck of the femur, and with the capsule the periosteum and muscular attachments are separated from the neck and the trochanter.

195. *Resection of One-Half of the Pelvis* (Fig. 102).—Performed by Kocher and Roux with very satisfactory functional result, so that my patient, in whom the head of the femur was resected at the same time, can walk without a cane, though he limps badly. We give a characteristic illustration from a photograph taken three and a half years after the operation.

V. Upper Extremity.

196. *Excision of the Phalanges, Metacarpal Bones, Interphalangeal and Metacarpo-phalangeal Joints* (Figs. 106 and 107).—For the phalanges and joints only lateral incisions, for the metacarpals dorsal incisions, come in question. Incisions

on the fingers are placed nearer the dorsum, and this all the more in proportion as they are lengthened peripherally.

Regarding the fingers it is necessary to make bilateral incisions in order to prevent cicatricial retraction and lateral curvatures after the removal of bones. Extensor tendons and nerves on the dorsum of the hand (radial and ulnar nerves) are to be

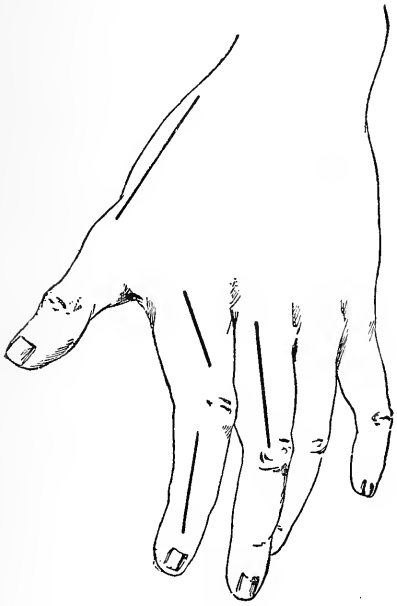

Fig. 106.

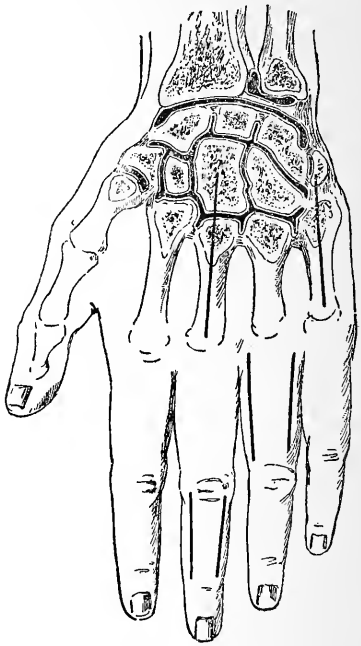

Fig. 107.

Figs. 106 and 107.—Resection of the Phalanges and Metacarpals. Resection of the Articulations of the Fingers. Frontal Section of the Wrist Joint after Henle.

spared; the incisions are to be made on the bones as felt subcutaneously and carried beyond the adjoining articulations.

Where there is no contra-indication, the resection should be subperiosteo-capsular, and the head of the bone is to be exposed first because it can be made more easily movable.

On the metacarpal bone of the thumb the tendon of the extensor brevis with the periosteum is to be pushed to one side, and the thenar muscles to the other side; at the upper end of

the bone the attachment of the tendon of the abductor longus must be separated. On the remaining metacarpals the external and internal interosseal muscles are to be detached with the periosteum. Only the metacarpo-carpal joint of the thumb is isolated; the others are connected with the wrist joint.

197. *Resection of the Hand* (Figs. 108 and 109).—For free opening of the wrist joint we have generally employed the method known as Langenbeck's, which is probably used most largely. Farabœuf states that the dorso-radial incision had been introduced in 1869 by Böckel. We have practised the same incision before Langenbeck's time, not only on the living patient, but have demonstrated it on the cadaver in our courses of instruction. At all events it was Langenbeck who secured recognition for the method, which has great advantages over earlier procedures.

Dorso-radial Incision.—The hand being in strong ulnar flexion, we make a straight incision through the skin from the middle of the second metacarpal to a point at an equal distance above the middle of the wrist joint, in the axis of the forearm. The incision lies between the tendons of the extensor digitorum communis, with the extensor indicis proprius on the one side and the extensor pollicis longus on the other side. The skin is divided slowly, preserving peripherally the branches of the superficial radial nerve which pass to the middle finger; then we sever the common dorsal ligament of the wrist with the fascia and penetrate at the forearm to the radius, at the wrist joint through its capsule and downward to the base of the third metacarpal. On the latter we detach the tendon of the radialis extensor brevis, and at the base of the second metacarpal that of the radialis extensor longus with the periosteum; we expose the dorsal surface of the second metacarpal with the interosseal muscles between the latter and the third metacarpal, and laterally close to the bone we begin to lift the tendons out of their grooves and to separate the capsule of the wrist joint.

The method of Böckel and Langenbeck, however, has this drawback, that in order to gain room the external radial muscles must be detached. No matter how carefully we make the method a subperiosteal one—as Trélat puts it (Farabœuf), peeling between tree trunk and bark—it entails grave injury to the chief dorsal flexors of the hand, and this may be the reason why a volar subluxation of the hand with greatly restricted dorsal flexion so often results. It is, therefore, justifiable, in

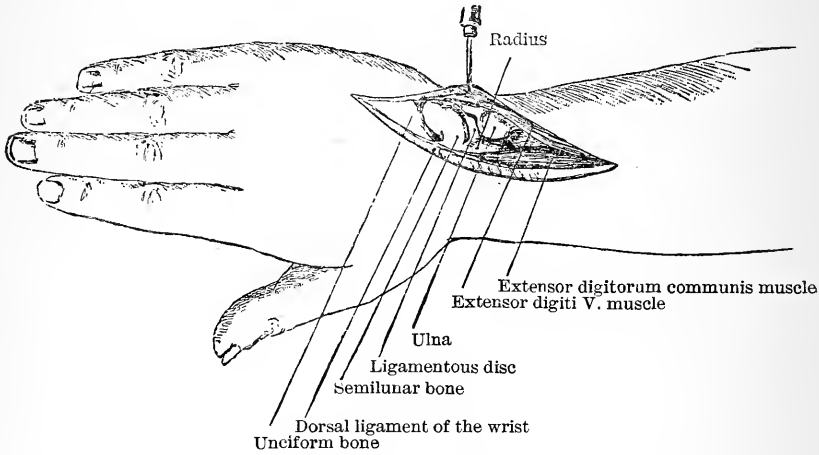

Fig. 108.—Arthrotomy and Resection of the Hand.

view of these common disturbances, to be more sparing of the radial muscles and place the incision on the ulnar side of the flexor tendons, though still on the dorsum, *i.e.*, to use the dorso-ulnar incision (Figs. 108 and 109), as it is called. This incision, proposed by Lister, lies far more to the ulnar side, between flexor and extensor carpi ulnaris. It should be 7 to 8 cm. in length; it begins, the hand being in slight radial flexion, at the middle of the interspace between the fourth and fifth metacarpal, passes toward the middle of the wrist joint and thence upward in the middle line of the dorsal surface of the forearm. At its lower end the incision preserves the dorsal branch of the ulnar nerve, which is easier than to save the radial in the dorso-radial incision, because the ulnar nerve turns toward the middle

line farther down. The incision divides the fascia and the common dorsal ligament of the wrist, opens the capsule at the base of the fourth metacarpal upon the unciform bone and ulna, but preserves the tendons of the extensor digiti minimi proprius and extensor communis between which it passes. The capsule is

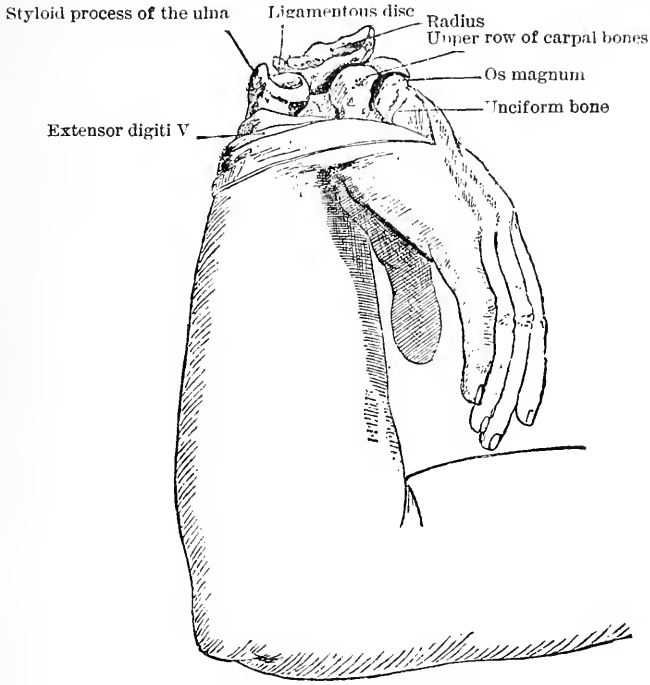

Fig. 109.—Arthrotomy and Resection of the Hand.

separated toward both sides and with it the tendon of the external ulnar muscle at the fifth metacarpal.

The detachment of the external ulnar tendon is less harmful than that of the two external radials. The ulnar muscle participates only to a minor degree in dorsal flexion as compared with the external radials which are attached to the radio-carpal or main joint. It is true, the external ulnar contributes materially to ulnar flexion; but this movement predominates only too much after resection as a result of gravity, for at a later stage

the hand appears inclined to the ulnar and volar side or even contractured in these directions. For this reason the separation of that tendon would act rather favorably than otherwise. Moreover, the extensor tendons are less liable to prolapse from the wound of the dorso-ulnar incision than from the dorso-radial. The extensor tendon of the little finger is most apt to be injured, but as this finger is provided with a double extensor and has far less important functions than the index finger, this is of no importance.

Above on the ulnar side the tendons of the extensor minimi digiti and the external ulnar are lifted from the groove in the ulna and the capsule is detached round about the ulna. When the joint is diseased between the ligamentous disc and the ulna and between the ulna and radius, the disc must be excised. The separation of the capsular attachments round about the ulna is easy. After the capsule is separated from the fifth metacarpal we naturally enter the joint between the pisiform and cuneiform; the tendon of the internal ulnar muscle is left intact at the former bone. The hamulus of the unciform, too, can more easily be freed than in the dorso-radial incision. The bundle of the common volar tendons is readily lifted *en masse* from its groove, and the attachment of the capsule to the fifth, fourth, and third metacarpals can be separated on the palm, while the attachment of the internal radial tendon is left intact at the second metacarpal. The tense capsular attachment to the volar margin of the radius is likewise separated.

On the dorsum the capsule is separated from the dorsal margin of the lower end of the radius to a point under the external radials and the extensors of the thumb, the tendons are lifted out of their grooves, and the attachment of the supinator longus is also separated. But the tendons of the external radials are left attached to the dorsal surface of the third and second metacarpals; the hand is forcibly luxated completely in the radio-volar direction so that the thumb touches the radial side of the

forearm. The enucleation of the carpal bones and the removal of the thinnest possible layer from the bones of the forearm and metacarpus now present no difficulty; only about the trapezium and trapezoid access is not so free for the removal of these and the three ulnar metacarpal bases. In cases where the disease affects mainly the radial side of the wrist and metacarpals or is confined exclusively to the radial side of the joints, the dorso-radial method is preferable to that described. Between the trapezium and trapezoid, or between the bases of the first and second metacarpals, special attention should be devoted to the radial artery, which here turns into the deep volar arch.

We consider as essential in our method that the tendons of the external radials be kept intact, and that it is possible, by complete luxation of the joint, to obtain a free view into all recesses and over all the bones.

In the after-treatment of resection and arthrotomy of the hand it is of importance that dorsal flexion at the wrist joint be secured by a splint such as we have had in use for many years, and which effects firm fixation of the wrist joint while permitting movements of the fingers. As for the finer function of the fingers their vigorous flexion alone comes in question, dorsal flexion at the wrist joint is the only correct position, for by the stretching of the flexor tendons it keeps the fingers at once in passive flexion and hence permits a greater degree of such flexion with very slight exertion.

198. *Resection of the Ulna.*—The ulna lies subcutaneous through the entire length of the forearm, in the space between the external and internal ulnar muscle. It can, therefore, be partially or totally excised without difficulty or incidental injury.

199. *Resection of the Radius.*—The radius is far less readily accessible than the ulna. On the posterior side of the radius the condyle can always be felt under the skin and therefore can be resected from a portion of the incision whose direction and

position are more fully described under our method for the resection of the elbow.

On the diaphysis the middle third is palpable on the posterior surface between the extensores radiales (longus and brevis) and the extensors of the fingers. Incision can here be made without having to fear the vessels, nor need nerve twigs be considered, since the adjoining muscles obtain their radial branches higher up. The upper third of the radius is covered by the supinator brevis through which the motor branch of the radial nerve passes dorsad. The lower third is covered externally by the tendons of the brachio-radialis and the radiales externi which run longitudinally, by the pronator quadratus, by the extensors crossing the dorso-radial side obliquely, and by the abductor of the thumb.

An incision along the entire length of the radius down to the bone is possible only in the line for the ligation of the radial artery, during which the superficial (sensory) branch of the radial nerve is displaced toward the radial side, and the vessels are pushed to the ulnar side. For the nerve lies toward the radius above; below, at the lower fourth of the forearm, it turns to the dorsal side.

The Free Opening of the Elbow Joint.

200. *Resection of the Elbow* (Figs. 110 and 111).—As in all arthrotomies and resections of the joints which require a free view into the joint for the correct removal of all diseased tissues, we adhere to the principle that a somewhat complicated cutaneous incision matters little if thereby we can preserve not only all the muscles with their attachments, but especially spare the nerve fibres which supply the muscles. This was our main reason for introducing the posterior curved incision for the arthrotomy of the shoulder to be described hereafter, and in the same sense we have modified the old method for the resection of the elbow.

At first we practised the simple method of von Langenbeck with posterior longitudinal incision; but we found that access was not as free as was desirable, particularly in cases of fungous inflammations localized in the region of the head of the radius

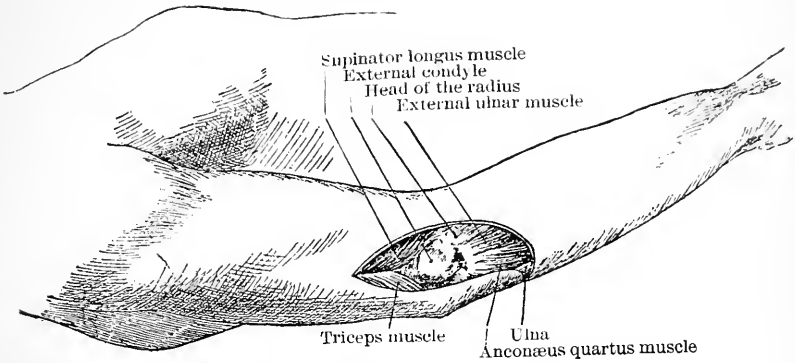

FIG. 110.—Resection of the Elbow.

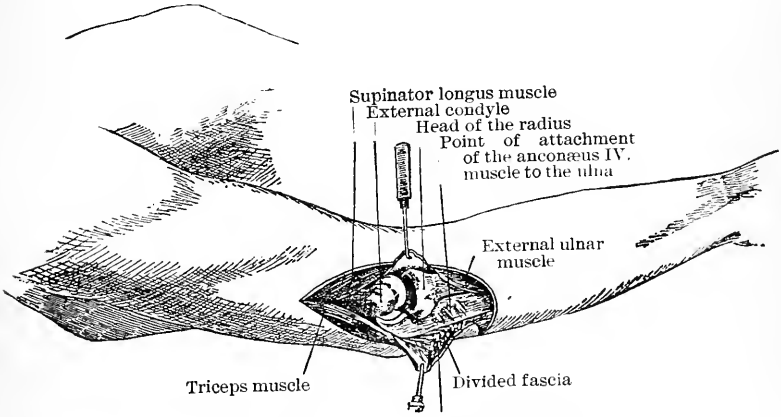

Attachment of the anconæus IV. muscle to the ulna

FIG. 111.—Resection of the Elbow.

or extending in this direction. Such access is furnished by Ollier's bayonet incision—an excellent method. But even the latter has the drawback of placing the anconæus quartus muscle out of function. It is true, the oblique middle portion of Ollier's incision passes through the interstice between the external head

of the triceps and the anconæus quartus; but since the branch of the radial nerve which supplies the latter muscle descends from above as the terminal twig of the above-mentioned branch supplying the head of the triceps, the muscle must atrophy after Ollier's operation. But in the case of the elbow it is our particular duty to do our best to secure actively movable joints, and for that reason the anconæus quartus should be preserved, as it is a true articular muscle for the tension and fixation of the capsule. This we effect in the following manner.

The elbow is bent to about 150° and an angular incision is made as in Fig. 110. This begins, like Ollier's incision, at the edge of the outer surface of the lower margin of the humerus, 3 to 5 cm. above the line of the joint; it runs essentially parallel to the axis of the humerus, *i.e.*, in a vertical direction to the head of the radius, thence corresponding to the lateral margin of the anconæus quartus to the edge of the ulna 4 to 6 cm. below the tip of the olecranon, and bends up about 1 or 2 cm. on the medial side of the ulna. Above, the incision reaches to the lateral edge of the humerus between the brachio-radialis, radiales externi, and extensor digitorum communis muscles, all of which remain in front, and the anconæus brevis which remains behind; then on the postero-external circumference of the head of the radius it severs the capsule and penetrates downward between the lateral margin of the anconæus quartus and the external ulnar muscle to the lateral surface of the ulna. The last offshoots of the anconæus quartus downward at the edge of the ulna are cut, for frequently they reach very far down the forearm.

Accordingly the incision completely separates the muscles supplied by the forearm branches of the radial nerve from those innervated by the deep branch of the radial nerve at the forearm, and thereby avoids any subsequent atrophy. After the bone is laid bare and the capsule opened, the next step depends upon the fact whether the removal of the olecranon is required

or not. If the latter is diseased, the chisel is applied in the line of the incision without unnecessary detachment of the muscles and tendons, and the olecranon is cut obliquely at its base (more deeply on the dorsal side). Then the flap consisting of triceps, anconæus quartus, and olecranon can be turned over toward the ulna, and the joint is open to inspection. According to the extent of its involvement, the olecranon can be enucleated in the most conservative manner.

If the olecranon is to be preserved, we proceed as follows. The external head of the triceps is separated from the humerus with the periosteum and the attachment of the capsule, the anconæus quartus from the outer surface of the ulna, the attachment of the triceps from the tip of the olecranon, and a portion of the internal ulnar muscle from the inner surface of the ulna. This triceps-anconæus flap with the capsule is turned inward over the olecranon like a cap, the arm being extended. As shown in Fig. 111, the joint can now be freely inspected from behind externally and be made to gape as soon as the external lateral ligament and the capsule are detached from the external condyle of the humerus and the neck of the radius. In this way the entire extensor apparatus is preserved *in toto*, as regards both muscles and nerves. According to the indications for the arthrotomy, we now detach as gently as possible the internal lateral ligament from the inner margin of the ulna and the medial surface of the trochlea, also the muscles, in connection with the periosteum, from behind forward so far as absolutely necessary, from the internal and external condyle, when the resection of the bone can be performed if required.

In cases of fungous disease of the capsule, we open the joint, on principle, as late as possible, by carrying the incisions only as far as the joint capsule, and dissect its outer surface free. In this way the whole morbid mass of tissue can be more accurately extirpated *en masse*. In resection of the olecranon we

have for many years practised the curved sawing in order to secure an olecranon to the new joint. This aids largely in preventing forward subluxations of the forearm.

We have above laid stress on the fact that in comparison with the simple posterior longitudinal incisions, of which Langenbeck's is the most common, the curved incisions, of which Ollier's method is the best representative, possess great advantages in giving more room and exposing the joint more thoroughly, especially about the head of the radius. Hardly anybody will be inclined to employ transverse incisions, whether straight or curved, combined or not with one or two longitudinal incisions. The principal direction of the incision will always have to be longitudinal if the muscles and their nerves are to be preserved. The only method which we have to mention according to Farabœuf's description, since it resembles our own, is that of Auguste Nélaton, who combines an external longitudinal incision upon the head of the humerus with one running at a right angle backward from the head of the radius to the ulna. But even Nélaton employs it mainly for the sufficient exposure of the head of the radius and, like Ollier, pays no attention to the preservation of the anconæus quartus. Hueter likewise and, according to Farabœuf, Marangos have recommended cutaneous incisions related to ours, but they differ in the principal object and intention of the incision.

201. *Resection of the Diaphysis of the Humerus.*—The excision of the humerus offers less simple conditions than that of the femur. The mode of removal of the upper and lower ends may be gathered from the description of the corresponding joint resection. Upon the diaphysis the relation of the radial nerve must be principally borne in mind. The nerve curves from within around the posterior surface of the humerus toward the outer side.

The external bicipital sulcus is the only line in which we can cut down upon the diaphysis over its entire length, from the

lower end of the surgical neck (in the region of which the circumflex artery and nerve must be spared) to the condyles below. We divide the fascia of the deltoid so that the anterior margin of the muscle can be drawn backward with the arm in the abducted position; then we open the fascia of the biceps and penetrate close to the margin of the muscle and under it along the coraco-brachialis and the outer margin of the brachialis internus down to the bone. The radial nerve with the offshoots of the deep brachial artery (collateralis radialis) remains on the outer side; in the lower third the musculo-cutaneous nerve, which descends between the biceps and brachialis internus to the lateral anterior side, is drawn medially.

202. *Resection of the Articulation of the Humerus.*

a. From in front, in disease of the head of the humerus (Figs. 112 and 113). The head of the humerus projects considerably beyond the socket in front, for in a horizontal direction the diameter of the socket is but half that of the head covered with cartilage. The head, therefore, is more readily accessible from this side in the same proportion as the socket is exposed with greater difficulty from in front. The simplest method is the anterior longitudinal incision practised by Baudens, Malgaigne, Robert, and Dubreuil; but perfected particularly by Langenbeck and his pupils. The improvement of the operation by Hueter, Ollier, and Chauvel, who substituted for the vertical incision an oblique one from the acromion downward through the deltoid so as to spare the latter, appears to be the most rational procedure, since this muscle is of the greatest importance for subsequent movements. The incision begins above the coracoid process on the clavicle and passes down along the anterior margin of the deltoid. The margin of this muscle, to which the clavicular portion of the pectoralis major muscle is closely adjoining, is mapped out by the cephalic vein. This is cut above or dissected out toward the pectoralis. If necessary the deltoid is detached for some distance close to the clavicle, by a transverse

incision. The acromial branches of the thoracico-acromialis and transverse scapular arteries are to be ligated.

The anterior margin of the deltoid is drawn outward. This brings into view the muscles springing from the coracoid process: pectoralis minor, short head of the biceps, and coraco-brachialis. At the lateral margin of the latter we cut down on

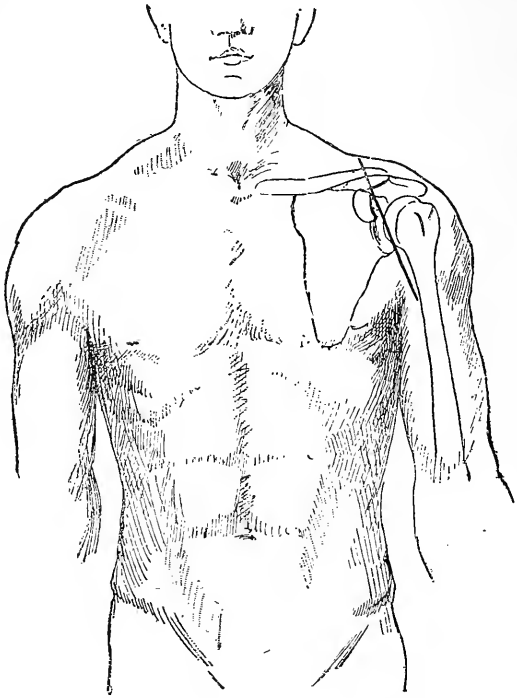

FIG. 112.—Anterior Resection of the Humerus.

the bone and, the arm being slightly rotated inward, open the sheath of the biceps tendon above the sulcus of the biceps which can be distinctly felt. The opening is made downward and upward through the upper wall of the capsule until the tendon is exposed at its attachment to the upper margin of the socket and can be readily drawn inward. This exposure of the biceps tendon has for its object not only its preservation, but it is intended especially to render the head of the humerus accessible in a line

along which the muscular attachments meet from in front and behind. Then follows the separation, by vertical incisions close to the bone and parallel to the bicipital sulcus, of the tendons attached to the capsule, namely, that of the subscapularis from the tuberculum minus, those of the supraspinatus and infra-

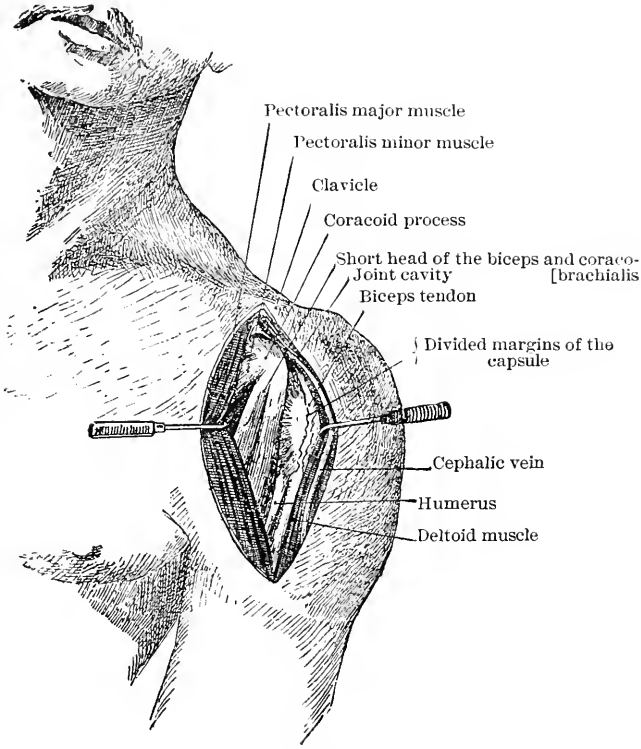

FIG. 113.—Anterior Resection of the Humerus.

spinatus and teres minor from the tuberculum majus. At the same time the humerus is rotated so that the joint surface is exposed more and more, first anteriorly, then posteriorly.

Any transverse incision through the capsule between the head and the socket is to be absolutely avoided. If the humerus requires exposure farther downward, regard must be had for the anterior and posterior circumflex arteries at the surgical neck and for the axillary nerve; the former may need ligation.

b. From behind (Figs. 114, 115, and 116) when the socket is largely affected or in diffuse disease of the joint.

As shown in Fig. 114, the cutaneous incision passes from the acromio-clavicular joint over the highest part of the shoulder along the spine of the scapula to near its middle, thence downward in a curve toward the posterior axillary fold, ending two fingers' breadth above the latter. The upper part of the incision penetrates into the acromio-clavicular articulation (the covering ligaments of which are severed) and in its further course runs along the upper margin of the spine. The descending portion of the incision divides the thick fascia along the posterior margin of the deltoid muscle, which is thus exposed in its lower portion, when the finger draws the muscle vigorously forward. The fibres of the deltoid which are attached farther backward along the spine must be cut, and thus a small posterior triangle of the muscle is placed out of function.

The attachment of the trapezius is separated above at the spine, the supraspinatus muscle is detached with the elevator, as is the infraspinatus below, until the finger can seize the lateral margin of the spine at the point where it rises from the scapula.

The supraspinatus and infraspinatus muscles being drawn aside, the spine is cut through at this point with a blow of the chisel. During this step care should be taken lest injury be done to the suprascapular nerve, which descends under the muscles named from the supraspinatous into the infraspinatous fossa; the nerve, however, is protected by the inferior transverse scapular ligament. Before cutting the bone it is desirable to make two gimlet-holes for the subsequent suture of the divided surfaces. Or else, the periosteum can be divided backward and forward, a small piece of bone excised, and the periosteum sutured over it. After the bone is cut, the acromial portion can be completely turned forward or luxated in the acromio-clavicular articulation, by the exercise of some force and the insertion of a sharp hook.

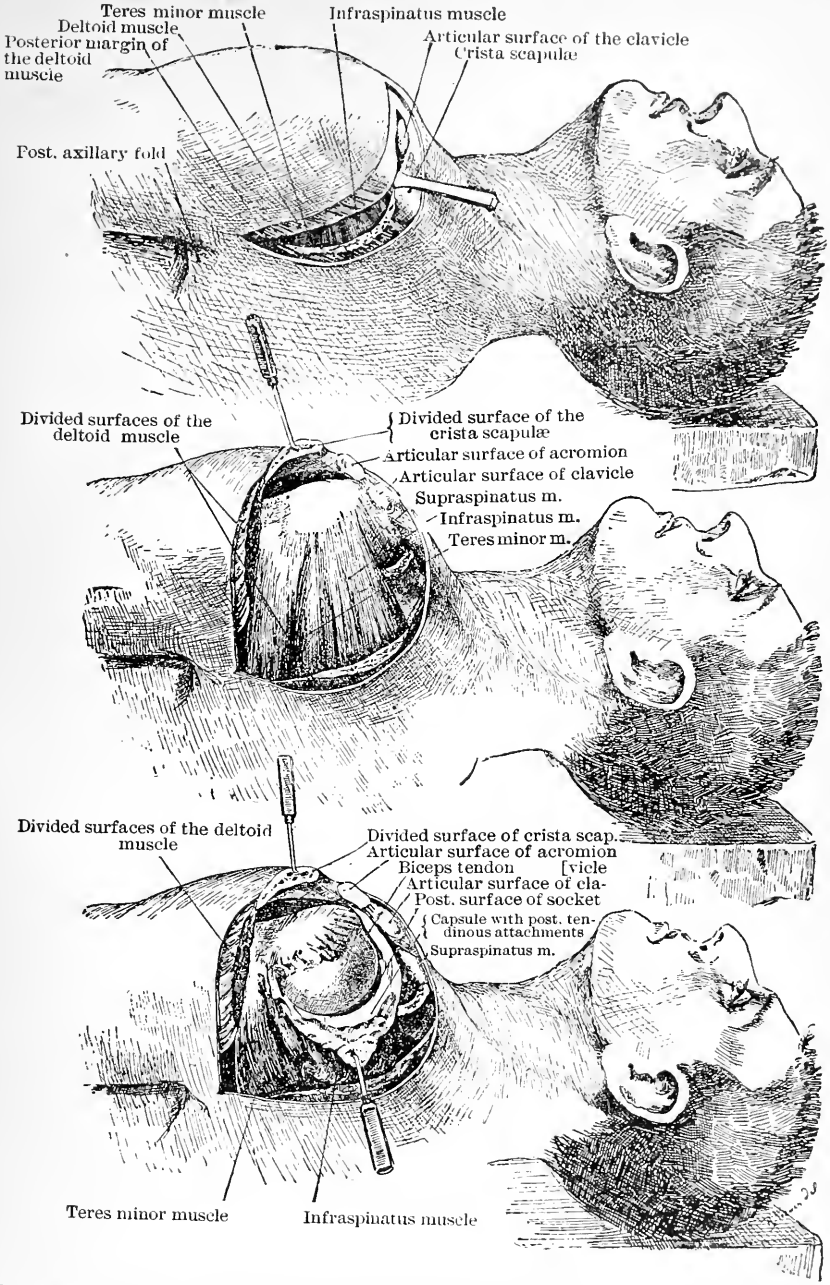

FIGS. 114, 115, AND 116.—Posterior Resection of the Articulation of the Humerus. (The divided surfaces of the deltoid muscle appear much too long in the illustrations, as merely a small posterior triangle is cut off.)

During this step the deltoid becomes spontaneously detached from the muscles of the scapula, with whose smooth under surface it is connected only by some loose connective tissue (Fig. 115).

After the acromio-deltoid flap is turned over, the upper, outer, and posterior surfaces of the head of the humerus are freely accessible, covered by the tendons of the outward rotators, supraspinatus, infraspinatus, and teres minor. The posterior surface of these muscles is likewise exposed. Much now depends on the fact that the incision on the head of the humerus be placed correctly so as to avoid unnecessary injury. At the point where the muscles named with their tendons are attached to the tuberculum majus and the spina tuberculi majoris, *i.e.*, at the anterior margin of these attachments and the posterior margin of the palpable bicipital fossa, a longitudinal incision is made upon the bone, passing upward along the upper margin of the supraspinatus; thus the capsule is divided on the upper surface of the joint and the biceps tendon is exposed as far as its attachment to the upper margin of the socket. Along the posterior margin of the biceps the attachments of the external rotators to the tuberculum majus are separated and drawn backward. In this way the biceps tendon is freed below from its bony fossa so that it can be drawn forward and the sheath of the biceps laid bare for inspection. In order to facilitate this step the elbow is brought forward and the arm rotated outward. Now the attachment of the subscapularis to the tuberculum and the spina tuberculi minoris becomes visible and is separated from the bone forward and inward. It is quite easy to spare the circumflex nerve and vessels which emerge from below the teres minor muscle; in fact, their injury does not come into question when the operation is correctly performed (Fig. 116).

As soon as the head is entirely freed—still more so, of course, when it is removed by resection—we obtain an excellent view into the socket, one that is far better than is possible by the anterior mode of operation. It need hardly be pointed out that

this is at present of special importance, in comparison with the former practice, when it was almost thought to be a matter of course that in resection of the humerus decapitation of the head alone was performed. Unless the affected tissues are removed from every part of the joint in tubercular disease, operative treatment has been deprived of most of its value.

Resection of the shoulder joint from the above-described posterior curved incision not only allows absolutely free inspection of the joint, but it fulfils the indication of keeping the deltoid with the other shoulder muscles in function, for it injures neither the muscle nor the afferent nerve. But it possesses a material advantage over resection from in front, inasmuch as it makes it possible, in the case of absent or limited disease of the head, to restrict ourselves to the detachment of the muscles passing from the posterior surface of the scapula to the capsule, while leaving the latter intact at the anterior circumference of the head, together with the covering subscapular muscle and the coraco-humeral ligament. This is the best way of guarding against the frequent subluxation of the head of the humerus toward the coracoid process. The method, therefore, deserves special consideration in arthrectomies.

203. *Resection of the Clavicle, of the Sterno-clavicular and the Acromio-clavicular Articulations.*—As the clavicle lies under the skin for its entire length, its resection is a simple matter whenever it can be made subperiosteal. After dividing the skin, platysma (with the supra-clavicular nerves), and the fascia, the periosteum is readily pushed back. Sawing through the clavicle in the middle facilitates the separation of the two halves. At the upper margin the attachments of the clavicular portion of the sterno-mastoid muscle and the trapezius, at the lower margin the clavicular portion of the pectoralis major and the deltoid, are to be separated; at the posterior surface the subclavian muscle, and medially the costo-clavicular ligament.

For the resection of the acromio-clavicular articulation merely the stout mass of ligaments on the surface of the joint is to be divided to make the clavicle movable.

The sterno-clavicular articulation *per se* likewise presents no difficulty from an anterior incision; for the meniscus facilitates the separation of the ends of the joint. But where the excision cannot be made subcapsulo-periosteal, we must bear in mind, during the separation of the interclavicular ligament, the transverse vein in the sternal notch; during the separation of the sterno-mastoid muscle, the continuation of the same vein behind this muscle to the external jugular vein; during further division of the subclavian muscle and the costo-clavicular ligament, the pleura and the subclavian vein.

204. *Resection of the Scapula* (Fig. 117).—Total resection was first performed by Langenbeck (Gies) in 1855. In disease and especially in tumors of the scapula, which are not rare, it is important that this bone be excised thoroughly but without unnecessary incidental injuries. The periosteum should be preserved wherever feasible, together with the covering muscles, in view of possible regeneration. On the other hand, where preservation of the periosteum is out of the question, as in tumors, it appears to be particularly desirable to remove thoroughly all the muscles which are placed out of function, in order to prevent relapses. In total excision of the scapula, these include the muscles moving the scapula alone or acting from the latter upon the arm.

Curved incision from the point at which the acromion must be severed, over the spine of the scapula to its posterior margin, and downward to the angle of the scapula. It is a great advantage for the function of the arm if a good part of the acromial portion can be preserved, because to it are attached important muscles—the trapezius from above and the deltoid from below. If the acromion is to be removed completely, the incision at its beginning at once passes into the acromio-clavicular articulation

and divides it fully. If a portion is preserved, the acromion is severed with a chisel at the respective point.

The triangular flap formed by the above-described incision is turned forward over the latero-posterior fibres of the deltoid and backward over the ascending portion of the trapezius to the margin of the latissimus dorsi muscle. The finger is in-

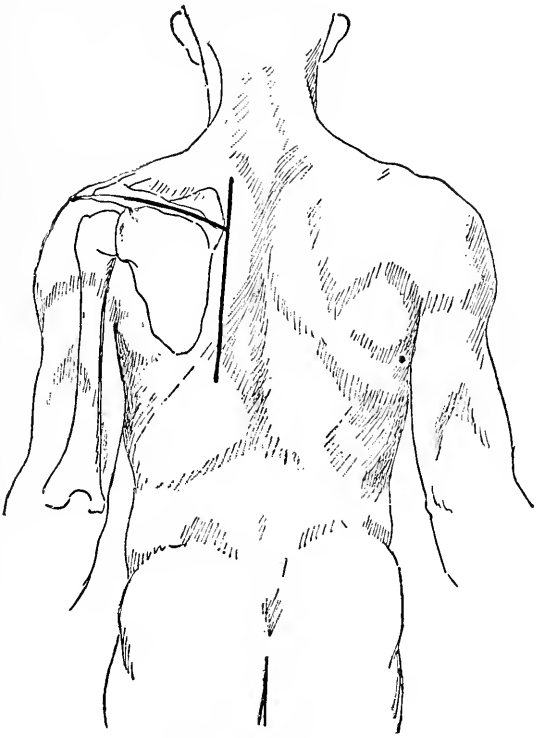

FIG. 117.—Resection of the Scapula.

serted under the exposed posterior margin of the deltoid and the muscle separated as close as the disease permits, along the crista and the acromion as far as the acromio-clavicular articulation or to the point where the acromion is cut with the chisel.

In this way, similarly to our resection operation for the shoulder joint, the posterior surface of the capsule with the covering tendons of the outward rotators is laid bare. If the articular portion of the scapula can be preserved, one muscle

after another is cut upon the insinuated finger or elevator, and the articular portion of the scapula is sawed off. But if the articular portion is to be removed likewise, the tendons are separated from the head of the humerus as in resection of that bone; from the tuberculum majus, the supraspinatus and infraspinatus and teres minor; from the tuberculum minus, the subscapular; and below from the spina tuberculi minus, the common attachment of the latissimus dorsi and teres major.

At the lower margin of the teres minor the axillary nerve and posterior circumflex artery are to be preserved or the latter ligated; farther backward the circumflexa scapulæ artery must be ligated.

Next the trapezius is divided, the finger being insinuated under its fibres from the cut surface of the acromion, and the muscle is separated along the crista scapulæ, also behind along the inferior edge of the crista. At the anterior end the acromial branches of the thoracico-acromialis artery must be ligated.

The scapula, now more freely movable, is drawn down; the muscles attached at the upper margin are separated antero-posteriorly; the omo-hyoid combined with ligation of the terminal branch of the transversa scapulæ artery, the levator scapulæ at the posterior upper angle with ligation of the branches of the dorsalis scapulæ artery (transversa colli).

Then the broad, rounded attachment of the serratus anticus major muscle at the posterior margin of the scapula is separated when the scapula is turned over, and finally the attachments of the thin rhomboids are cut at the same point, with eventual ligation of the dorsalis scapulæ artery, which passes along the scapular margin on the serratus posticus superior muscle.

PART IV.

AMPUTATIONS AND EXARTICULATIONS.

Introduction.

THE complete removal of a limb or a portion of it is called amputation. If the removal is made at the joint it is generally called exarticulation. Quite a number of indications for the choice of the method of amputation have become nugatory since the introduction of the antiseptic wound treatment and the improvement in the technique in connection with the latter. In former times two considerations pre-eminently determined the surgeon to follow a definite method in the removal of a portion of a limb:

1. The desire to favor rapid and undisturbed recovery.

2. The formation of the most useful possible and painless stump.

In order to secure rapid healing, the wound was sought to be made small, smooth, and so placed that the margins were well nourished and coapted themselves spontaneously; finally the best possible escape of the secretions from the wound surface was aimed at.

Nowadays, thanks to asepsis, we can make the largest wound heal by first intention, can even tolerate considerable tension of the wound margins, and can sufficiently provide for the escape of the wound secretions, which at any rate form an element for a few days only, by separate small openings.

Moreover, the usefulness of the stump formerly depended far more upon the method than it does to-day, since it was by the method that the surgeon had to secure the mobility of the

skin on the stump, the correct placing of the tendons and muscles to the ends of the bones, and the removal of the nerve stumps from the region of the cicatrix.

At present even these considerations are largely done away with when the course of the wound is aseptic. Amputation is permissible anywhere, provided sufficient tegumentary covering for the stump can be obtained and the cicatrix (superficial and deep) can be protected from injurious pressure from without.

Development of the Methods of Amputation.

In order to show the connection of the various methods of amputation, we give in Figs. 118 to 122 a synopsis of the development of the complicated incisions from the simple circular methods.

The simplest and oldest methods have recently again become the most frequent. These are the circular incisions. By circular incisions we understand, in opposition to other authors, not only transverse incisions, but also those running obliquely to the axis of the limb, provided the line of the incision continues in one direction, or the incision lies in a single plane. In the following diagrams we give the fundamental type of the circular method from which all other methods can be derived, first by the addition of longitudinal incisions, and then by the rounding of the resulting angles. The addition of a single longitudinal incision with rounding of the angles results in the so-called oval incision (an oval with a pointed side is strictly not an oval). The addition of two longitudinal incisions with rounding of the angles results in true flap incisions. The incision "*en raquette*" and the quadrangular flaps are transitions from the circular to the latter methods. Wherever possible the circular method is to be preferred. For the employment of the oval and flap methods we shall always give the special indications. In the introduction, therefore, we can confine ourselves to the descrip-

DEVELOPMENT OF THE METHODS OF AMPUTATION.

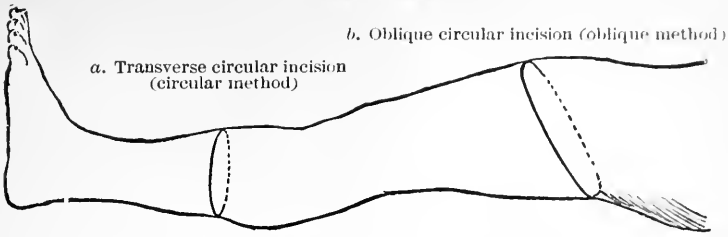

FIG. 118.—I. Fundamental Type: Circular Method.

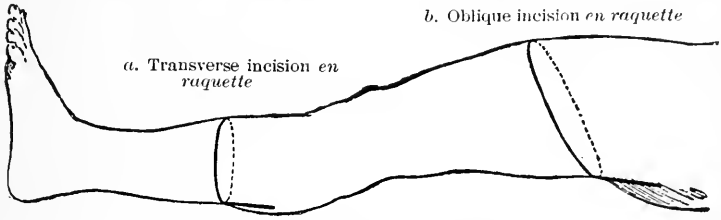

FIG. 119.—II. Transition to the Oval Method (Incision *en raquette*=Pedunculated Circular Method).

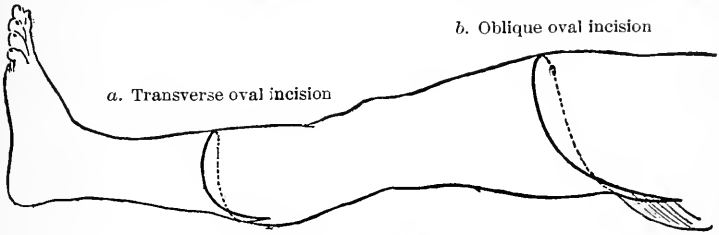

FIG. 120.—III. Oval Method.

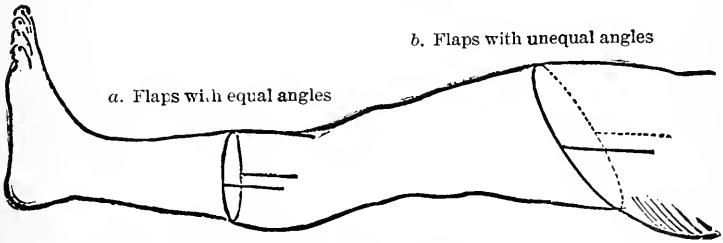

FIG. 121.—IV. Transition to the Flap Method (Angular Flap Method=Doubly Pedunculated Circular Method).

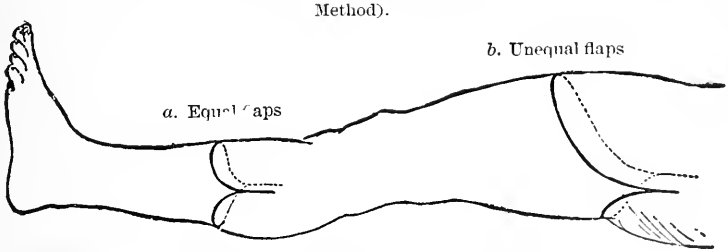

FIG. 122.—V. Flap Method (Rounded Flaps).

tion of the circular methods and only briefly point out the indications.

The transverse circular method secures to the skin the best vascular supply and nutrition. It is contra-indicated in favor of the oblique circular method: first, when more healthy skin is present on one side of the limb than the other, otherwise the amputation would have to be carried unnecessarily high; secondly, when the portion of the limb to be operated on is much thicker above than at the point of incision, as this renders the retraction of the skin difficult; thirdly, when the cicatrix cannot be placed at the end of the stump because it is exposed to pressure from below. Figs. 129 and 130 sufficiently illustrate the varying position of the suture: in the transverse circular method, below on the stump; in the oblique circular method, above the stump laterally. It is evident without much argument that for the reasons above given the transverse circular method finds a far more general application because it can be adapted to most cases, is easily executed, and furnishes a movable tegumentary covering for the end of the stump which is free from cicatrices.

The incision *en raquette* and the oval method give more room with equal preservation of integument, or equal room with greater preservation of integument (including the soft parts) and therefore are to be preferred in some difficult exarticulations (at the thumb, hip, and shoulder).

The flap method is preferable where the skin or the other soft parts on one side of the limb call for special consideration. This is the case, for instance, at the heel and the muscles at the shoulder and hip. The drawback of the flap method, which applies in a minor degree even to its fundamental type, the oblique circular method, is the defective nutrition of the skin.

The performance of the transverse circular method is sufficiently illustrated in Figs. 123, 124, and 125.

The oblique circular method (see Figs. 126, 127, and 128) differs from the transverse in one essential point, namely, that



FIG. 123.—Transverse Circular Method; showing the retraction of the skin and the application of the knife.

FIG. 124.—Transverse Circular Method; showing how the deep muscles together with the periosteum are pushed back with the raspatory.

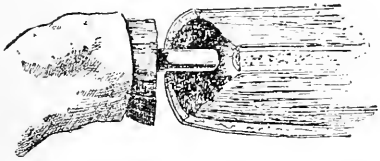

FIG. 125.—Transverse Circular Method after Sawing the Bone; showing the hollow cone (in sagittal section) from the skin to the bone.

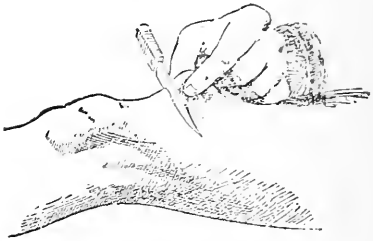

FIG. 126.—Oblique Method; pinching up of the skin for marking the lower end.

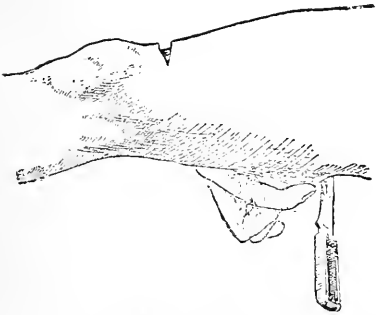

FIG. 127.—Oblique Method; pinching up of the skin for marking the upper end.

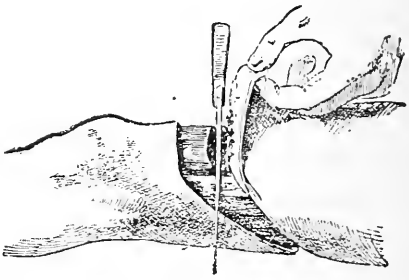

FIG. 128.—Oblique Method: showing the application of the knife for the gradual deep division of the soft parts.

FIG. 129.—Position of the Suture in the Transverse Circular Method.



FIG. 130.—Position of the Suture in the Oblique Method.

the skin is lifted from the underlying tissue and must be dissected back with the knife, while in the transverse circular method it is merely drawn back.

Another difference lies in this, that the relation of the cutaneous incision to the point of division of the bone must be determined in varying ways. The plane in which the limb is ablated forms a wound surface for the covering of which integument must be spared. In the transverse circular method the knife must be applied one-half the greater diameter of the limb (measured at the point of division of the bone) below the line along which the bone is sawed; in the oblique circular method, the whole diameter of the limb. In the latter case the upper end of the oblique incision is at the level where the bone is divided (Fig. 127). These measurements should be taken very liberally, since one to two centimetres must be available for the broad coaptation of the wound margins. The elastic retraction of the wound margins need not be considered for wounds to be healed by first intention, as it is readily overcome by the suture and becomes useful for a good adaptation of the integument to the wound surface. In the open wound treatment the measurements should be doubled.

The cutaneous incision severs the skin, subcutaneous adipose tissue, and superficial fascia. Both hands of an assistant retract the skin vigorously during the transverse circular incision, the knife cutting the tightening fibres always close to the edge of the skin.

In the oblique circular method the upper and lower ends are best marked by small incisions made by pinching up a fold of skin as in Figs. 126 and 127. The two small angles of this "rhomboid incision" also facilitate the subsequent suture. The left hand then grasps the longer skin margin and draws it up with great force so as to detach it from its base to the level of the upper end of the incision (Fig. 128). Wherever possible the fascia is included. The edge of the knife must never be

directed toward the flap, but always against the underlying tissue.

At the margin of the retracted skin the muscles are divided in a plane transverse to the axis of the limb (Fig. 123); where the muscle is thick, the superficial layers are first severed and allowed to retract upward, and the deeper layers are divided in a higher plane because the superficial muscles usually retract more strongly.

The same plan is followed in the puncture method. This is admissible in the formation of two short equal flaps; the divided skin being drawn back, the muscles detached from the bone, the knife inserted in one of the angles between the flaps, carried along the bone, and pushed through in the other angle between the flaps, so as to divide the muscles obliquely along the margin of the skin by one smooth cut. The same is done on the other side, the muscles being lifted off. This operation requires a long, sharp, two-edged knife.

Then follows the incision through the periosteum in the plane in which the muscles have retracted (Fig. 124). This is pushed without cutting along the bone as far as necessary for covering the sawed surface of the bone completely with periosteum, and the bone is severed at the margin of the detached periosteum. Where the periosteum adheres closely, as on the rough lines of epiphyses and tendinous attachments, it is separated with the knife.

Where no muscles are to be divided, as on certain joints, all the soft parts at the margin of the retracted skin are severed down through the periosteum, and the bone is enucleated subperiosteally, in the case of joints subcapsularly, to the point of division (Ollier's subcapsulo-periosteal method).

In all cases in which the end of the bone is to act as a direct support, as especially on the epiphyses, it must be rounded off, either by curved sawing or by osteoplastic covering with a rounded bony process, as in Pirogoff's and Gritti's operation.

After the removal of the limb the vessels are ligated, best with fine silk; the stumps of nerves and tendons are searched for, drawn out, and cut off at the level of the wound surface. Where the suture fails to bring the raw surfaces in exact coaptation throughout, a glass drainage-tube with large lateral openings is inserted through a special small incision (for its direction see the figure showing the cleavage lines of the skin).

Then follow a few deep button sutures and an uninterrupted exact cutaneous suture.

X. Lower Extremity.

Amputations at the Foot.

For the foot the chief rule is to make the incisions for amputation so that no cicatrix extends to the sole. Therefore oblique incisions and their modifications are here the normal methods. The longer flap must always lie on the plantar side. The second rule is to look upon the foot always as a whole, excepting isolated amputations of the toes, *i.e.*, to ablate it in a transverse line (Major).

205. *Removal of the Toes, with or without Metatarsal Bones* (Fig. 131).—Amputations and exarticulations of the toes are fully analogous to those of the fingers. For the phalanges and interphalangeal joints the oblique method is indicated; for the metatarsals and the metatarso-phalangeal joints, the oval method. The dorsal portion of the incisions extends to the bone and enucleates it subperiosteally.

On the first and last toe the dorsal portion of the incision is made, not on the middle of the phalanges and the metatarsus, but more toward the median line of the foot so as to bring the cicatrices out of reach of lateral pressure.

206. *Exarticulation of all the Toes* (phalango-metatarsal exarticulation; Fig. 132).—All the toes are circumscribed by an incision at the base where they separate from the common in-

tegument of the foot, so that the incisions coincide with the interdigital folds. On the sole the incision runs exactly in the groove of the ball of the toes. Laterally on the great and little toes two dorso-lateral longitudinal incisions are added.

The toes being flexed strongly toward the sole, the dorsal tendons are severed as high as possible at the margin of the

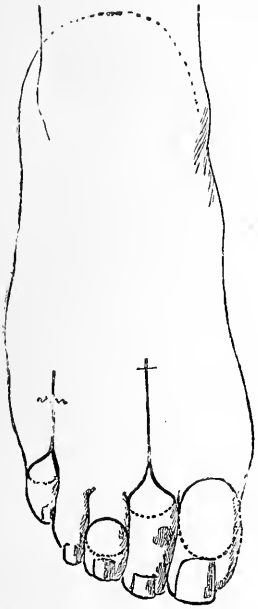

FIG. 131.—Exarticulation of the Great Toe, Exarticulation of the Second Toe with the Metatarsal, Amputation of the Third Toe, Amputation of the Fifth Metatarsal.

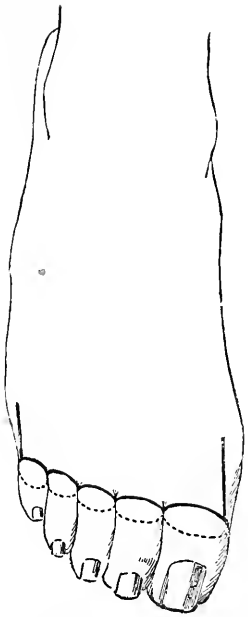

FIG. 132.—Exarticulation of the Toes.

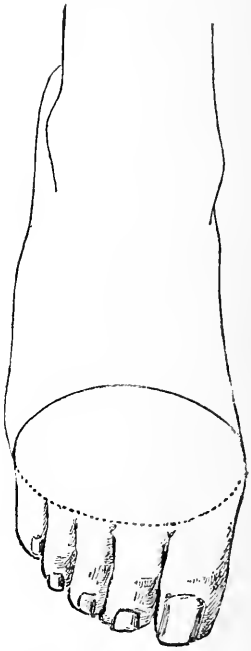

FIG. 133.—Metatarsal Amputation.

wound, a small knife cuts the lateral ligaments and the dorsal and plantar joint capsule, and lastly the plantar tendons as high as possible.

207. *Metatarsal Amputation* (Fig. 133).—This operation has the advantage over the metatarso-tarsal exarticulation that the attachments of the chief muscles of the foot are all preserved, not only tibialis posticus and peroneus, but also tibialis anticus, peroneus brevis and tertius. The foot, there-

fore, remains movable in all directions. It is likewise quite useful for support, as the important support of the fifth metatarsal at its posterior end is preserved, the only one lost being that of the head of the first metatarsal.

Oblique incision with the formation of a plantar flap, which is at once separated in such a way as to pass with long strokes of the knife through the muscles obliquely to the point where

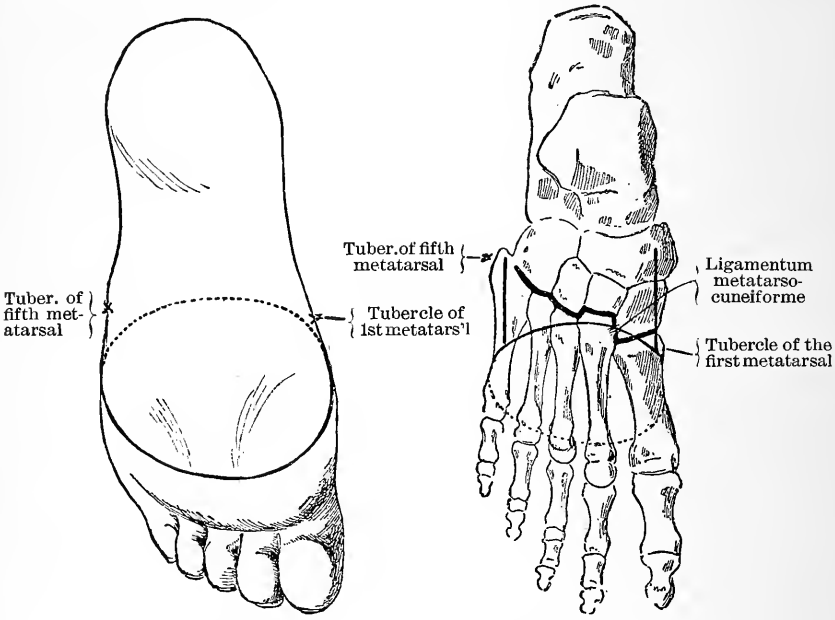

FIG. 134 (Plantar surface). FIG. 135 (Dorsal surface).

FIGS. 134 AND 135.—Tarso-metatarsal Exarticulation (Lisfranc).

the bones are severed, in order to spare the branches of the internal and external plantar artery. All the plantar bones, one after the other, are circumscribed with a small scalpel and sawed off.

208. *Metatarso-tarsal Exarticulation* (Lisfranc; Figs. 134 and 135).—Passing between the metatarsus in front, the cuneiform bones and the cuboid behind. The plantar flap extends to the middle of the balls of the toes. The joint is characterized laterally by the tuberosity of the fifth metatarsal, behind which lies the line of the joint (Fig. 135). On the medial side a small

eminence, the base of the first metatarsal, is distinctly palpable. Oblique incision with two dorso-lateral cuts so as to lay bare the line of the joint.

The line of the joint is convex downward and outward, has a depression above, due to the recession of the second cuneiform bone which stands back from the oblique convex line 2 to 3 cm. from the third cuneiform, and 1 cm. from the first. The two joints are opened first (the first, third, fourth, and fifth), the second last. The strongest ligament is between the first cuneiform and the base of the second metatarsal (compare Fig. 135), and until that is severed the joint cannot be made to gape.

As in all operations on the foot, the vessels are preserved in the plantar flap.

Where the tegumentary covering is insufficient, the removal of the first cuneiform does not lessen the function of the foot any more than Lisfranc's exarticulation alone.

209. *Anterior Intertarsal Exarticulation* (Jäger; Fig. 137). —Between the cuneiform bones in front and the scaphoid behind, the cuboid being sawn through. Operation like Lisfranc's, somewhat less integument being preserved. The method has the advantage over Chopart's of preserving the strong ligament from the calcaneus to the cuboid and scaphoid bones.

210. *Posterior Intertarsal Exarticulation* (Chopart; Fig. 136).—Between calcaneus and astragalus behind, the cuboid and scaphoid in front. The operation has often resulted in a bad stump, owing to equinus position of the foot and chafing at the anterior lower circumference of the calcaneus. The best preventive measures for this are, to attach the dorsal flexor tendons firmly to the stump, prophylactic tenotomy of the Achilles tendon, and care for healing by first intention.

The line of the joint is characterized on the medial side by the marked projection of the tuberosity of the scaphoid bone behind which it lies, and laterally by an eminence on the body of the calcaneus in front of which it lies. The oblique incision

strikes the line of the joint above, and below passes to the posterior end of the balls of the toes. Two small dorso-lateral incisions facilitate the exarticulation.

We penetrate into the joint between the head of the astragalus and the scaphoid which is convex below; on the outer side and more deeply the knife should again be directed toward the toes,

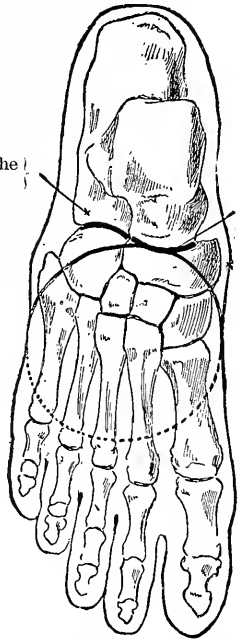

FIG. 136 (Dorsal surface).

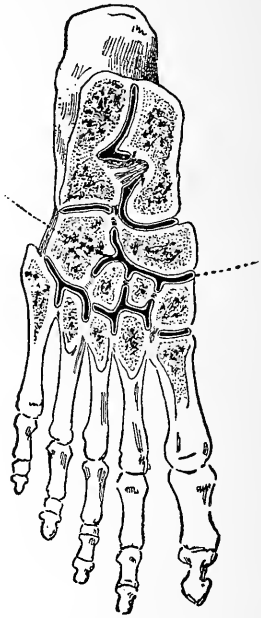

FIG. 137.

FIG. 136.—Medio-tarsal Exarticulation (Chopart).
FIG. 137.—Medio-tarsal Amputation (Jäger). Horizontal section of the Foot after Heitzmann.

for the lateral portion of the joint between calcaneus and cuboid is concave forward. If the edge is directed backward we reach the joint between astragalus and calcaneus.

The main connection between the bones is the Y-shaped ligament from the body of the calcaneus to the scaphoid and cuboid bones.

211. The term "tarsal amputation" can be applied to the operation in which, after exarticulation, the joint surfaces of the astragalus and calcaneus are sawed off because the tegumentary

covering does not suffice for a Chopart operation. As the capsule of the ankle joint is not opened (the operation extends to within 1 cm. of the margin of the cartilage of the astragalus joint) the resulting foot is still movable.

212 *a. Subastragaloid Exarticulation* (Malgaigne, Textor; Figs. 139 and 143).—Oval incision, beginning horizontally under

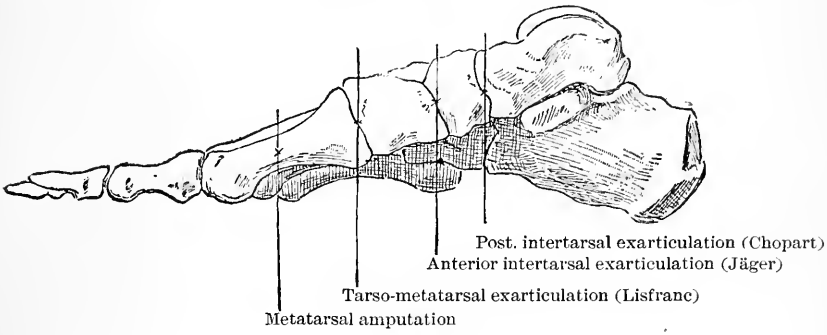

Fig. 138.

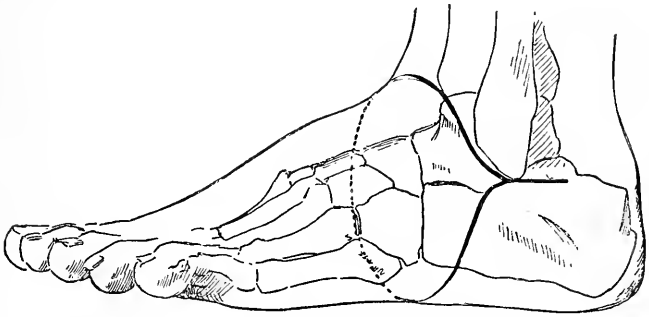

Fig. 139.—Subastragaloid Exarticulation (Malgaigne, Textor).

the tip of the external malleolus, extending toward the dorsum to Chopart's line (which is distinctly marked, as above, by the tuberosity of the scaphoid), along which it descends vertically to the sole on the medial side, back to its point of beginning on the outer side.

Chopart's joint is opened from above between the head of the astragalus and the scaphoid. Then, without penetrating deeper into this joint, the narrow knife is turned immediately upward and backward under the head of the astragalus so as to

sever the strong ligamentum interosseum astragalo-calcaneum in the sinus tarsi, and the calcaneus is enucleated, first on the upper, outer, and lower surface, then inward, and lastly behind.

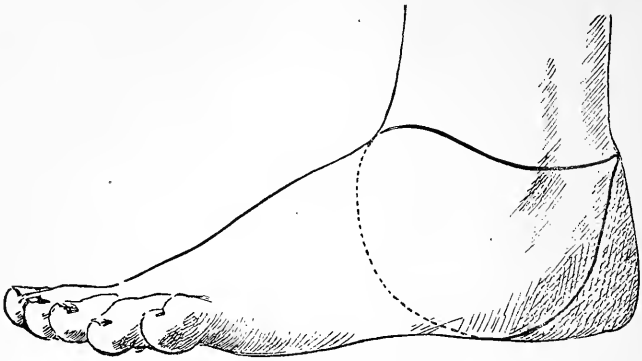

FIG. 140.—Exarticulation of the Foot (Syme, modified).

On the medial side the most difficult point is the sustentaculum tali, which extends high up.

When the tegumentary covering is insufficient the head of the astragalus is sawed off.

212*b*. *Osteoplastic Subastragaloid Amputation.*—Performed by Hancock by the attachment of the severed tuber calcanei to the sawed lower surface of the astragalus. The indication for the operation is of exceptional occurrence.

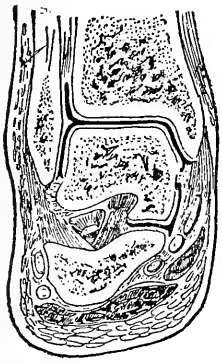

FIG. 141.—Frontal Section through the Ankle Joint, after Henle.

213. *Exarticulation of the Foot* (Syme; Figs. 140 and 141).—The total removal of the foot at the ankle joint has been performed by Syme, a flap having been formed from the integument of the heel. This method has the drawback that in place of the enucleated tuber calcanei a cavity is left which is not filled up.

Worthy of recommendation is the oval incision with the formation of a flap from the medial side, beginning transversely over the tip of the external malleolus (Fig.

140). After dividing the skin, the strong lateral ligaments (lig. fibulo-calcaneum and astragalo-fibularia) and the peroneal tendons are severed and the extensor tendons at the margin of

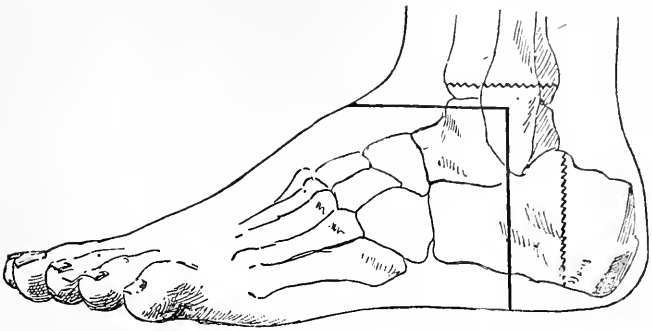

FIG. 142.—Osteoplastic Exarticulation of the Foot (Pirogoff).

the retracted skin; the ankle joint capsule is opened and enucleated close to the bone along the calcaneus, downward from the flaps. The malleoli are circumscribed with the knife and sawed off.

214. *Osteoplastic Amputation of the Foot* (Pirogoff; Figs. 142 and 143).—The leg bones are sawed off immediately above

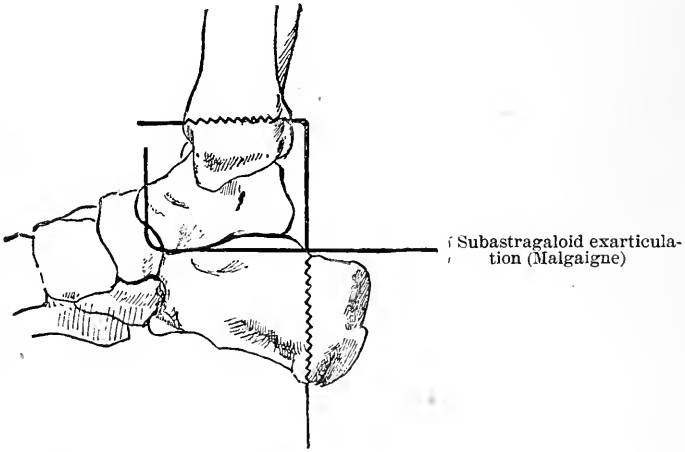

FIG. 143.—Osteoplastic Exarticulation of the Foot (Pirogoff).

the cartilaginous surface and to the sawed surface is attached that of the tuber calcanei to lengthen the leg. The preservation

of the tuber calcanei has the great advantage that the skin of the heel remains well nourished and the so-called heel cap remains filled. It is far preferable to Syme's exarticulation.

The simplest and most reliable method is the following: Tenotomy of the Achilles tendon. Incision beginning at the level of one malleolus, extending in the axis of the leg—the foot being kept at a right angle—over the heel ("stirrup" incision), and ending at the level of the opposite malleolus. The incision throughout is carried vigorously down to the bone and severs the tendons within and without completely.

Second incision extending directly forward at a true right angle from the ends of the first incision, so that the anterior end lies a good thumb's breadth in front of the ankle joint. This incision severs only the skin and fascia, at the margin of which the extensor tendons are divided.

The astragalo-crural joint is opened from in front, the lateral ligaments are divided under the malleoli until the astragalus is laid bare to its posterior end. Then the tuber calcanei is sawed off vertically behind the astragalus, in the plane of the stirrup incision, and turned up with the skin of the heel. The malleoli and articular portions of the leg bones are circumscribed with the knife and sawed off transversely. The suture exactly coapts the sawed surfaces. The gait subsequently is excellent.

In order to avoid the turning of the calcaneus, which in our opinion, however, is quite serviceable, many surgeons have sawed the calcaneus obliquely (Schede, Volkmann) or horizontally (Dupasquier, Lefort) or at a curve and angle (Bruns, Böckel).

For the horizontal division the oval incision is to be recommended (similar to Fig. 139), beginning horizontally under the tip of the external malleolus. By this horizontal incision room is gained for sawing.

All these modifications have the drawback, as compared with the above-described method, that a portion of the cicatrix is placed too near the inferior surface of the foot.

215. *Amputation of the Leg* (Figs. 144, 145, and 146).—We indicate the suitable incisions merely by illustrations; for the performance we refer to the description of amputations in general. The oblique incision is the method most frequently employed; at the upper and lower end it is best to form the flap in front so as to cover the epiphyses, which are sawed in a curve.

About the diaphysis, however, the oblique incision is made so that the flap lies antero-externally, lest the anterior edge of the tibia (which should always be rounded off) be pressed too firmly against it. It is well to separate the periosteum of the inner surface of the tibia with the tegumentary flap so as to protect the bone.

The interosseous ligament adheres firmly to the bone and is dissected up with the periosteum by means of the knife. The division of the muscles between the bones must be made smoothly in a transverse plane so that the vessels are divided with one cut.

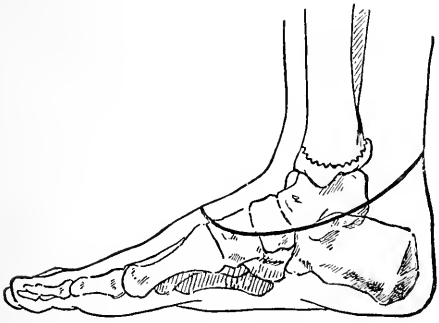

Fig. 144.—Intra-malleolar Amputation.

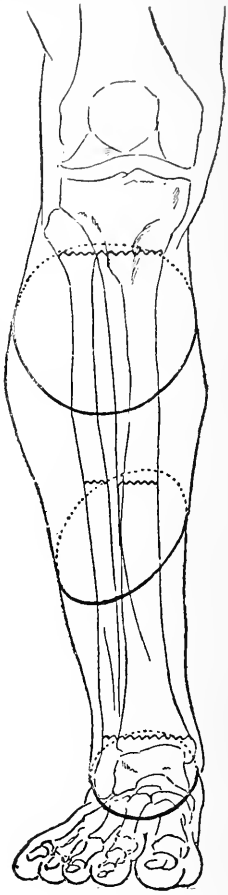

Fig. 145.—High, Medial, and Intra-malleolar Amputation of the Leg.

Throughout the length of the leg the vessels to be ligated are: tibialis antica artery (and vein) on the interosseous liga-

ment, tibialis postica artery on the deeper calf muscles, in the lower two-thirds the peroneal artery on the dorsal surface of the fibula or of the flexor hallucis longus muscle.

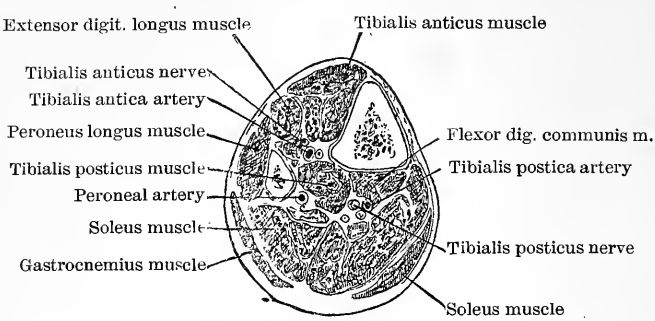

Fig. 146.—Transverse Section of the Leg, after a Photograph.

216. *Exarticulation of the Knee* (Figs. 147 and 150).—Furnishes an excellent stump when the course is aseptic. Whether the preservation of the articular cavity (Socin) is a permanent advantage is still uncertain.

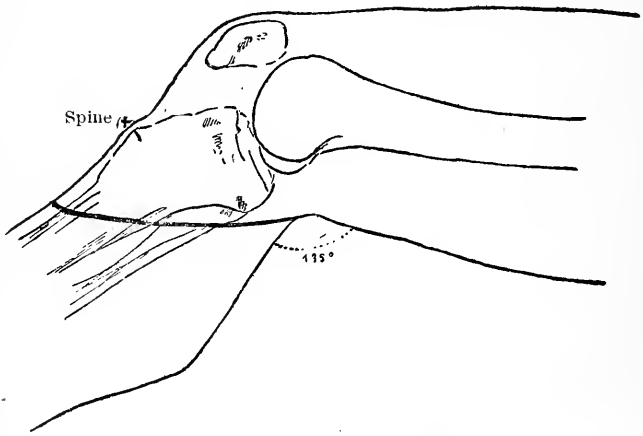

Fig. 147.—Exarticulation of the Knee.

Oblique incision with anterior flap, beginning posteriorly in the line of the joint and ending in front four fingers' breadth below the spine of the tibia. If the leg is kept half flexed (at an angle of 135° with the thigh), the direction of the incision lies in the prolongation of the axis of the thigh (Fig. 147).

The skin with the fascia is dissected back, the capsule with the ligamentum patellæ is divided in front, the meniscuses and lateral ligaments in front and laterally, then along the intercondyloid eminence of the tibia the crucial ligaments are separated, the posterior wall of the capsule is severed along the tibia, and the operation is completed by a transverse incision through the posterior soft parts.

Where the removal of the patella appears necessary on account of prothesis, the flap is turned over, the patella circumscribed with the knife, and enucleated subperiosteally.

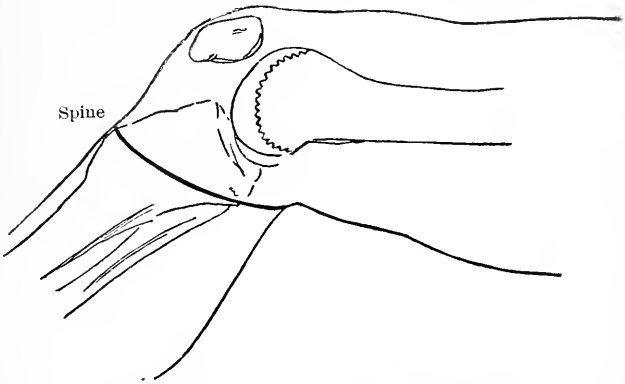

Fig. 148.—Intracondylic Amputation (Carden).

The main vessels are the popliteal artery and vein. Among the larger branches the articularis genu artery and occasionally muscular branches to the gastrocnemius require ligation.

217. *Amputation of the Femur* (Figs. 148–152).—Formerly and even now one of the more frequent amputations. An oblique incision is to be recommended for any level, and so is the circular method, with the exception of the lower end, owing to the bad position of the cicatrix.

218. *Intracondylic Amputation* (Fig. 148; Carden and Buchanan).—In amputation at the lower end of the femur in children Buchanan simply divides the condyles in the epiphyseal line.

Carden saws off the condyles in a curve at their greatest

circumference and by this means obtains an excellent stump which easily bears the weight of the body. Oblique incision beginning at the level of the condyles and extending in front to the spine of the tibia.

219. *Supracondylic Amputation* (Fig. 151) is performed by an oblique incision with flap (Langenbeck) on the anterior inner side because the adductors draw the thigh forward and inward; were the incision made directly anterior, the bone would be crowded too far toward the inner angle of the wound.

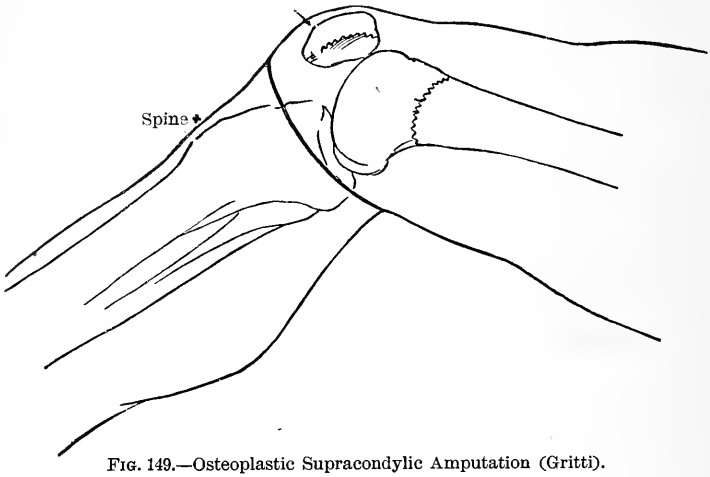

Fig. 149.—Osteoplastic Supracondylic Amputation (Gritti).

A modification of this frequent amputation is Gritti's supracondylic amputation (Fig. 149). Oblique incision, the upper end lying posteriorly directly over the eminence of the condyles, the lower end in front, two fingers' breadth under the patella. The ligamentum patellæ is divided at the upper end. After sawing through the femur and the cartilaginous surface of the patella, the latter is attached to the femur or nailed to it.

220. The amputation through the middle (Fig. 151), owing to the massive muscles, is best performed in such a way as to form two short vertical flaps (Lisfranc and Esmarch), and after their retraction to divide the muscles transversely by a smooth cut. Very smooth wounds can also be obtained by inserting

the knife on both sides of the bone after the division of the skin. When the muscles are well developed, the periosteum should be pushed up several centimetres in order to obtain sufficient integument and to be able to cover the sawed surface with periosteum.

221. The high amputation (Fig. 151) is performed by an oval incision in a manner resembling exarticulation of the femur. The longitudinal portion of the incision is on the outer side, extends down to the bone, and permits its enucleation subperiosteally to the point of division.

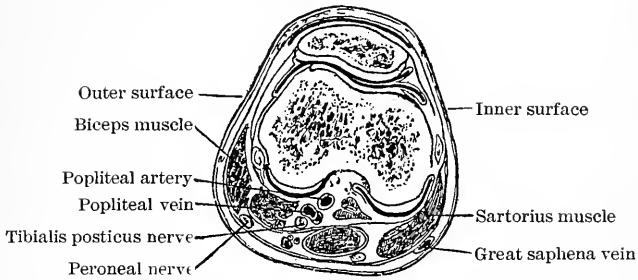

FIG. 150.—Transverse Section through the Lower End of the Femur and Knee Joint (after Braune).

During amputation of the femur in the lower third (Fig. 152) the vessels to be ligated are the femoral artery and vein, the articularis genu suprema artery antero-internally, and possibly the superior arteries of the knee joint. In the upper two-thirds, besides the femoral artery and vein, the profunda femoris artery and in the upper third large branches of the external circumflex artery require ligation.

222. *Exarticulation of the Hip* (Figs. 153 and 154).—Though formerly a capital operation, the removal of the thigh at the hip joint can now, thanks to the improved technique, be performed without hesitation even on relatively feeble patients.

Rose (Lüning) extirpates the thigh like a tumor, either ligating the vessels immediately after their division or doubly ligating them before they are severed. In the case of tumors reaching high up into the region of the hip joint this procedure

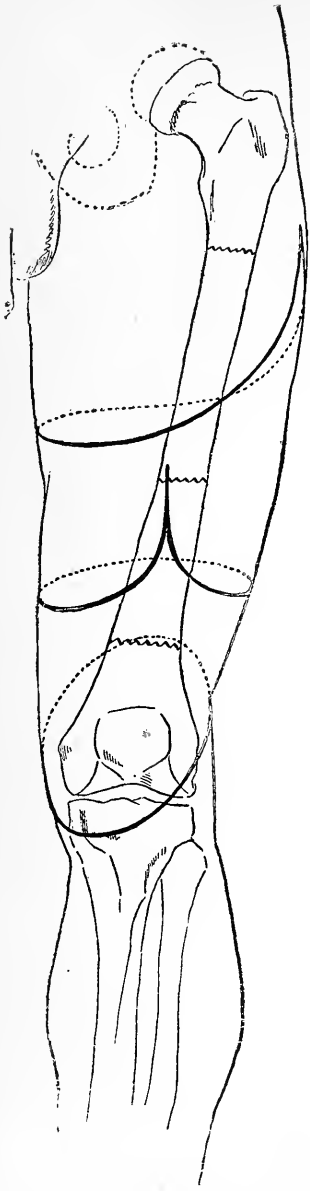

Fig. 151.—High, Median, and Supracondylic Amputation of the Femur.

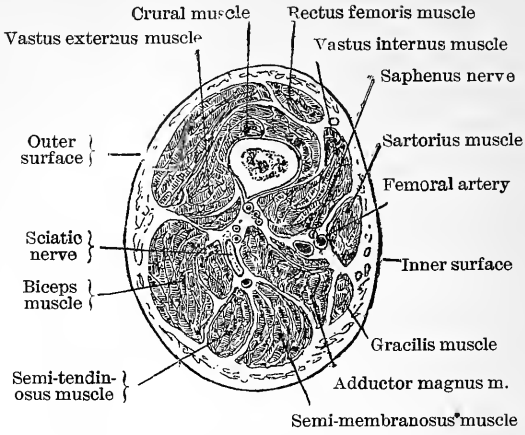

Fig. 152.—Transverse Section through the Thigh (after a Photograph).

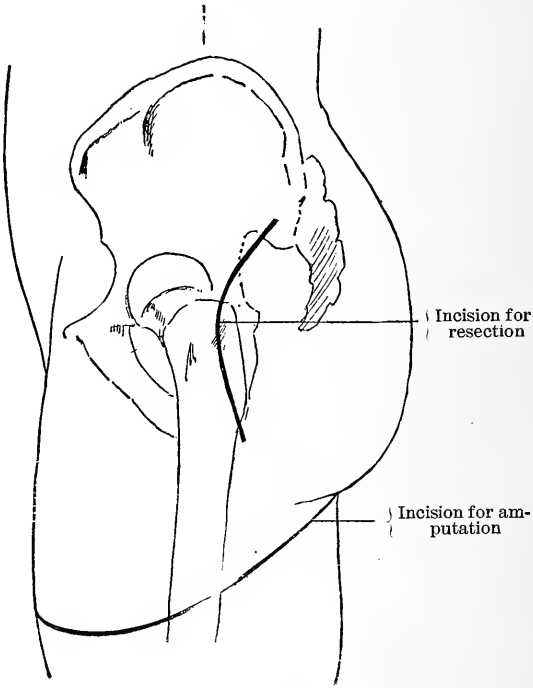

Fig. 153.—Exarticulation of the Hip.

is the most suitable. For these reasons the technique requires no special description, as it varies in each case.

Wherever the soft parts about the hip joint can be preserved this should unquestionably be done. For in the subsequent use of an artifical limb the function of the muscles in the stump after exarticulation of the hip is of the greatest value. Especially after operating subperiosteally a stump is obtained which gives vigorous mobility in all directions, similar to the high amputation of the femur.

The elastic bandage is applied in the inguinal fold for the prophylactic arrest of hemorrhage, a figure-of-eight turn being invariably made around the pelvis to prevent downward displacement. At the height calculated in the usual manner (see General remarks on amputations) the circular incision is carried through the skin and at its margin the corresponding incision through the muscles to the bone, which is sawed through after the separation of the periosteum. Careful ligation of the vessels follows, after which the elastic bandage is removed.

Fig. 154.—Frontal Section of the Hip and Knee Joints, after Henle.

More suitable than the simple circular method is an oval incision, the prolongation being on the outside (Fig. 151) of the bone, or eventually a short anterior and posterior flap.

The exarticulation of the upper end of the femur is performed in various ways.

After the amputation Beck divides on the outer surface of the femur the soft parts and enucleates the bone, separating with the knife the attachments of the periosteum at the linea aspera, of the tendons (of the three gluteal muscles, the pyriformis, external and internal obturator with gemelli, quadratus femoris at and under the great trochanter, ilio-psoas at the lesser trochanter), and of the capsule about the anterior and posterior inter-trochanteric line. The ligamentum teres is torn by rotating the bone several times.

We (Kocher, Roux) precede the amputation by a resection of the hip, with a shortened posterior incision about the great trochanter (which see), ligating all the bleeding vessels, and then only apply the elastic ligature and make the amputation. Our method has the advantage that the inevitable hemorrhage from the smaller vessels (obturator, circumflex, and sciatic arteries) occurs at the beginning instead of the end of the operation.

Otherwise the same vessels are to be ligated as in the high amputation of the femur.

Y. Upper Extremity.

223. *Amputation and Exarticulation of the Fingers* (Figs. 155, 156, and 157).—For the fingers the main rule is to preserve even the smallest stump, provided it can remain connected with the tendons and be covered with healthy integument. All methods, therefore, are good. Where the choice is open, flaps from the volar side are to be preferred, so as to avoid cicatrices in the palm. The corresponding oblique incision is the most suitable, in fact necessary for the ungual phalanx. The position of the joints is readily located by bending the fingers, since the line of the joint is always peripheral from the dorsal emi-

nences (Fig. 155). Here the knife is applied and carried obliquely downward toward the palm. The phalanx being strongly flexed, the attachment of the extensors to the base is divided, then the dorsal capsule, the two lateral ligaments, and the flexor tendons.

During amputations the volar flap must be turned back, so as to circumscribe the bone with the knife.

For the exarticulation of the fingers in the phalango-

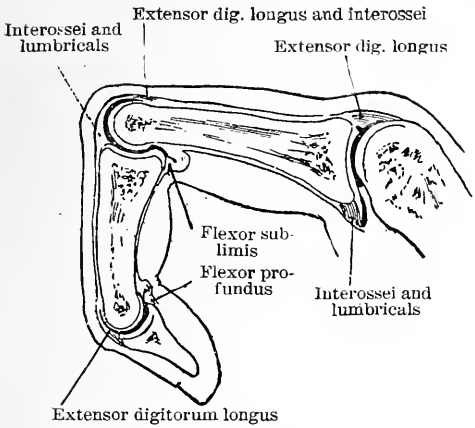

FIG. 155.—Position of the Joints of the Fingers in Flexion, and Attachments of the Tendons.

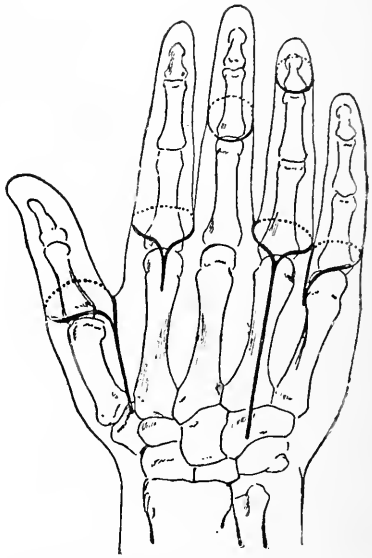

FIG. 156.—Exarticulation of Fingers: Fifth, Second, Fourth with Metacarpal. First with Metacarpal (Dorsal Surface).

metacarpal and in the metacarpo-carpal joint the oval incision is used, whose longitudinal portion extends backward over the head of the metacarpus or over the base of this bone. The tendons are divided at the margin of the retracted skin, then the periosteum is opened and detached, at the articular ends simultaneously with the capsular attachment.

In the case of the thumb, index, and little finger, the dorsal portion of the incision is placed toward the median line of the hand instead of toward the middle of the bone or joint.

In removing the metacarpals of the thumb and little finger it is a matter of special importance to keep the short thenar and hypothenar muscles quite intact, as in this way very useful movable stumps are obtained, especially with subperiosteal enucleation of the bone.

For the exarticulation of the whole finger, with or without the metacarpal, the point for the transverse incision is exactly defined by the transverse fold between the palm and finger; no incisions must be made farther back in the palm.

224. *Exarticulation of the Hand* (Fig. 157).—For this as well as for the amputation of the forearm the most variable

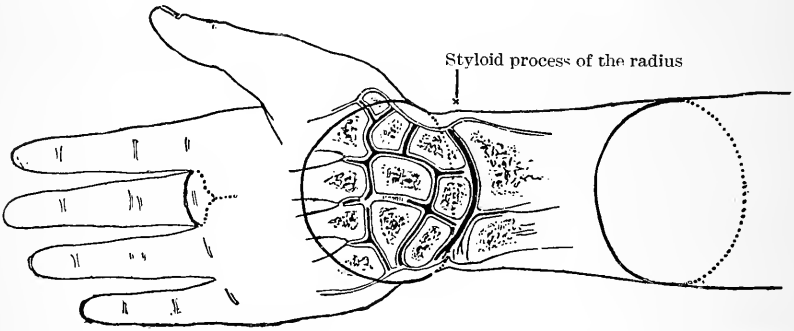

FIG. 157.—Exarticulation of the Third Finger, Exarticulation of the Hand, Amputation of the Forearm.

methods are admissible by which a longer stump can be obtained. Contrary to Major's rule with reference to the foot, no amputation should be made in the transverse line so long as a movable finger or portion of the hand can be preserved.

Oblique incision, the upper end in the line of the wrist joint, the lower end in the palm. Under strong volar flexion the extensor tendons and the dorsal capsule are divided; also the lateral ligaments and tendons under the styloid processes projecting farther downward (external ulnar, extensors and abductor of the thumb), and the upper row of carpal bones which is convex above is enucleated. In the line of the joint the bundle of flexor tendons is divided and anteriorly the volar

flap freed in its entire thickness. The volar flap has the advantages of excellent nutrition, delicate tactile sensation, and occasionally the preservation of movable muscular stumps.

The vessels requiring ligation are the ulnar artery or its two branches passing to the volar arch in the palm and the branch of the radial artery to the superficial arch; on the dorsal side the trunk of the radial artery passing to the deep arch.

225. *Amputation of the Forearm* (Figs. 157 and 158).—This presents no peculiarities deviating from the general rules. An oblique incision with volar flap is to be recommended for the

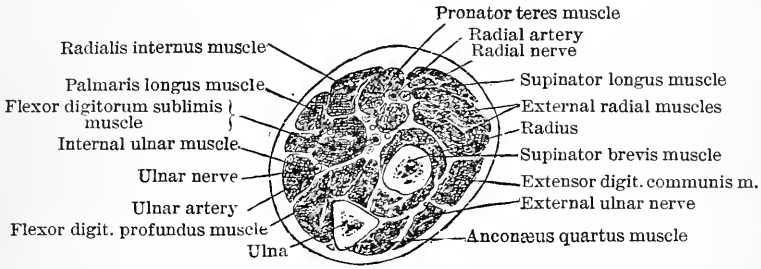

Fig. 158.—Transverse Section of the Forearm in the Upper Third, after a Photograph.

same reasons as at the wrist joint. It prevents cicatrices on the volar side.

Ligation of the radial and ulnar arteries and the interosseal lying under and medially from the latter.

226. *Exarticulation of the Elbow* (Figs. 159 and 160).—It is an error repeated incessantly by instructors in operating, that the joint-line of the elbow is to be determined from the tip of the olecranon. It should be determined from the condyle of the radius, which can always be felt on the dorso-radial side.

Oblique incision from the line thus determined in the bend of the elbow, extending a hand's breadth under the tip of the olecranon on the dorsal side. When the forearm is flexed at an angle of 135° the direction of the incision is parallel to the prolonged axis of the arm. The dorsal flap with the periosteum, and the attachment of the triceps and anconæus

quartus are freed beyond the tip of the olecranon and the dorsal surface of the humerus. In front the soft parts with the joint

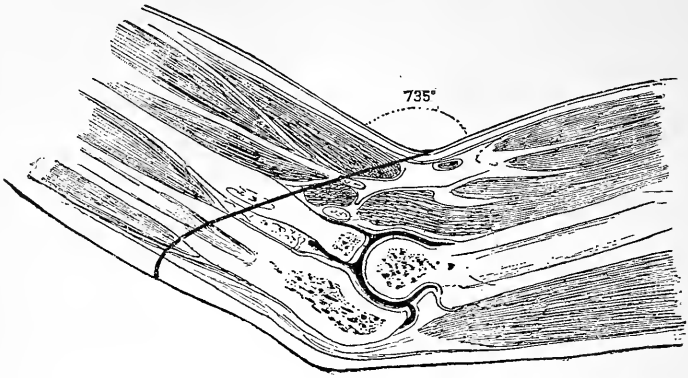

FIG. 159.—Exarticulation of the Elbow; Longitudinal Incision after Braune.

capsule are divided transversely, the flap being lifted and the knife carried into the humero-radial articulation. With the

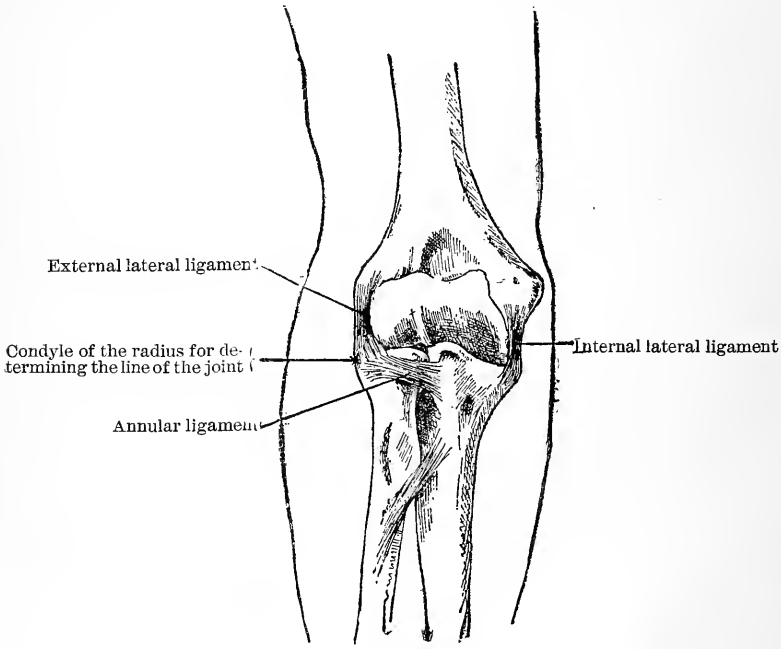

FIG. 160.

division of the tense internal ligament the operation is finished. Ligation of the brachial artery in the bend of the elbow.

227. *Amputation of the Arm* (Fig. 161).—In order to obtain a broad covering of the arm stump we must bear in mind that the arm is much flattened from without inward when the volar surface is directed forward. Flaps should be formed from the broad side. Accordingly in an oblique incision the upper

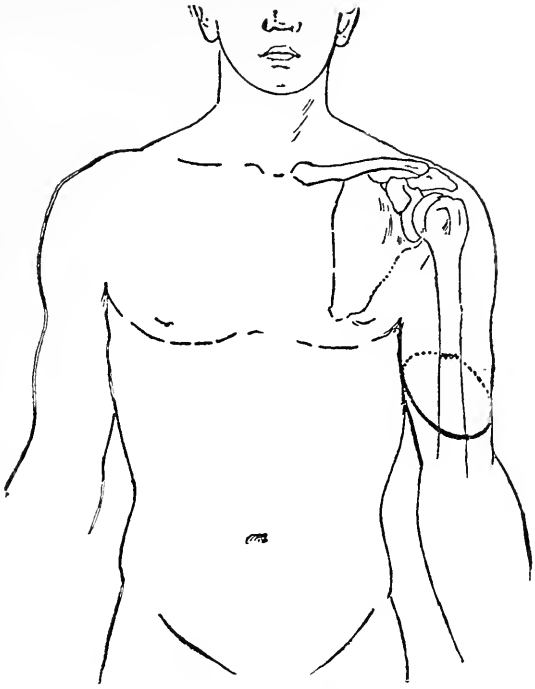

Fig. 161.—Amputation of the Humerus.

end of it falls in the internal bicipital sulcus. The biceps muscle retracts strongly.

The upper limit for securing a useful stump by amputation is determined by the surgical neck to which the joint capsule is continued on the medial side; on the other side, by the attachments of the deltoid, pectoralis major, and latissimus, which must maintain the equilibrium as the chief abductors and adductors. Regarding the rules for the high amputation compare the exarticulation of the humerus. Ligation is required for the brachial and the deep brachial arteries, together with

smaller branches (collateral ulnar arteries). When the bone is sawed through at the turning-point of the radial nerve, its resection is particularly necessary.

228. *Exarticulation of the Humerus* (Fig. 162).—In removing the arm at the shoulder joint it is as necessary as in exarticulation of the hip that wherever possible a musculo-periosteal

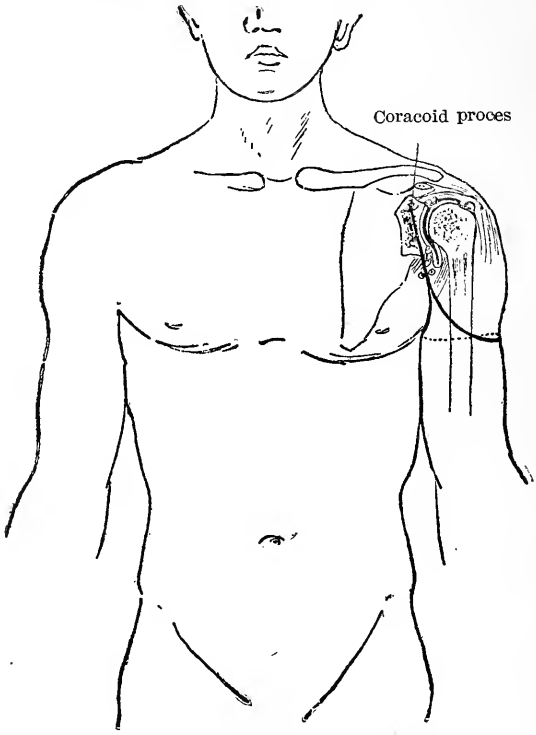

FIG. 162.—Exarticulation of the Humerus.

stump be preserved. This will be important in the use of an artificial limb.

The incision is made in accordance with this requirement. It is admissible, in a manner analogous to that of the hip, to make a high amputation at the level of the axillary folds, by means of a circular incision; and, after sawing the bone, to add a longitudinal incision on the anterior surface as in resection of the humerus, and to enucleate the upper end of the humerus.

However, this is not absolutely necessary, as the hemorrhage can be controlled as certainly through a simple oval incision.

The longitudinal incision begins under the clavicle on the outer side of the coracoid process and passes downward at the anterior margin of the deltoid to the level of the axillary fold, then turns laterally around the belly of the deltoid, extends transversely across the dorsal surface and upward under the anterior axillary fold, and terminates in the first part of the incision.

Immediately after tracing the first longitudinal incision the cephalic vein and branches of the thoracico-acromial artery are ligated. In front we penetrate into the depth to the bone at the margin of the deltoid (the uppermost anterior fibres are severed), between it and the pectoralis major, divide the capsule in the bicipital sulcus and upward to the socket, and separate it with the tendinous attachments of the subscapularis, also the periosteum with the attachment of the pectoralis major on the inner side, the attachments of the supraspinatus, infraspinatus, and teres minor on the outer side of the bone, so that the head of the humerus can be readily forced out forward and upward. In cutting upon the surgical neck, the ligation of the circumflex arteries, or at least of the anterior artery, may come in question. When the cutaneous incision is then completed, it will be easy to ligate the main vessels before dividing the deep soft parts transversely, and to separate the latissimus dorsi and teres minor muscles from the spine of the lesser tuberosity. During this step we must carefully avoid injury of the axillary nerve, which turns behind the bone over the teres major in order to supply the deltoid. For the latter is the chief muscle of the remaining stump.

229. *Exarticulation of the Arm with the Shoulder Girdle* (Fig. 163).—As a rule the operation is performed for tumors which have involved the shoulder joint with the scapula, frequently also the axillary glands, vessels, and muscles. The

preservation of any stump, therefore, is out of the question. Of course, cases occur in which only a portion of the scapula (acromion and articular portion) need be removed with the arm.

Prophylactic arrest of hemorrhage is out of the question. The first care, therefore, in making the incisions is the ligation

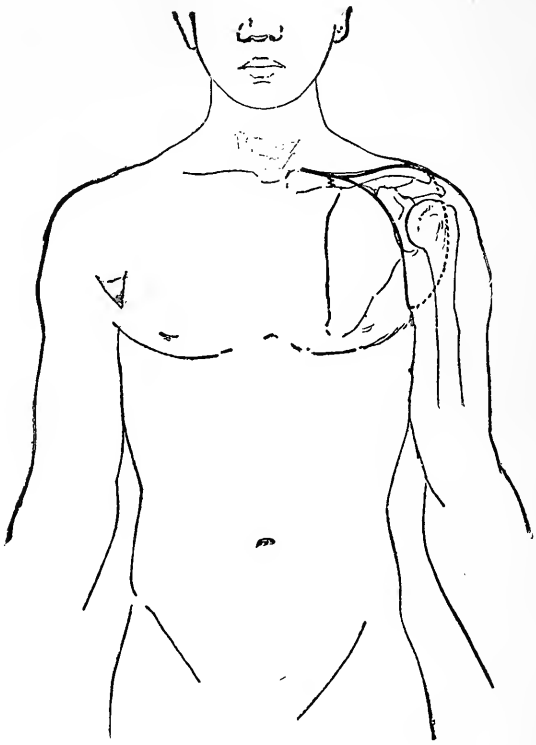

FIG. 163.—Exarticulation of the Shoulder Girdle.

of the large vessels. Otherwise the direction of the incision is to be largely modified according to the involvement of the skin.

The rule is an oval incision, the longer portion of which passes over the clavicle, beginning in the supraclavicular fossa. The periosteum of the clavicle is divided, the clavicle sawn through and bent apart with sharp hooks, and the subclavian muscle is carefully separated. The fascia is opened and the subclavian artery and vein and the brachial plexus are laid

bare. The nerves are divided singly, the vessels doubly ligated and cut.

If the hemorrhage is to be reduced to the minimum, other vessels must be ligated, as follows: Branches of the subclavian which emerge laterally over the scaleni, namely, the three branches of the thyro-cervical trunk which pass from the scalenus upward (ascending cervical artery), upward and outward (superficial cervical artery), and laterally behind the clavicle (transverse scapular artery); finally the thick transversa colli artery which passes backward over or through the brachial plexus so as to supply the scapular muscles (levator, supraspinatus) and then descends along the scapula (as the dorsalis scapulæ) between the rhomboid muscles and the serratus posticus superior. By this means we guard against serious hemorrhage.

Then the anterior incision is carried into the depth between the clavicular portion of the pectoralis major and the deltoid on the medial side of the large vessels, dividing first the pectoralis minor at the coracoid process, then the attachments of the pectoralis major and latissimus dorsi as close as possible to the humerus, during which step the skin is severed antero-posteriorly through the axilla. Then the arm together with the scapula and clavicle can be lifted off.

The posterior incision passes backward over the acromion and downward on the dorsal surface to the posterior axillary fold. Along the upper margin of the clavicle, acromion, and spine of the scapula the upper portion of the trapezius is divided; along the lower margin of the spine, the lower portion of this muscle.

The scapula is now attached only by its upper margin to the omo-hyoid and levator scapulæ, by its posterior margin to the serratus anticus major and rhomboids.

Berger has done very meritorious work in developing the method of the exarticulation of the shoulder girdle.